

CALCIFICATION OF BASAL GANGLIA IN CHRONIC HYPOPARATHYROIDISM

Hamza Ali Khan¹, Anurag Dhingra², Paul Peter³,
Giridhar Tarigopula⁴, Praveen Partha⁵

ABSTRACT

Hypoparathyroidism and pseudohypoparathyroidism are the common causes of pathological calcification in the brain. Though in 0.3- 1.5 % cases it can be physiological, we describe a case of pathological basal ganglia calcification due to hypoparathyroidism. A 39 years old diabetic lady who presented with neuro-psychiatric problems and seizures and finally diagnosed as a primary hypoparathyroidism with symptoms related to metastatic calcification in the brain. This case emphasizes the importance of thinking about the whole spectrum of the disease even though the biochemical markers are stable on treatment.

Key Words: Calcification, Basal Ganglia, Chronic hypoparathyroidism, Pseudohypoparathyroidism.

This case report may be cited as: Khan AK, Dhingra A, Peter P, Tarigopula G, Partha P. Calcification of basal ganglia in chronic hypoparathyroidism. J Postgrad Med Inst 2013; 27(4):450-3.

INTRODUCTION

Calcification of basal ganglia was described in 1855 by Virchow¹ and Bamberger² independently, but Eaton et al recognized its association with chronic hypoparathyroidism in 1939³.

Hypoparathyroidism is an endocrine disorder due to various causes and can be primary idiopathic which includes congenital or autoimmune causes and acquired (usually iatrogenic). There is decreased level of PTH hormone which in turn is usually associated with hypocalcaemia. The clinical presentation of hypoparathyroidism can vary with the serum calcium levels and chronicity of hypocalcaemia. Often acute hypocalcaemia presents with paresthesias, arrhythmias, muscular spasms (e.g. carpopedal) or tetany where as chronic hypocalcaemia may be completely asymptomatic. Hypoparathyroidism is well known entity which can cause intracranial calcifications but

extensive intracranial calcification is rare⁴.

The mechanism of intracranial calcification is not completely understood⁵. It may be related to the duration of hypocalcaemia and hyperphosphataemia than parathyroid hormone itself. Basal ganglia calcification presents with diverse presentations, the most common including seizures, mental deterioration, and disorders of cerebellar or extra-pyramidal function. Only 20 - 30% of patients with basal ganglia calcification present with movement disorders, chorea, or Parkinsonism, while some patients are asymptomatic.

CASE REPORT

A 39 year old female who was Type 1 Diabetic for last 23 years was repeatedly hospitalised with collapse episodes thought to be hypoglycaemic though never proved. She also had primary hypoparathyroidism since 2002 and was on calcium and vitamin D supplements. She had cataract removal from right eye and also had early cataract in left eye. Her fundal examination did not show any diabetic retinopathy. She also started to have tonic clonic seizures which initially were thought to be due to hypoglycaemic events but the capillary glucose was never documented in these episodes. It was becoming apparent that she was struggling to manage her diabetes and it was thought that she was having some cognitive impairment secondary to severe hypoglycaemias. Her family had also confirmed her declining memory over past couple of years. She would take long pauses trying to recall things.

¹⁻⁵Department of Diabetes & Endocrinology, Darlington Memorial Hospital, Darlington - United Kingdom.

Address for Correspondence:

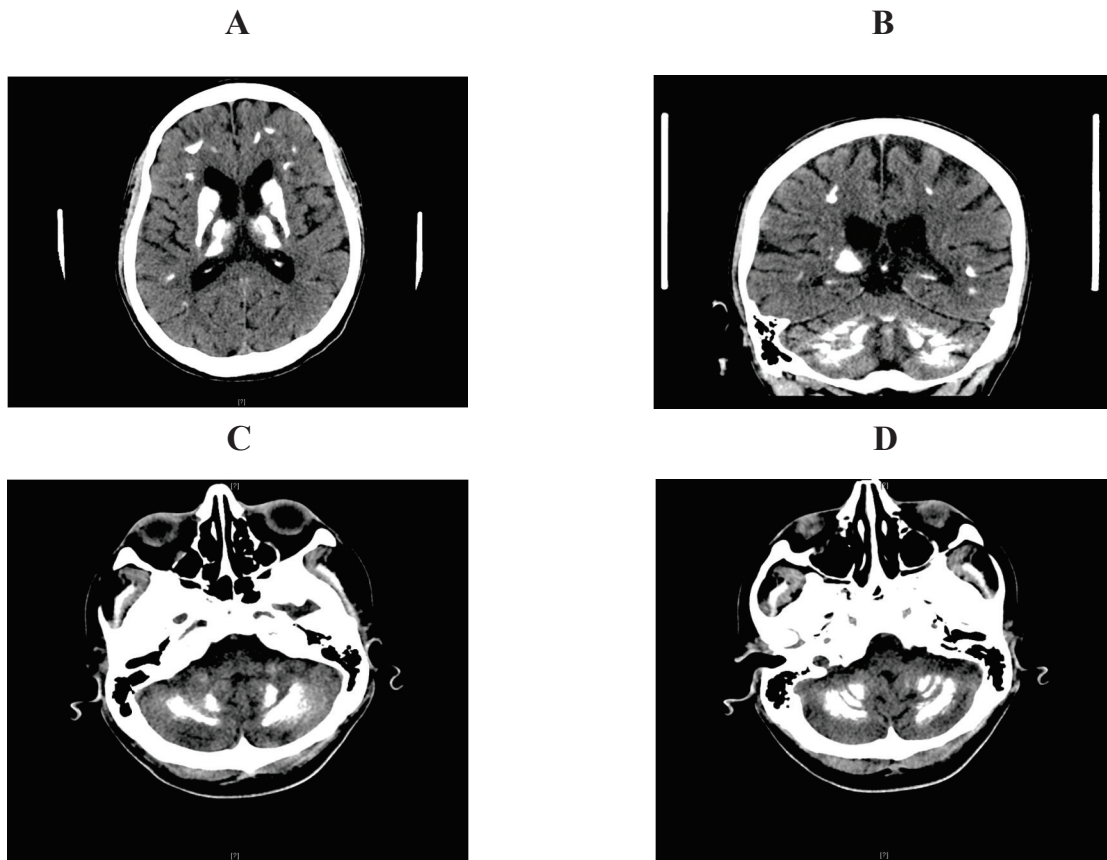
Dr. Hamza Ali Khan

Specialist Registrar, Department of Diabetes & Endocrinology Darlington Memorial Hospital Darlington - United Kingdom.

E-mail: hamzaali_k@yahoo.com

Date Received: 18 April 2013

Date Accepted: 20 August 2013

Figure 1: CT Brain showing calcification in basal ganglia

On examination she had slow speech, serpentine gaze and shuffling gait. Rest of the systemic examination was normal. Chvostek's sign and Trousseau's signs were negative. Looking through her records her calcium was reasonable with adjusted calcium of 2.2 -2.5 mmol/L on treatment.

She was sent for neuropsychological assessment to ascertain the cognitive impairment and whether she would be capable of looking after her diabetes by herself. There she was found to have marked cognitive impairment in everyday functioning, particularly planning & organisation, abstract reasoning, attending to verbal information and processing new information, recalling and decision making. She had CT brain showing calcification in basal ganglia involving caudate nucleus lentiform nucleus and thalamus, in the centrum semi ovale bilaterally and also demonstrated subcortical dense curvilinear calcification bilaterally (Figure 1). She was seen by a neurologist and started on anticonvulsant treatment. Her seizures improved with no improvement in her cognition and gait abnormalities.

DISCUSSION

Parathyroid glands contain the parathyroid chief cells that sense the level of calcium in the blood through the calcium-sensing receptor and secrete parathyroid hormone to maintain a calcium level within normal limits. PTH increases calcium absorption in the bowel, while it prevents calcium excretion and increases phosphate release in kidney and increases calcium through bone resorption in bone.

Hypoparathyroidism causes calcification most often in basal ganglia⁸. Calcification can also occur in other parts of the brain including subcortical white matter, corona radiata, thalamus and cerebellum. Basal ganglia calcification is associated with any type of hypoparathyroidism and, rarely, with other metabolic diseases; as a familial trait; and sporadically, without abnormal calcium metabolism. Sporadic calcification is the most common form being present in up to 1.5% of all brain scans².

The goal of therapy in hypoparathyroidism is to control symptoms and minimise complications. The

immediate treatment of the patient depends on the nature and severity of the symptoms and serum calcium levels⁹⁻¹¹. Severe symptoms (e.g., seizures, laryngospasm, bronchospasm, cardiac failure, and altered mental status) warrant intravenous calcium therapy, even if the serum calcium level is only mildly reduced (1.75 to 2.00 mmol per liter). Oral therapy is appropriate in patients with mildly reduced serum total calcium levels (1.87 to 2.00 mmol per liter) who have symptoms, even if they are nonspecific ones (e.g., fatigue, anxiety, and reduced well-being) because these symptoms may improve with calcium and Vitamin D⁶.

Only a few randomised trials have assessed the use of human PTH in patients with hypoparathyroidism^{12,13}. In a 3-year trial comparing PTH (1-34) with calcitriol, both given every 12 hours with supplemental calcium, both treatments maintained the serum calcium level within or slightly below the normal range (1.9 to 2.2 mmol per liter) there were no differences in bone mineral density between the groups¹². Creatinine clearances did not differ significantly between the groups and they were stable in both groups during the study. PTH (1-34), however, is not approved by the Food and Drug Administration for this indication.

Seizures occur in up to 70% of patients with symptomatic hypoparathyroidism¹⁴⁻¹⁶ which can be improved by correction of serum calcium levels in most of the cases¹⁶. Parkinsonism, dystonia, hemiballismus, choreoathetosis, and oculogyric crises occur in 5-10% of patients with idiopathic hypoparathyroidism¹⁷, but are less common in patients with surgical hypoparathyroidism or other causes of hypocalcemia¹⁸. Parkinsonism seems to be resistant to Levodopa but in some cases seem to have improved or recovered after calcium and vitamin D replacement¹⁹⁻²¹.

In our case, initially hypoglycaemia was thought to be the cause of patient's seizures and neuropsychiatric symptoms as serum calcium was stable (2.2-2.5mmol/L). However, her visit to the neurologist and subsequent CT brain findings and improvement in seizures after anticonvulsant treatment showed that her symptoms were due to hypoparathyroidism related brain calcification. This case emphasizes the importance of thinking about the whole spectrum of the disease even though the biochemical markers are stable on treatment.

REFERENCES

1. Virchow R. Kalk metastasen. *Virchows Arch Pathol Anat* 1855;8:103-13

2. Bamberger, Von Rokitsansky K. *Lehrbuch der Pathologischen Anatomie*. Vienna, Austria: Wilhelm Braumuller; 1856.
3. Eaton LM, Camp JD, Love JG. Symmetric cerebral calcification, particularly of the basal ganglia, demonstrable roentgenographically: calcification of the finer cerebral blood vessels. *Arch Neurol Psychiatry* 1939;41:921-42.
4. Basak RC. A case report of basal ganglia calcification - a rare finding of hypoparathyroidism. *Oman Med J* 2009;24:220-2.
5. Fujita T. Mechanism of intracerebral calcification in hypoparathyroidism. *Clin Calcium* 2004;57:1455-7.
6. Shoback D. Hypoparathyroidism. *N Engl J Med* 2008;359:391-403.
7. Koller WC, Cochran JW, Klawans HL. Calcification of the basal ganglia: computerized tomography and clinical correlation. *Neurology* 1979;29:328-33.
8. Harrington MG, Macpherson P, McIntosh WB, Allam BF, Bone I. The significance of the incidental finding of basal ganglia calcification on computed tomography. *J Neurol Neurosurg Psychiatry* 1981;44:1168-70.
9. Cooper MS, Gottoes NJ. Diagnosis and management of hypocalcemia. *BMJ* 2008;336:1298-302.
10. Lebowitz MR, Moses AM. Hypocalcemia. *Semin Nephrol* 1992;12:146-58.
11. Rude RK. Hypocalcemia and hypoparathyroidism. *Curr Ther Endocrinol Metab* 1997;6:546-51.
12. Winer KK, Ko CW, Reynolds JC, Dowdy K, Keil M, Peterson D, et al. Long-term treatment of hypoparathyroidism: a randomized controlled study comparing parathyroid hormone (1-34) versus calcitriol and calcium. *J Clin Endocrinol Metab* 2003;88:4214-20.
13. Winer KK, Yanovski JA, Cutler GB. Synthetic human parathyroid hormone 1-34 vs calcitriol and calcium in the treatment of hypoparathyroidism. *JAMA* 1996;276:631-6.
14. Messing RO, Simon RP. Seizures as a manifestation of systemic disease. *Neurol Clin* 1986;4:563-84.

15. Fonseca OA, Calverley JR. Neurological manifestations of hypoparathyroidism. *Arch Intern Med* 1967;120:202-6.
16. Hossain M. Neurological and psychiatric manifestations in idiopathic hypoparathyroidism: response to treatment. *J Neurol Neurosurg Psychiatry* 1970;33:153-6.
17. Soffer D, Licht A, Yaar I, Abramsky O. Paroxysmal choreoathetosis as a presenting symptom in idiopathic hypoparathyroidism. *J Neurol Neurosurg Psychiatry* 1977;40:692-4.
18. Rubenstein A, Brust JC. Parkinsonian syndrome as complication of post-thyroidectomy hypoparathyroidism. *N Y State J Med* 1974;74:2029-30.
19. Frame B. Parkinsonism in postoperative hypoparathyroidism. *Arch Intern Med* 1965;116:424-7.
20. Pearson DWM, Durward WF, Fogelman I, Boyle IT, Beastall G. Pseudohypoparathyroidism presenting as severe parkinsonism. *Postgrad Med J* 1981;57:445-7.
21. Felitti VJ, McAfee LL. Recovery from symptoms in pseudohypoparathyroidism. *Johns Hopkins Med J* 1968;123:271-5.