

# COMPARISON BETWEEN ON LAY AND SUBLAY METHODS OF MESH REPAIR OF INCISIONAL HERNIA

Nadia Saeed<sup>1</sup>, Syed Abdullah Iqbal<sup>2</sup>, Bashir Ahmad Shaikh<sup>3</sup>, Fareeduddin Baqai<sup>4</sup>

<sup>1,2,4</sup> Department of surgery, Fatima Hospital, Baqai Medical University, Karachi - Pakistan.

<sup>3</sup> Surgical unit 1, Dow University of Health Sciences, Karachi - Pakistan.

**Address for correspondence:**

**Dr. Nadia Saeed**

Assistant Professor, Surgical unit III, Fatima Hospital, Baqai Medical University, Karachi - Pakistan.

E-mail: nadia\_saeed94@yahoo.com

Date Received:

December 17, 2013

Date Revised:

November 25, 2014

Date Accepted:

November 29, 2014

## ABSTRACT

**Objective:** To evaluate the repair of incisional hernia by two different methods onlay (Conventional method) and sublay (retromuscular preperitoneal) methods at two different tertiary care centres of Karachi - Pakistan.

**Methodology:** Patients diagnosed clinically and confirmed ultrasonographically and subsequently operated upon with either methods were included in this study. The primary endpoint was hernia recurrence. Secondary endpoints were operative time, length of hospital stay and postoperative complications of the two methods.

**Results:** A total of 80 patients were allocated in two groups, group A (n=40) underwent incisional hernia repair by sublay method and the remaining in Group B, (n=40) by onlay method. The frequency of wound infection was found significantly higher in the Sublay method of mesh placement (p=0.019). The frequency of seroma formation was significantly higher in the onlay method of mesh placement (p=0.076)

**Conclusions:** The sublay technique was proven to be very effective, with minimal complications and low recurrence rate.

**Key Words:** Incisional hernia, Onlay method, Sublay method.

This article may be cited as: Saeed N, Iqbal SA, Shaikh BA, Baqai F. Comparison between onlay and sublay methods of mesh repair of incisional hernia. *J Post Med Inst* 2014; 28(4): 400-3.

## INTRODUCTION

Incisional hernia is an important problem in surgical practice and occurs in up to 11% of patients who undergo laparotomy<sup>1</sup>. Apart from the risk of bowel strangulation, it also has an impact on patients quality of life<sup>2</sup>. The cause of incisional hernia is undoubtedly multifactorial. The technical factors such as slippage of knots, suture fracture, excessive tension and rapidly absorbable sutures can result in incisional repair<sup>3</sup>. The use of prosthetic material to reduce tension in hernia repair was described in 1950<sup>4</sup>.

Since its introduction, inclusion of a mesh in incisional hernia repair has unquestionably reduced the recurrence rate with the addition of prosthetic to the surgeon armamentarium. The debate for the ideal surgical approach for placing mesh continues to be unanswered, although each approach has its ardent supporters, there is few data carefully evaluating each approach in appropriately designed

controlled trial. The three methods are namely onlay (Over the rectus sheath), bridging the fascial defect (inlay) and Sublay (retromuscular preperitoneal)<sup>5</sup>.

The purpose of this study is to evaluate the repair of incisional hernia by two different methods onlay (Conventional method) and sublay (retromuscular preperitoneal) methods at two different tertiary care centres of Karachi. The primary endpoint was hernia recurrence. Secondary endpoints were operative time, length of hospital stay and postoperative complications of the two methods.

## METHODOLOGY

A total of 80 patients with incisional hernia either diagnosed clinically or by ultrasonography over a period of one year from May 2012 to June 2014 who were admitted in surgical ward of Baqai Medical University and surgical unit 1 of Dow university of health sciences were

included in this study. Patients were not operated upon if they had a body mass index (BMI) >40, an American Society of Anesthesiologists (ASA) score of 3, or chronic pulmonary or ischemic heart disease therefore were excluded from study.

Informed consent was taken from all patients and the operation and its complications were explained to them and were allocated to the two groups. It was purposive, non-probability sampling of the patients. Group A (n=40) were treated with sublay method of mesh repair while group B (n=40) underwent open mesh repair with onlay method. The age, patients, sex, location of hernia and size defect, operating time and postoperative complications were recorded and analyzed by using SPSS version 11.

### SURGICAL TECHNIQUE

All surgeries are carried out under General anaesthesia. Patients in group A received a single dose of intravenous broad spectrum antibiotic (a cephalosporin) at induction and two more doses at 8 and 16 hours later. Skin was prepared with povidone iodine solution.

Sublay technique involves the placement of a permanent prosthetic mesh (polypropylene) in a preperitoneal plane. After incising the subcutaneous tissue, the sac was dissected and delineated. The defect, most often in the midline, is opened along the linea alba. A plane is created between the posterior rectus sheath and the peritoneum. The mesh is then apposed to the adhering layers with continuous 1/0 polypropylene sutures. A polypropylene mesh cut to size is placed in the plane created. The mesh is secured with a few interrupted 3/0 polypropylene suture. A suction drain was placed over the mesh. An anterior rectus sheath is closed with con-

tinuous 1/0 polypropylene suture.

Patients in group B under general anaesthesia after cleaning of the skin with iodine solution, surgical incision was given. The hernia sac was either resected or reduced to the abdomen without opening. Intact fascia, approximately 5 cm around the defect was dissected.

A polypropylene mesh (Prolene Ethicon, Germany) was placed on to the anterior rectus fascia (onlay technique) with continuous or interrupted 2/0 and 3/0 polypropylene sutures. Two suction drains were placed above prolene mesh in all patients. Drains were taken when the daily drainage decreased below to 20 cc. immediate postoperative complications were noted. Follow-up of the patients was done in outpatient department 1-4 and 8 week and 24 months after surgery.

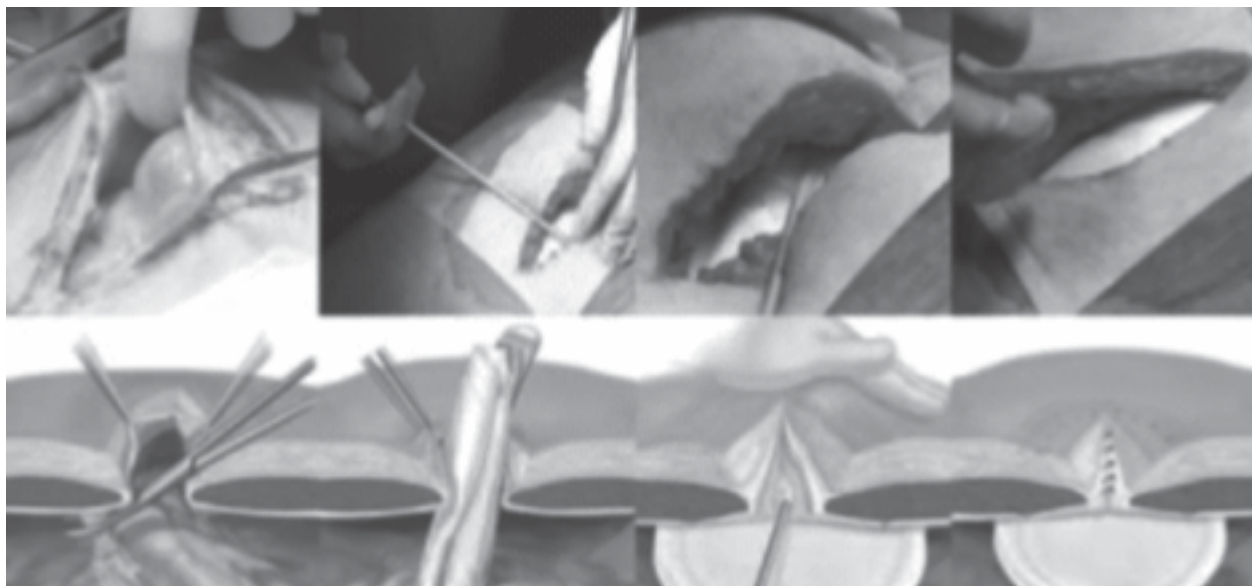
### RESULTS

A total of 80 patients was operated with incisional hernia during our study period. Figure 1 showing the steps of placing mesh in sublay methods. There were 55 women and 25 men. The mean age was  $55.12 \pm 9.749$  years (range 30-85). Demographic characteristics of patients were shown in Table 2.

The most common complaint before surgery was swelling in anterior abdomen 70 (87.5%) pain at hernia site in 10 patients (12.5%). The hernia diagnosis was established with physical examination in 79 patients (99%) and ultrasonography. The most common incision that hernia had been developed was upper midline incision.

In group B, the operative time ranged from 75 to 130 minutes with a mean operative time of 104 minutes, while in group A the operative time ranged from

**Figure 1: Sublay open method of mesh repair using polypropylene mesh**



**Table 1: Demographic details of the patients**

		Group A Sublay Method	Group B Onlay method
Number of patients		40	40
Gender	Female	23	32
	Male	17	8
Hernia Location	Supra umbilical	7	17
	Infraumbilical	17	20
	Umbilical	4	1
	Suprainfraumbilical	12	2

**Table 2: Hospital stay and complications in two groups**

	Group A	Group B	Statistical Significance
Hospitalization days	3.96+ 1.92	2.25+ 0.80	
Complications			
Wound Infection	4(10%)	2(5%)	0.019
Hematoma	5(12.5%)	2(5%)	0.230
Recurrence at 24 months	0	3(7.5)	0
Seroma formation	0	3(7.5%)	0.076

60 to 105 minutes with a mean operative time of 83.5 minutes. Postoperative complications are given in table 3. Four patients of group A developed seroma in 4 patients (10%) in group B, ranging from 50 to 250cc (mean 108.75cc), and all were managed conservatively by aseptic aspiration until dried. 5 patients required a single aspiration and 3 patient needed another two sessions of aspirations every other day.

Other complications like hematoma 4 (5%), and wound infections 6 (7.5%) are seen in Group B but none of them were serious complications and did not require re hospitalization and needed evacuations in opd conservatively.

## DISCUSSION

Abdominal surgical interventions have increased in number in last decades. Approximately two million abdominal operations were performed in USA and about 100 000 incisional hernias were detected annually<sup>6</sup>. Incisional hernia has also become a more commonly encountered surgical pathology worldwide. It causes significant morbidity and mortality in affected patients. Incisional hernia usually presents with an asymptomatic

or painful bulging noticed by the patient over incision scar.

Incisional hernia usually presents with an asymptomatic or painful bulging noticed by the patient over incision scar. The pain is more common in small defects with narrow hernia orifice. The pain was most common symptom in our patients. The defect increases in size with time and serious complications like intestinal strangulation and perforation may occur. While more than half of the incisional hernias are seen in first two years after primary operation, they may also be detected many years after surgery<sup>7-9</sup>.

Although placement of the prosthetic mesh in the subcutaneous plane (onlay technique) is the most popular and most commonly used technique, it is associated with many disadvantages, especially wound infection, seroma formation, and prolonged time of drainage and therefore prolonged hospital stay<sup>10</sup>. Infection remains one of the most common complications of this technique. Stoppa reported an infection rate of 12%<sup>11</sup> while White et al reported an incidence of 6 %<sup>12</sup>.

In this study the onlay technique was associated with an incidence of 10% of wound infection, but all cases

were mild superficial infection, treated conservatively without any surgical intervention. There is no clear explanation to this relatively high incidence of wound infection in a procedure categorized as clean surgery.

However, the presence of the mesh in the subcutaneous plane, the fact that those patients are commonly obese, the prolonged subcutaneous drainage and the accumulation of seroma may represent reasonable explanations<sup>13</sup> while sublay technique this complication is comparatively less. The second most common problem of this technique is seroma formation. The incidence seroma formation in the onlay technique is variable in literature. In this study, postoperative seroma collection occurred in 7.5% of patients, which is close to the incidence reported by White et al in 1998<sup>12</sup>. The third problem is excessive effluent drainage and the need to leave the drain in situ for a long time, resulting into prolonging the hospital stay.

Putting into consideration all these disadvantages of the onlay repair, placement of the mesh in the retromuscular plain seems to be a reasonable alternative. First, this plane is highly vascular, hence, it prevents infection, and if any infection occurs in the subcutaneous plane, it will not affect the mesh, as the mesh is retromuscular in a deeper plane<sup>14</sup>. Second, the prosthesis in this plane cannot be dislodged or ruptured by intra-abdominal pressure, but instead is held in place by the same force that caused the hernia. Third, the prosthesis adheres early to the posterior rectus sheath and renders it inextensible, permitting no further herniation. Finally, the retromuscular space is an already existing anatomical plane, requiring no dissection, and the bare posterior surface of the of the rectus muscles is rich in lymphatics capable to absorb any collecting seroma.

All those benefits were clear in this study; since the incidence of wound infection in the patients where the mesh was placed in the retromuscular plane was lower (5%). Also 3(7.5%) patients developed seroma.

Furthermore in this study the mean operative time was much shorter in the sublay technique (83.5min) compared to the onlay technique (104 min). This difference can be easily explained by elimination of 3 important steps needed in the onlay technique, which are the dissection of big subcutaneous flaps, haemostatis after dissection and mesh fixation.

## CONCLUSION

Sublay repair of incisional hernias, placing mesh in the submuscular plane, is highly effective with a low recurrence rate and acceptable complication rates.

## REFERENCE

1. Kurzer M, Kark A, Selouk S, Belsham P. Open mesh repair of incisional hernia using a sublay technique: long term

followup. *World J Surg* 2008;32:31-6.

2. Nau P, Clark CJ, Fisher M, Walker G, Needleman B J, Ellison C, et al. Modified rives-stoppa repair for abdominal incisional hernias. *Health* 2010;2:162-9.
3. Santora TA, Roslyn JJ. Incisional hernia. *Surg Clin North Am* 1993;73:557-70.
4. Shell DH, De la Torre J, Andrades P, Vasconez LO. Open repair of ventral incisional hernia. *Surg Clin North Am* 2008;88:61-83.
5. Ushcer FC. Hernia repair with. An analysis of 541cases. *Arch Surg* 1962;84:325-8.
6. Ammar S, Ismail T. Abdominal wall hernias in upper Egypt: a different spectrum. *East Cent Afr J Surg* 2008;13:109-13.
7. Rutkow IM. Epidemiologic, economic and sociologic aspects of hernia surgery in the United States in the 1990s. *Surg Clin North Am* 1998;78:941-51.
8. Venclauskas L, Silanskaite J, Kanisauskaite J, Kiudelis M. Long-term results of incisional hernia treatment. *Medicina (Kaunas)* 2007;43:855-60.
9. Luijendijk RW, Lemmen MH, Hop WC, Wereldsma JC. Incisional hernia recurrence following "vest-over-pants" or vertical Mayo repair of primary hernias of the midline. *World J Surg* 1997;21:62-5.
10. Awad ZT, Puri V, LeBlanc K, Stoppa R, Fitzgibbons RJ Jr, Iqbal A, et al. Mechanisms of ventral hernia recurrence after mesh repair and a new proposed classification. *J Am Coll Surg* 2005;201:132-40.
11. Dumanian GA, Denham W. Comparison of repair techniques for major incisional hernia. *Am J Surg* 2003;185:61-5.
12. Stoppa RE. The treatment of complicated groin and incisional hernias. *World J Surg* 1989;13:545-54.
13. White TJ, Santos MC, Thompson JS. Factors affecting wound complications in repair of ventral hernias. *Am Surg* 1998;64:276-80.
14. Milad NM, Said SM, Samir M. Comparison between onlay and retromuscular drainless mesh repair for para-umbilical hernia with divarication of recti. *Kasr El Aini J Surg* 2009;10:11-6.
15. Leithy M, Loulah M, Greida HA, Baker FA, Hayes AM. Sublay hernioplasty versus onlay hernioplasty in incisional hernia in diabetic patients. *Menoufia Med J* 2014 ;27:353-8.

## CONTRIBUTORS

NS did data collection, data analysis and writing of manuscript. SAI, FB did final review and corrections. BAS conceived central idea. All authors contributed significantly to the final manuscript.