

RENAL CELL CARCINOMA AT LOWER POLE MOIETY OF ADULT LEFT DUPLEX KIDNEY

Ateeque Ahmed Khan¹

¹⁻⁴ Dow University of Health Sciences, Civil Hospital, Karachi - Pakistan.

Address for correspondence:

Dr. Ateeq Ahmed Khan

Professor, Department of Radiology, Dow University of Health Sciences, Civil Hospital, Karachi - Pakistan.

E-mail: atrafia@hotmail.com

Date Received:

September 14, 2014

Date Revised:

February 02, 2015

Date Accepted:

November 30, 2015

ABSTRACT

Duplex kidney is an entity which is one of commonest congenital urinary tract anomalies. Overall incidence is 0.8-2 % with bilateral in 20% of cases along with female preponderance. Presentation of duplex kidney and diagnosis is common at pediatric age and rarely presents at adulthood because of complications associated with duplex kidney. Duplex system is defined as kidney with two pelvicalyceal system with single or double ureter or single renal parenchyma containing two pelvicalycealsystems. In literature review it is well documented that duplex system is associated with complications such as hydronephrosis, calculi formation, ureterocele, vesicoureteric reflux and recurrent infection. Duplex system is also prone to development of renal pelvis carcinomas as compared to normal kidney as was in our case. In literature only four cases of renal cell carcinoma have reported so far which were associated with duplex kidney but these were either multicystic transitional cell carcinomas of renal pelvis or one case of cystic renal cell sarcomatoid carcinoma. Here we present very rare case of duplex kidney with lower pole moiety renal cell adenocarcinoma of solid nature. Patient presented with left lion pain and burning micturition. Patient had history of recurrent infection with left lumbar pain in the past. Ultrasound, intravenous pyelogram and CT SCAN of abdomen revealed duplex kidney and double ureters on left side with large solid enhancing mass in lower pole moiety left kidney. Histopathology confirms diagnosis of renal cell adenocarcinoma. It is vital to detect duplex system at earliest stage to detect associated complications especially renal carcinoma using imaging so as to conserve partial kidney and its function while remove tumor at early stage in order to reduce morbidity and mortality.

Key Words: Renal Malignancy, Duplex Kidney, Renal Carcinoma

This case report may be cited as: Khan AA. Renal cell carcinoma at lower pole moiety of adult left duplex kidney. *J Postgrad Med Inst* 2015; 29(4): 313-6.

INTRODUCTION

Duplex kidney (DK) is the most common congenital abnormality of the urinary tract, with an incidence of around 0.8- 2%^{1,2}. Basis of duplex kidney formation by embryology is explained as development of two ureteral buds separately from a single mesonephric duct gives rise to a duplex kidney with complete ureteral duplication. On the other hand, bifurcation of a single ureteral bud proximal to the ampulla gives rise to a duplex kidney with a bifid pelvis or ureter³. Duplex system is explained as the kidney with two pyelocaliceal systems, which may have either single or bifid ureter (partial duplication) or double ureterdraining separately into the urinary bladder (complete duplication), with a single renal parenchyma that is drained by two pyelocaliceal systems⁴. In literature review it is well documented that duplex system is associated with complications such as hydronephrosis, calculi formation, ureterocele, vesicoureteric reflux and recurrent infection⁵. Duplex system

is also prone to development of renal pelvis carcinomas as compared to normal kidney because of continuous injury from repeated infection, trauma and inflammation from calculi resulting into urothelial metaplasia and neoplasia^{6,7}.

CASE REPORT

Our patient was middle aged 40 years old, presented with left lumbar pain and discomfort since six month. Pain was gradual in onset with increasing in intensity with time. Patient also has hematuria. Past history of recurrent urinary tract infection with left lumbar pain. His urine detail report showed RBC and WBC. Blood picture showed normal values of blood and white cell count along with low Hemoglobin. Intravenous pyelography followed by post contrast CT scan abdomen was performed. Intravenous pyelography document left renal duplex system with large mass at lower pole moiety of left kidney but pelvi-calyceal system appears intact only displacement was seen.. Double ureters also identified

with mild fullness in left lower moiety ureter. Concomitant CT scan abdomen demonstrate duplex left kidney and double ureters with large solid enhancing mass at lower pole moiety of left duplex kidney which is indenting and displacing lower pole moiety pelvi-calyceal system without invading and upper pole moiety pelvi-calyceal system of left duplex kidney was intact. Renal capsule of left duplex kidney was intact. No abdominal lymphadenopathy was identified. No metastasis in lung, liver or spine was seen. Patient was operated and tumor resected with preserving surgery for upper pole moiety of left renal duplex system was carried out. Histopathology revealed renal cell carcinoma (adenocarcinoma).

DISCUSSION

Duplex kidney is relatively common anomaly among congenital urinary tract anomalies but association of duplex kidney with urothelial malignancy is extremely rare⁸. Only few cases of duplex kidney with urothelial malignancy so far have been reported in international literature^{6,7,8}. In all these cases urothelial malignancy was most commonly transitional cell carcinoma and then sarcomatoid carcinoma⁹. There was one case of multicystic renal cell carcinoma⁸ while in our case solid renal cell adenocarcinoma was detected which is unique in sense that not a single case of solid renal cell carcinoma with duplex kidney has documented in local or international literature. Renal sparing surgery gives very good prognosis in cases of early diagnosis of duplex kidney with renal malignancies like renal cell carcinoma or mul-

ticystic renal cell carcinoma which have good prognosis with preservation of normal function of remaining kidney⁸ as seen in our case in which left duplex kidney was associated with lower moiety renal cell carcinoma. For such cases early diagnosis of duplex kidney with follow up by ultrasound to keep checking about complications associated with duplex kidney especially any growth. In such cases then immediately carryout intravenous pyelography and followed by post contrast CT scan abdomen for extension and localization of tumor so as to consider nephron sparing surgery can be possible or not^{10,11}, as was seen in our case in which early diagnosis of duplex kidney with lower moiety renal cell carcinoma which has spared the lower moiety pelvi-calyceal system as well as upper moiety pelvi-calyceal system, making nephron sparing surgery possible with good prognosis. Intravenous pyelography has vital role not only clearly demonstrating duplex pelvi-calyceal system and ureters but also clearly documenting the sparing of upper pole moiety parenchyma and pelvi-calyceal system as well as pelvi-calyceal system of lower moiety as compared to CT scan because of large tumor overlap with renal parenchyma on CT scan.

CONCLUSION

Early detection of duplex kidney either on ultrasound or intravenous pyelography is very important because that will help to monitor patient for development of complications associated with duplex kidney especially urothelial malignancy at early stage in order to make

Figure 1: Left duplex kidney with large soft tissue mass at lower pole displacing lower moiety pelvicalyceal system of left duplex kidney

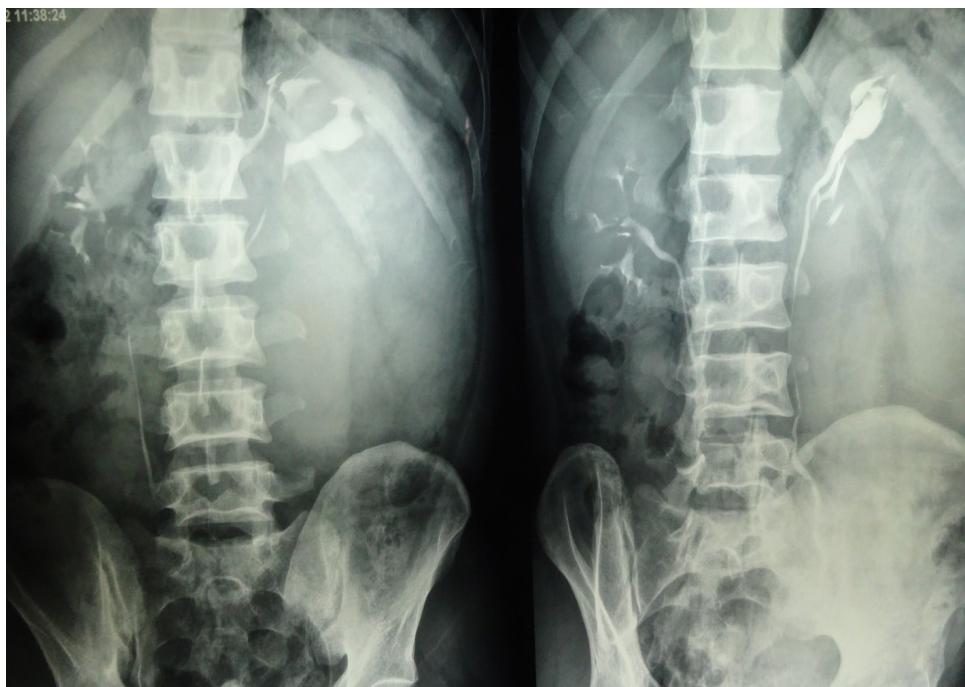


Figure 2: Ct scan abdomen post contrast axial scan. Left duplex kidney with large heterogeneously enhancing mass(renal cell carcinoma) arising from lower pole moiety of left duplex kidney with displacing but sparing pelvicalyceal system of lower moiety as well as sparing of upper moiety of left duplex kidney

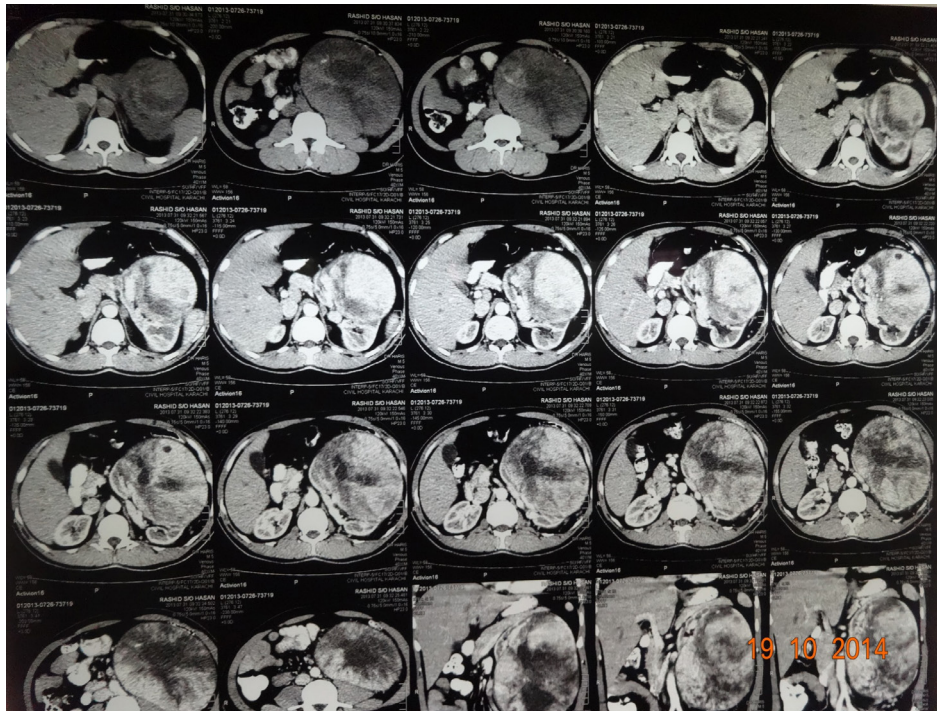


Figure 3: Ct scan abdomen axial and coronal post contrast scans. Left duplex kidney with large heterogeneously enhancing mass(renal cell carcinoma) arising from lower pole moiety of left duplex kidney with displacing but sparing pelvicalyceal system of lower moiety as well as sparing of upper moiety of left duplex kidney

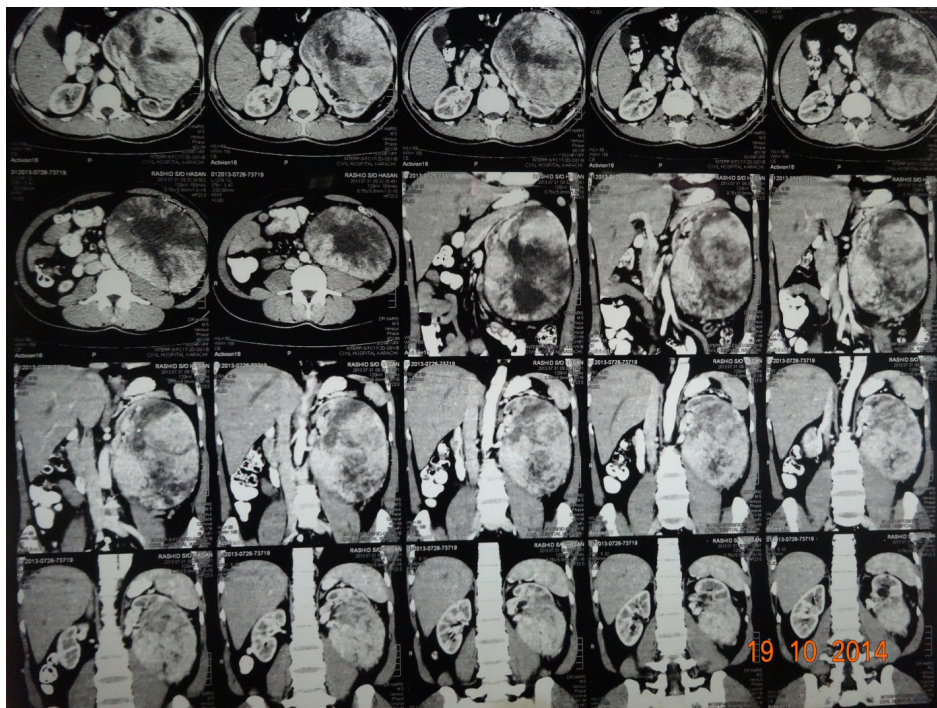
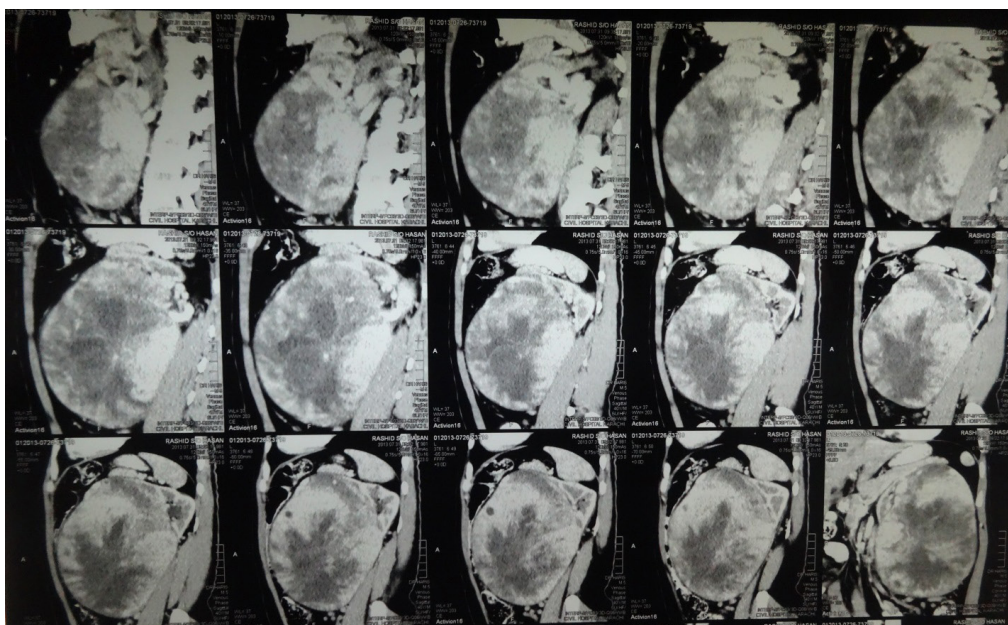


Figure 4: Ct scan abdomen sagittal post contrast scans. Left duplex kidney with large heterogeneously enhancing mass(renal cell carcinoma) arising from lower pole moiety of left duplex kidney with displacing but sparing pelvicalyceal system of lower moiety as well as sparing of upper moiety of left duplex kidney



nephron sparing surgery favorable for patient with surgical removal of tumor and cure of patient. This will reduce the morbidity and mortality of patient with sparing of function of remaining duplex kidney.

REFERENCES

1. Malek RS, Kelalis PP, Stickler GB, Burke EC. Observations on ureteral ectopy in children. *J Urol* 1972; 107:308-13
2. He XH, Lu N, Zhang R, Zhu LW. Duodenal metastases of renal cell carcinoma: a case report. *Chin Med J* 2010; 123:1228-9. *Chin Med J* 2010; 123: 1228-1229
3. Dalla Palma L, Bazzocchi M, Cressa C, Tommasini G. Radiological anatomy of the kidney revisited. *Br J Radiol* 1990; 63:680-90.
4. Glassberg KI, Braren V, Duckett JW, Jacobs EC, King LR, Perimutter AD, et al. Suggested terminology for duplex systems, ectopic ureters and ureteroceles. *J Urol* 1984; 132:1153-4.
5. Prakash, Rajini T, Venkatiah J, Bhardwaj AK, Singh DK, Singh D. Double Ureter and Duplex System A Cadaver and Radiological Study. *Urol J* 2011; 8:145-8.
6. Mizusawa H, Komiyama I, Ueno Y, Maejima T, Kato H. Squamous cell carcinoma in the renal pelvis of a horse-shoe kidney. *Int J Urol* 2004; 11: 782-4.
7. Ujike T, Noda Y, Oka D, Takada S, Fujimoto N, Koide T, et al. Squamous cell carcinoma of the renal pelvis with giant hydronephrosis. *Hinyokika Kiyo* 2003; 49: 757-9.
8. Liu GM, Ma HS, Li YM. Multilocular Cystic Renal Cell Carcinoma in Lower Pole Moiety of a Duplex Kidney. *Int J Surg Pathol* 2012; 20:613-7.
9. Chen GM, Chen SW, XIA D, LI J, YAN S, JIN BY. Sarcomatoid carcinoma of the renal pelvis in duplex kidney. *Chin Med J* 2011; 124:2074-6.
10. Moinzadeh A, Gill IS, Finelli A, Kaouk J, Desai M. Laparoscopic partial nephrectomy: 3-year follow-up. *J Urol* 2006; 175:459-62.
11. Gur U, Yossepowitch O, Baniel J. Transitional cell carcinoma in a fused crossed ectopic kidney. *Urology* 2003; 62:748.