

IS RETINOPATHY DUE TO STARGARDT'S DISEASE OR AFTER MALARIA TREATMENT WITH CHLOROQUINE?

Shagufta Zia¹, Yusra Amanullah², Ahmedyar Hasan³

¹ Medcare Medical Center, Dubai - UAE.

² Army Medical College Rawalpindi - Pakistan.

³ Mohammed Bin Rashid University of Medicine and Health Sciences, Dubai - UAE.

Address for Correspondence:

Dr. Shagufta Zia

Medcare Medical Center, Dubai - UAE.

Email: shagufta@medcarehospital.com

Date Received: May 19, 2018

Date Revised: November 11, 2018

Date Accepted: November 16, 2018

ABSTRACT

Central vision impairment associated with macular degeneration in young adults in the absence of other chronic conditions can be associated with an autosomal recessive condition known as Stargardt's Disease (SD). One of the serious complications of long term malaria prophylaxis (LTMP) is maculopathy associated with chloroquine treatment. This complication can cause blindness as well as permanent visual impairment. Evidence suggests that the cumulative dose of LTMP should not exceed 140 g for subjects at risk of chloroquine retinopathy (CR). We present a case of macular degeneration with possible genetic inheritance associated with SD. However, presentation was associated with chloroquine treatment for malaria as a single dose of 120g over three days. Periodic screening is required since a threshold dose of chloroquine for causing toxicity in the retina has not yet been established.

Key Words: Stargardt's Disease, Chloroquine, Chloroquine retinopathy

This case report may be cited as: Zia S, Amanullah Y, Hasan A. Is retinopathy due to Stargardt's Disease or after malaria treatment with chloroquine? *J Postgrad Med Inst* 2018; 32(4): 412-3.

INTRODUCTION

Stargardt's Disease (SD) is an autosomal recessive macular dystrophy with a prevalence of approximately 1 in 10,000¹. A typical characterization of the disorder is impairment of central vision within the first two decades of life, with normal peripheral and colour vision. It is a slowly progressive condition up to the level of legal blindness¹. Prognosis of the disease and its clinical presentation varies, depending on the change in type of gene. An accepted complication of chloroquine treatment, given for long-term malaria prophylaxis (LTMP), is chloroquine retinopathy (CR)². Chloroquine toxicity affects the retinal pigment epithelium (RPE), progressing to bull's-eye maculopathy. Hobbs et al³ first reported CR as pre-maculopathy which was reversible upon the discontinuation of chloroquine treatment⁴.

CASE REPORT

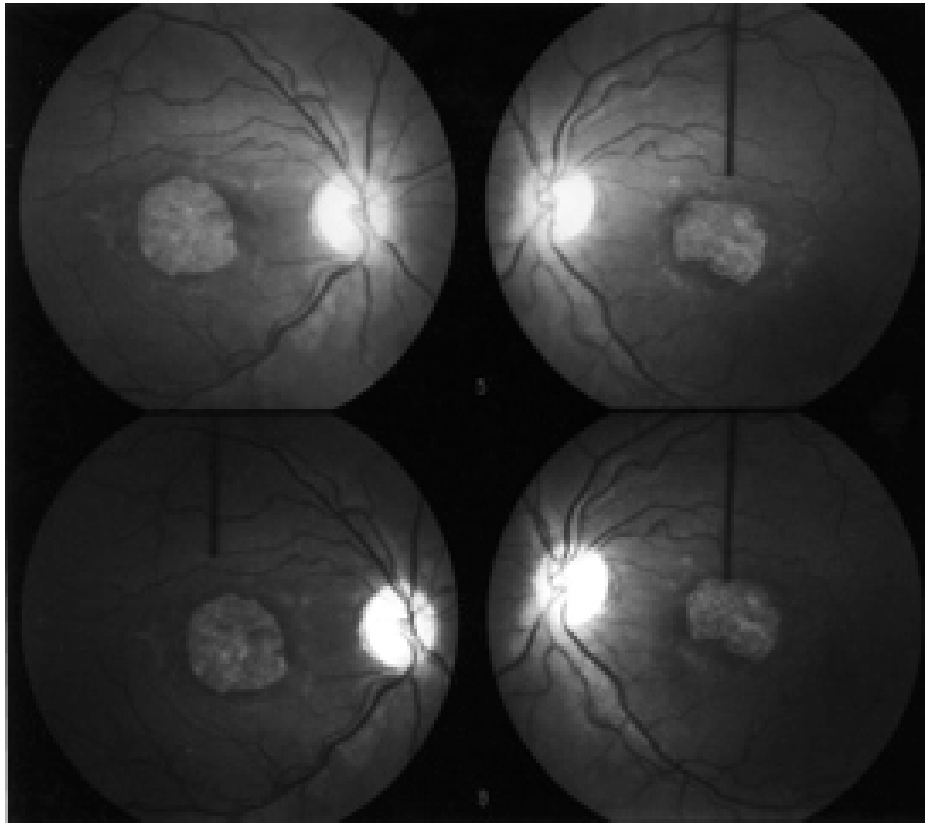
A 51 years old Asian female attended her GP for worsening eye sight. After attending an ophthalmology clinic, her visual acuity was 6/24(R) and 6/18(L), with normal visual fields and color vision. Fundus examination showed macular lesions (Figure 1). Her history showed that at the age of 18 years, she was treated with oral chloroquine (41.7mg chloroquine phosphate/kg or 25mg base/kg) for 3 days after complaining of headaches and high-fever. A total of 120g chloroquine was administered and her symptoms were successfully treated. Two years later, she complained of blurred dis-

tant vision, photophobia and difficulty in reading. Since known risk factors for retinal disease (excluding age) were absent, CR was suspected. This was further evident from the history of chloroquine use in the past, which is associated with retinal-lesions. Additionally, there was no immediate family history of retinal degeneration or macular dystrophy. However, three years later after the above presentation, (in 1989), her nephew was diagnosed with retinitis pigmentosa plus night blindness. It was also revealed that a great grand uncle had night blindness at a younger age and severe visual impairment. Therefore, the genetic inheritance type of maculopathy such as SD rather than CR was more suggestive in this case.

DISCUSSION

Several cases of retinopathy have been reported after chloroquine treatment for LTMP^{4,5}. Establishing when LTMP should be stopped and its safe dosage is particularly important. It has been predicted that the cumulative dose may play a more important role than the dosing regimen of chloroquine⁵. For instance, there is a possibility that a weekly regimen may not prevent but only delay the onset of retinopathy.

Both SD and CR present with low visual acuity, with normal color and peripheral vision. Fluorescein angiogram is the key diagnostic test to distinguish between SD and other retinopathies. Typically, in SD, the macula has a 'beaten-bronze' appearance, with scattered yel-

Figure 1: Macular lesions on fundus examination

low-white flecks within the posterior pole and in the mid-peripheral retina, with a diffuse abnormality at the level of the retinal pigment epithelium¹ and dark chorioid effect². While in CR, the retina has a bull's-eye maculopathy.

SD typically affects one generation. It is possible for only one person in a family to have SD. When both parents are carriers, there is a 25% probability of inheritance⁶. Rarely, an autosomal dominant form of Stargardt-like Disease inheritance occurs and can be passed from one generation to the next, with 50% probability⁶.

CONCLUSION

Genetic inheritance type of maculopathy such as Stargardt's Disease rather than chloroquine retinopathy was more suggestive in this case. Early ophthalmological and bi-annual follow-up examinations for subjects undergoing LTMP is crucial. At a clinically benign stage, stopping the chloroquine treatment may stabilize maculopathy. Also genetic inheritance should be excluded in early onset macular degeneration.

REFERENCES

1. Lois N, Halfyard AS, Bird AC, Holder GE, Fitzke FW. Fundus autofluorescence in Stargardt macular dystrophy-fundus flavimaculatus. *Am J Ophthalmol* 2004; 138:55-63.
2. Nylander U. Ocular damage in chloroquine therapy. *Acta Ophthalmol (Copenh)* 1967; 9:1-71.
3. Hobbs HE, Sorsby A, Freedman A. Retinopathy following-chloroquine therapy. *Lancet* 1959; 2: 478-80.
4. Kellner U, Kraus H, Foerster MH. Multifocal ERG in chloroquine retinopathy: regional variance of retinal dysfunction. *Graefes Arch Clin Exp Ophthalmol* 2000; 238:94-7.
5. Bertagnolio S, Tacconelli E, Camilli G, Tumbarello M. Case report: retinopathy after malaria with chloroquine. *Am J Trop Med Hyg* 2001; 65:637-8.
6. Westerfeld C, Mukai S. Stargardt's Disease and the ABCA gene. *Semin Ophthalmol* 2008; 23:59-65.