

# EXPERIENCE OF FOREIGN BODY REMOVAL BY FLEXIBLE BRONCHOSCOPY IN A TERTIARY CARE HOSPITAL

Muhammad Hussain<sup>1</sup>, Syed Mazhar Ali Naqvi<sup>2</sup>

<sup>1,2</sup> Pulmonology and Critical Care Department, Services Hospital, Lahore - Pakistan.

**Address for correspondence:**

**Dr. Muhammad Hussain**  
380-2-D2 Green Town, Lahore - Pakistan.

Email: hussainmeo@gmail.com

Date Received:

July 20, 2018

Date Revised:

August 15, 2019

Date Accepted:

August 23, 2019

## ABSTRACT

**Objective:** To determine the outcome of removal of tracheobronchial foreign bodies by flexible bronchoscopy and related complications.

**Methodology:** We retrospectively reviewed patients with foreign bodies (FBs) treated between January 2010 and May 2018 at Pulmonology department. The demographic and endoscopic data was collected and analyzed.

**Results:** A total of 30 adult patients (12 men and 18 women) with an average age of  $35 \pm 7.24$  years were analyzed. Most common FBs included metallic pin ( $n=16$ , 53%), metallic nut-bolt ( $n=4$ , 13%), whistles ( $n=4$ , 13%), nut shells ( $n=2$ , 6%), bone ( $n=2$ , 6%), dental prosthesis ( $n=1$ , 3%) and dental brush ( $n=1$ , 3%). The prevalence of FB-related complications was 75%, including granulation formation (70%), obstructive pneumonia (20%), hemorrhage (20%), atelectasis (13%) and endobronchial stenotic scarring (10%). In 96% of the patients, the FBs were successfully removed with flexible video bronchoscopy and 01 patient required rigid bronchoscopy.

**Conclusion:** There was high frequency of FB-related complications likely due to prolong delay between aspiration and diagnosis. The removal of foreign bodies under flexible video bronchoscopy has a significant success rate and therefore can be used in adults.

**Key Words:** Foreign body, Flexible bronchoscopy, Adults

This article may be cited as; Hussain M, Naqvi SMA. Experience of foreign body removal by flexible bronchoscopy in a tertiary care hospital. *J Post Grad Med Inst* 2019; 33(3): 237-41.

## INTRODUCTION

Foreign body (FB) aspiration into the airway is not uncommon and can lead to acute emergency like choking and respiratory compromise or chronic problems like asthma, chronic cough, hemoptysis, pneumonia, abscess and bronchiectasis. Symptoms could remain unnoticed for months to years<sup>1,2</sup>. Foreign body may lead to granulation formation causing recurrent pneumonia, atelectasis and endobronchial stenotic scarring if the intervention is delayed<sup>3-8</sup>. Early Foreign body removal can reduce the chronic complications and significant morbidity.

Rigid bronchoscopy has been the tool of choice under GA for foreign body extraction but now flexible bronchoscope is one of the most commonly used tool<sup>9,10</sup>. A few published studies have described the clinical features and endoscopic management of tracheobronchial foreign body. The aim of this study was to report our experience using flexible video bronchoscopy for the removal of FBs and related complications of FBs aspiration.

## METHODOLOGY

Between January 2010 and May 2018, total of 30 adult patients with foreign body aspiration were managed in Pulmonology and Critical Department of Services Hospital, Lahore. Available medical history, physical examination and chest radiograph were obtained from record of patients with foreign body inhalation. Bronchoscopic findings, complications and procedure related issues were noted not only from record but videos of the procedure were reviewed by authors.

Topical anesthesia was given intra-nasally and orally using 2-4% lidocaine and with 2% lidocaine endobronchially. Sedation with intravenous diazepam or propofol was used when necessary. Flexible bronchoscopes (6c.260 or 1T.240) (Olympus, Tokyo, Japan) were used in all patients. The accessories used to remove the FBs included FB forceps (Rat-tooth, Alligator, Dormia Basket, three prongs and tooth forceps). We introduced bronchoscope via mouth protected by bite guard. Bronchial tree was examined, complications like granulation, slough, hemorrhage or mucosal injury was noted and FB was localized. Granulation removed if required with

help of electrocautery. Norepinephrine was sprayed locally to stop any bleeding when necessary. After removal of foreign body, effected area was again examined and hemostasis secured if required.

The patient demographic data, including age, sex, and symptoms; endoscopic findings including the types, number and location of FBs; FB-related complications; time of diagnosis (which was measured as the time between symptom onset and diagnosis for the patients); endoscopic methods used to remove the FBs; and accessory devices used were collected and analyzed.

## RESULTS

Thirty patients, 12 (40%) men and 18 (60%) women were enrolled in the study. The mean age was  $35 \pm 7.24$  years with range of 12 to 60 years. Majority of patients (80%) were adult (14-25 years) and only 10% were of middle age. A compatible history suggestive of FBs aspiration was found in 90% (n=27) of the patients while 10% (n=3) were examined for non-resolving pneumonia. The main presenting symptoms are given in Table 1. Fourteen (46.6%) patients were diagnosed between two days and one week (including one week) and six patients (20%) were diagnosed between one week and one month (including one month) after aspiration or development of symptoms. Ten patients (33.0%) delayed the diagnosis until more than one month after

aspiration or the development of symptoms. The longest delay was 10 years with two times intake of ATT for chronic cough and recurrent fever. The nature of the FB was confirmed visually during bronchoscopy. The types of FBs are given in Figures 1 and 2.

The frequency of FB-related complications was 75%, as given in Table 1. The Rate and severity of complications were associated with the duration the FBs stayed in the airway.

The overall success rate for removal was 96%. Bronchial bleeding was the most common procedure-related complication (25%). The commonly used accessory devices were FB forceps Rat-tooth (90%) followed by biopsy forceps (7%) and FB baskets (3%). Furthermore, electrocautery coagulation was used in one patient with a bone located in the right lower lobe embedded in the mucosa on both sides and partially epithelized. In one patient, a toy in the form of whistle was embedded, with history of its inhalation 5 years ago that covered with granulation, scar tissue and secretions. After removal of granulation, it was noted to be fully embedded in the bronchus and we were unable to remove it in LA. Therefore, it was removed under GA with rigid bronchoscope after removal of slough, granulation and scar tissue with help of electrocautery.

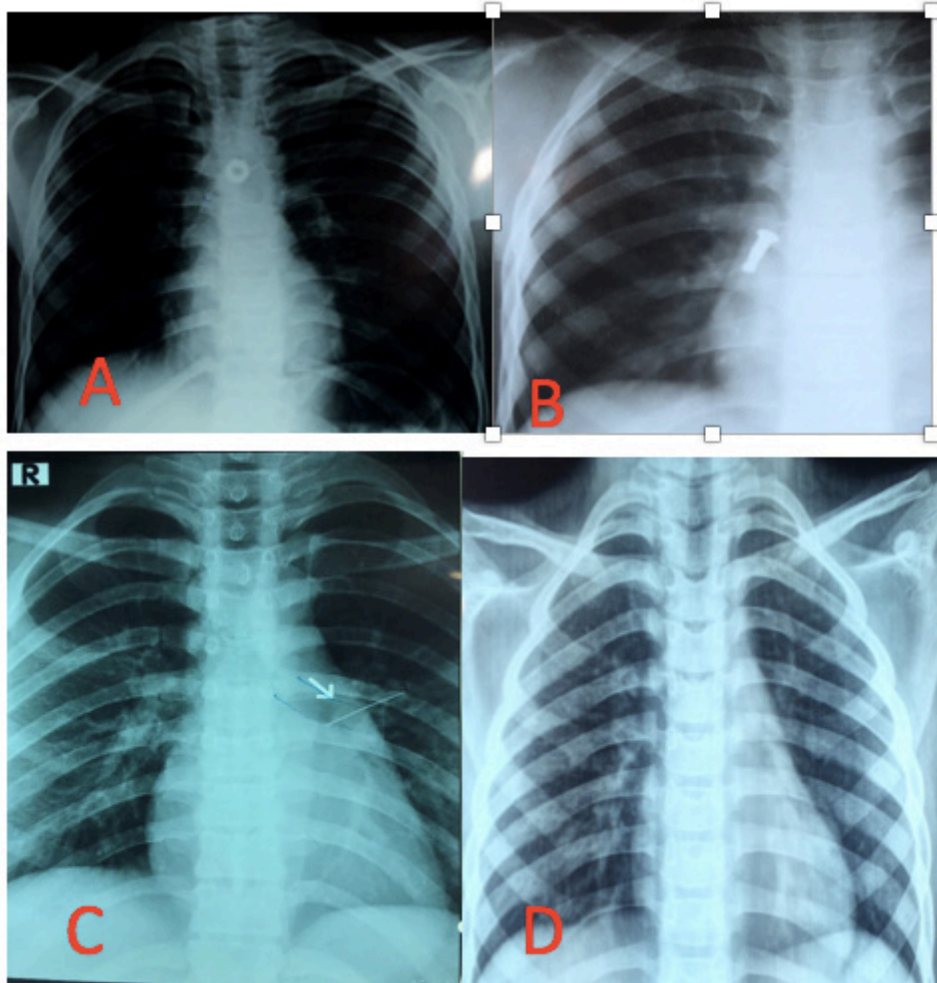
**Table 1: Symptoms and complications in patients presenting with foreign body inhalation**

Variable		Frequency	Percentage
Symptoms	Cough	17	56.6%
	Sudden Choking	07	23.3%
	Dyspnea	04	13.3%
	Hemoptysis	03	10%
	Fever	02	6.6%
	Chest Pain	01	3.3%
Complications	Granulation	21	70%
	Obstructive Pneumonia	06	20%
	Hemorrhage	06	20%
	Atelectasis	04	13.3%
	Stenosis/Scarring	03	10%

**Figure 1: Various foreign bodies removed endoscopically, saved in formalin jar. (Rusting is due to storage)**



**Figure 2: X- rays of foreign bodies including bolt (A) nail cutter part (B), scarf pin (C) and a whistle (D) causing retrocardiac collapse in a young boy**



## DISCUSSION

Removal of tracheobronchial FBs by endoscopists were rare in past but practice changed after flexible bronchoscopy and revolutionized after video bronchoscopy. Nowadays many centers are removing FBs endoscopically. The largest series of adults with FBs in the existing studies included 100 cases in Vietnam and 200 adult Chinese patients<sup>10,11</sup>. The age and sex distributions were different from the studies due to different customs. Most of our patients were young female inhaling metallic scarf pin which they used for anchoring scarf, very common in student age in Punjab and Pakistan. Same was the reason that our patients presented early with definite history of inhaling FBs. In our study, few of FB aspirations occurred in older patients with neurological issues. We didn't found bones, nuts/ nut shells and food boluses commonly in our population due to food habits of this region. Nuts/nut shell or Chalia like FBs are more common in Karachi due to traditional Pan chewing. Many people sleep with beetle nut in mouth and aspirate during sleep.

The success rate of flexible bronchoscopy is comparable to that using rigid bronchoscopy (92%-98% vs. 95%)<sup>3,12-16</sup>. Both are suitable for the removal of FBs. However, the procedure under flexible bronchoscopy is more acceptable for patients and endoscopist due to short procedure time, low cost and few complications. With the new advances many difficult FBs like embedded in the mucosa, large one and with extensive granulation can be removed with help of argon plasma coagulation and cryoprobe<sup>17-19</sup>. Another intermediate advantage is the removal of FBs under GA with laryngeal mask airway (LMA) using video bronchoscope in younger children (8-10 years old) or very uncooperative patients. We used this procedure in two young kids (didn't included in this study) using LMA, deep sedation, paralysis and video bronchoscope.

## CONCLUSION

There was high frequency of FB-related complications likely due to prolonged delay between aspiration and diagnosis. The removal of foreign bodies under flexible video bronchoscopy has a significant success rate and therefore can be used in adults. Clinicians should be aware of FB aspiration, because it may explain the origin of unknown chronic cough and recurrent pneumonia and fever. Early diagnosis and early intervention are key to success in experienced hands.

## ACKNOWLEDGEMENTS

We are indebted to Prof. Dr. Kamran Khalid Chima for his continuous guidance and training and our bronchoscopy paramedical staff for their support during the procedures.

## REFERENCES

1. Scully RE, Mark EJ, McNeely WF, Ebeling SH, Phillips LD. Case records of the Massachusetts General Hospital. Weekly clinicopathological exercises: Case 20-1997. A 74-year-old man with progressive cough, dyspnea and pleural thickening. *N Engl J Med* 1997; 336:1895-903.
2. Al-Majed SA, Ashour M, al-Mobeireek AF, al-Hajjaj MS, Alzeer AH, al-Kattan K. Overlooked inhaled foreign bodies: Late sequelae and the likelihood of recovery. *Respir Med* 1997; 91:293-6.
3. Mise K, Jurcev Savicevic A, Pavlov N, Jankovic S. Removal of tracheobronchial foreign bodies in adults using flexible bronchoscopy: Experience 1995-2006. *Surg Endosc* 2009; 23:1360-4.
4. Moisan TC. Retained endobronchial foreign body removal facilitated by steroid therapy of an obstructing, inflammatory polyp. *Chest* 1991; 100:270.
5. Debeljak A, Sorli J, Music E, Kecelj P. Bronchoscopic removal of foreign bodies in adults: Experience with 62 patients from 1974-1998. *Eur Respir J* 1999; 14:792-5.
6. Lai YF, Wong SL, Chao TY, Lin AS. Bronchial foreign bodies in adults. *J Formos Med Assoc* 1996; 95:213-7.
7. Moura e Sá J, Oliveira A, Caiado A, Neves S, Barroso A, Almeida J et al. Tracheobronchial foreign bodies in adults-experience of the Bronchology Unit of Centro Hospitalar de Vila Nova de Gaia. *Rev Port Pneumol* 2006; 12:31-43.
8. Baharloo F, Veyckemans F, Francis C, Bietot MP, Rodenstein DO. Tracheobronchial foreign bodies: Presentation and management in children and adults. *Chest* 1999; 115:1357-62.
9. Lan RS. Non-asphyxiating tracheobronchial foreign bodies in adults. *Eur Respir J* 1994; 7:510-4.
10. Nguyen LH, Nguyen DH, Tran TN, Nguyen PT, Thi QH, Aelony Y et al. Endobronchial foreign bodies in Vietnamese adults are related to eating habits. *Respirology* 2010; 15:491-4.
11. Dong YC, Zhou GW, Bai C, Huang HD, Sun QY, Huang Y et al. Removal of tracheobronchial foreign bodies in adults using a flexible bronchoscope: Experience with 200 cases in China. *Intern Med* 2012; 51:2515-9.
12. Soysal O, Kuzucu A, Ulutas H. Tracheobronchial foreign body aspiration: A continuing challenge. *Otolaryngol Head Neck Surg* 2006; 135:223-6.
13. Limper AH, Prakash UB. Tracheobronchial foreign

- bodies in adults. *Ann Intern Med* 1990; 112:604-9.
14. Mantel K, Butenandt I. Tracheobronchial foreign body aspiration in childhood: A report on 224 cases. *Eur J Pediatr* 1986; 145:211-6.
  15. Tang LF, Xu YC, Wang YS, Wang CF, Zhu GH, Bao XE et al. Airway foreign body removal by flexible bronchoscopy: experience with 1027 children during 2000-2008. *World J Pediatr* 2009; 5:191-5.
  16. Ibrahim Sersar S, Hamza UA, AbdelHameed WA, AbdulMaaty RA, Gowaeli NN, Moussa SA et al. Inhaled foreign bodies: Management according to early or late presentation. *Eur J Cardiothorac Surg* 2005; 28:369-74.
  17. Bolliger CT, Mathur PN, Beamis JF, Becker HD, Cavaliere S, Colt H et al. ERS/ATS statement on interventional pulmonology. *European Respiratory Society/American Thoracic Society. Eur Respir J* 2002; 19:356-73.
  18. Bolliger CT, Sutedja TG, Strausz J, Freitag L. Therapeutic bronchoscopy with immediate effect: Laser, electrocautery, argon plasma coagulation and stents. *Eur Respir J* 2006; 27:1258-71.
  19. Mathur PN, Wolf KM, Busk MF, Briete WM, Datzman M. Fiberoptic bronchoscopic cryotherapy in the management of tracheobronchial obstruction. *Chest* 1996; 110:718-23.

#### CONTRIBUTORS

MH initiated manuscript writing after designing the study and performing bronchoscopies. SMAN reviewed the manuscript, helped perform bronchoscopies and collected the data after bronchoscopic procedures. All authors contributed significantly to the submitted manuscript.