

INTRACARDIAC ECHOCARDIOGRAPHY: AN EXTRAORDINARY TOOL TO ABLATE TYPICAL ATRIAL FLUTTER

Imran Khan¹, Bakhtawar Shah², Zahid Aslam Awan³

¹⁻³ Department of Cardiology and Electrophysiology, Hayatabad Medical Complex, Peshawar - Pakistan.

Address for correspondence:
Dr. Imran Khan

Department of Cardiology and Electrophysiology, Hayatabad Medical Complex, Peshawar - Pakistan.

E-mail: Khan114@hotmail.com.

Date Received:

January 10, 2019

Date Revised:

December 11, 2020

Date Accepted:

December 21, 2020

ABSTRACT

Objective: To determine the role of intra cardiac echocardiography in ablating typical atrial flutter.

Methodology: This cross sectional study was conducted in the Department of Cardiology, Hayatabad Medical Complex, Peshawar from June 2006 to June 2018. All patients with typical atrial flutter were included while those with atypical atrial flutter and scar related flutter were excluded. ICE was used in 06 cases. Conventional five wire study was performed. Cavotricuspid isthmus (CTI) was located electro anatomically using fluoroscopic or with the help of intra cardiac echocardiography (ICE) guidance. Ablation was done using standard protocols with 60 degree Celsius temperatures and 40-50 watts power in case of use of therapy catheter. In case of irrigated cooled tip catheter, the flow was kept at 30 ml/hour and the power at 30 watts. CTI was ablated and booster burns applied. Trans-isthmus conduction time and bidirectional block was documented. The data were analyzed using SPSS version 23.

Results: Out of 1738 cases of different arrhythmias admitted for elective ablation, 48 cases were typical flutter. All the 6 cases that were ablated with ICE guidance had lesser procedure time and flouro time with better success and low recurrence.

Conclusion: Intracardiac echocardiography (ICE) has the capability to reveal the anatomy of the cavotricuspid isthmus and guide ablation in difficult cases.

Key Words: Atrial flutter, Cavotricuspid isthmus, Intracardiac echocardiography

This article may be cited as: Khan I, Shah B, Awan ZA. Intracardiac echocardiography: An extraordinary tool to ablate typical atrial flutter. J Postgrad Med Inst 2021; 34(3): 203-207.

INTRODUCTION

Atrial flutter is a common arrhythmia¹. The mechanism is reentry circuit². When the circuit involves the CTI, CTI dependent flutter or typical flutter occurs³. When the circuit revolves around a scar tissue, it is called atypical flutter or non-isthmus-dependent atrial flutter⁴. Both typical and atypical flutter can be clockwise or counter clockwise. Atrial flutter rate reaches up to 350 per minutes in its circuit but the ventricular conduction is dropped due to the decremental properties of the atrio-ventricular node (AV node)⁵. Most of the time there is variable block with 2:1, 3:1 due to this decremental property. But at times the AV nodal conduction is fast and the patient become symptomatic due to fast ventricular response. Nonetheless, even if the ventricular response is not very fast and the arrhythmia is not symptomatic, still thromboembolic phenomena is the drastic complication^{6,7}. The fluttering atria, lead to

stagnation of blood which facilitates clot formation and then embolism. Beside thromboembolic phenomena, tachycardia induced cardiomyopathy⁸ is another deadly complication.

The management strategies of atrial flutter are not straight forward⁹. The patient can be reverted to sinus rhythm with overdrive pacing, antiarrhythmic drugs or electric cardioversion¹⁰⁻¹². Cardioversion and overdrive pacing cannot guarantee prolonged sinus rhythm and there may be recurrence^{13,14}. Moreover, these procedures need anticoagulation. Alternatively, patient may need to take anti-arrhythmics along with anticoagulants for life with all possible risks of complications of antiarrhythmic and anticoagulant drugs. Compliance of patients for such complicated regimens may be another problem¹⁵⁻¹⁹. Above all, the availability and affordability of effective drugs for flutter is also an issue in developing world²⁰. Ablation of atrial flutter is a permanent rem-

edy with very low complication rate²¹. The success rate of ablation in typical flutter is very reasonable and cost effective while in atypical flutter it is acceptable²²⁻²⁴. Atrial flutter ablation is done under fluoroscopy and electrocardiographic guidance. Fluoroscopy alone is unable to depict the endocardial surfaces and the anatomic details required for precise localization of the CTI due to its complex and variable anatomy²⁵. Moreover, the electrode tip endocardial contact cannot be accessed directly with fluoroscopy and with the increased fluoroscopy time both the patient and operator are at risk of radiation hazards²⁶. However, use of ICE during ablation increases the success rate, decreases recurrence and the rate of complications many folds²⁵.

METHODOLOGY

This cross sectional study was conducted in the Department of Cardiology, Hayatabad Medical Complex, Peshawar from June 2006 to June 2018, after obtaining ethical approval from the institutional Research and Ethics Board (IREB) of Post Graduate Medical Institute, Peshawar. All patients with typical atrial flutter were included while those with atypical atrial flutter and scar related flutter were excluded.

All those patients who presented to our department with atrial flutter and were hemodynamically stable, were electively planned for radiofrequency ablation. They were anticoagulated with novel anticoagulants for four weeks before the elective procedure. Anticoagulation was stopped 24 hours before the elective procedure. Baseline ECG and transthoracic echocardiography were done. Trans esophageal echocardiography (TEE) was done a day before the procedure to rule out any left atrial or left atrial appendage clots. After confirmation of the typical flutter, the CTI was ablated in left anterolateral oblique (LAO) or right anterolateral oblique (RAO) fluoroscopic position using therapy ablation catheter with 60 degree Celsius temperatures and 40-50 watts power and in case of failure, irrigated cooled tip catheter was used. In some cases three dimensional activation mapping was used. ICE was used in 06 cases to locate cavotricuspid isthmus. Post procedure bidirectional block was documented. Patient was given isoprenaline, and 30 minutes after the procedure; if there was no recurrence of the flutter, then the procedure was stopped. Next day after repeat ECG, patient was sent home on anticoagulation for three weeks and advised follow up after a month. The data were analyzed using SPSS version 23.

RESULTS

Out of the total 1738 patients enrolled for radiofrequency ablations, 48 cases had typical atrial flutter. All the flutter cases with conventional method and on ICE are summarized in Figure 1.

Figure 1: Atrial flutter ablation success using different modalities

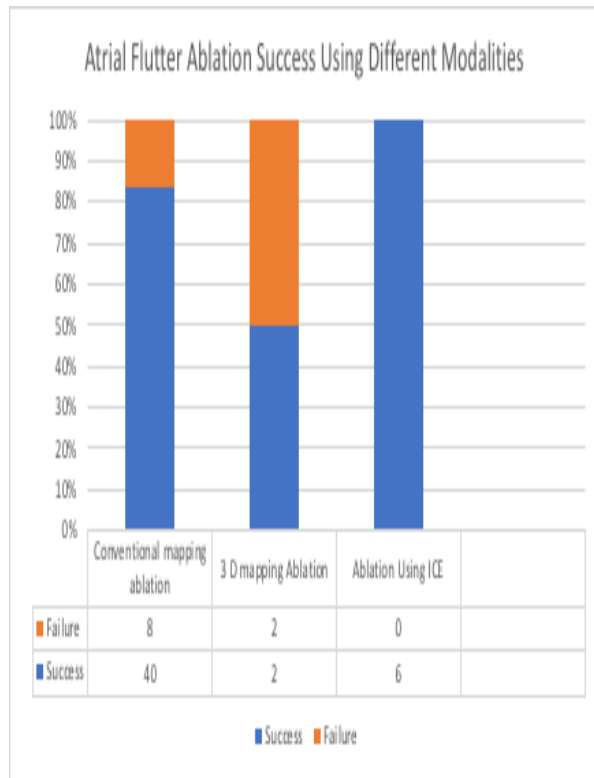


Figure 2: Typical position of ablation catheter at 7 o'clock position

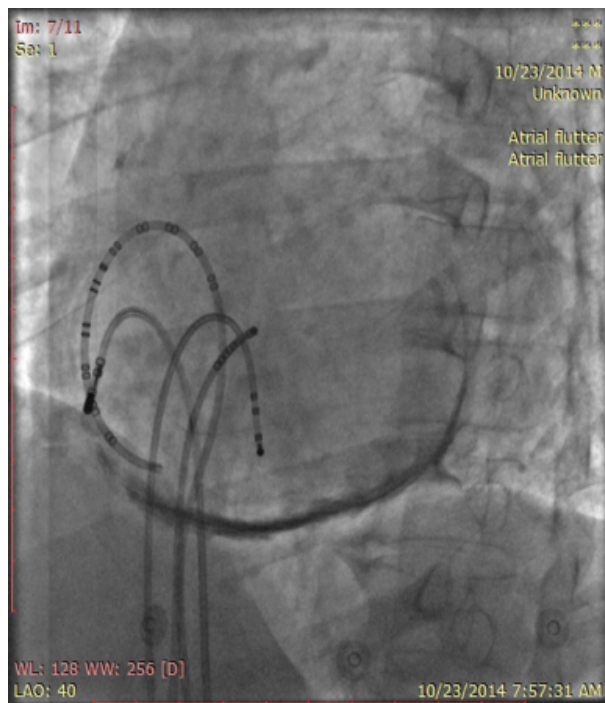


Figure 3: Position adjusted under direct vision at 7 o'clock position with the help of ICE

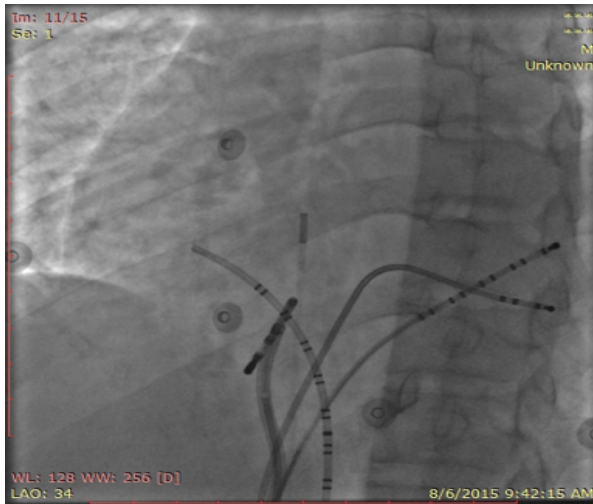


Figure 5: Locating the CTI by curving the catheter under direct vision

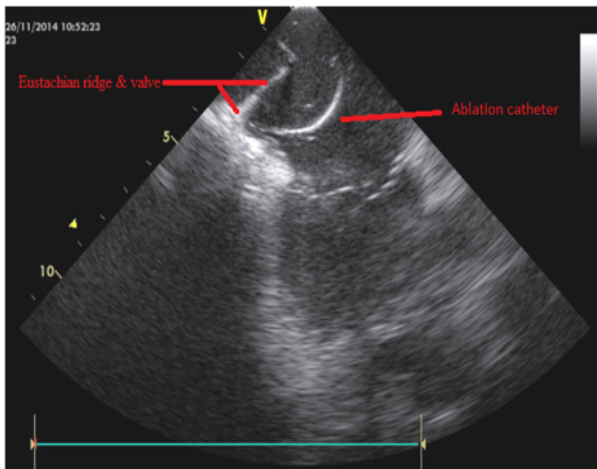
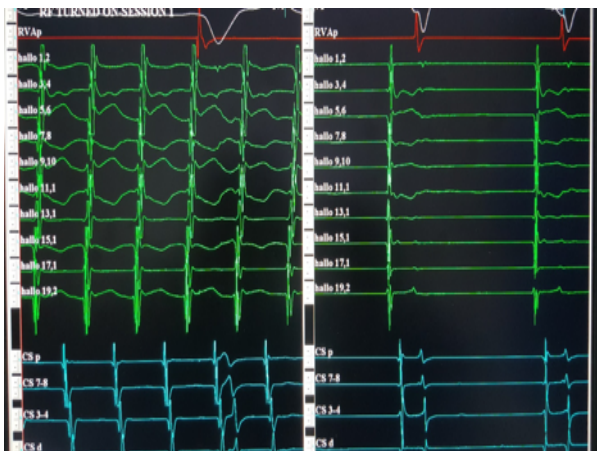

Figure 5: Intra cardiac view of flutter



Age of the patients ranged from 24 to 60 years, with a mean age of 39.77 ± 8.32 years. Male patients were 56%.

Forty patients were successfully ablated without any major or minor complications. We were unable to ablate with conventional methods in 06 cases and then ICE was used with successful ablation in all 06 cases (Figures 2 to 5).

In all patients, at the end of the procedure, bidirectional block was documented. More than 50 % increase in trans-isthmus conduction time was also documented. Average time of procedure was 60 minutes.

DISCUSSION

Though typical atrial flutter ablation has high success rate and despite the fact that its ablation is mostly anatomically assisted with intra cardiac signal, still it is not straight forward²¹⁻²⁵. The site of ablation, CTI^{27,28} which is the narrowest part in the path of electrical circuit, is lying at 5 to 7 o'clock in the LAO position. If ablation is not successful then the catheter is rotated toward the 7 and 5 o'clock position in the LAO view and the same maneuver is repeated again and again till the ablation becomes a success^{29,30}.

Frequently a pouch (Keith's pouch) is found at 6 o'clock position which makes the electrode to endocardium contact difficult³¹. By taking catheter towards the 7 o'clock position in the LAO view, the catheter mostly meets with thicker atrial muscular portion and terminal part of pectinate muscles³². Also at time, the thick muscular ridge of Eustachian valve will not allow the tip of the ablation catheter to reach the CTI and it will hang over the CTI, and will fail to deliver the energy to the ablation site³⁰. Then one has to turn around the catheter on the muscular ridge to reach the CTI. This is not possible using fluoroscopy or even three dimensional activation mapping system. When the catheter is moved toward the 5 o'clock position in the LAO view the chance of AV blocks increases due to the compact AV node³³. This not only increases the rate of complications but also the frequency of recurrence because proper block is not induced at CTI.

Therefore, to minimize the rate of complication and increase the rate of success, different tools are introduced. These include different ablation catheters i.e. 8 mm instead of with 4 mm tip catheter, steerable sheath, cool flow catheters, cryoablation of CTI, biplane right atrial angiography to reveal highly variable CTI anatomy, three-dimensional (3D) navigation system, Remote navigation, real-time 3-dimensional transesophageal echocardiography and Voltage-guided ablation of CTI, transthoracic and transesophageal echocardiography³⁴. Morton et al²⁶ conducted a study which showed the feasibility of typical atrial flutter ablation. They used ICE and the CTI was visualized in its long axis.

In our center, we use halo catheters, sheaths, different tip catheters, cool flow catheters and 3D Navex navigation system. None of these tools are much friendly and all of them have different limitations. Therefore, for the principal operator it becomes mandatory to take care of both fluoroscopy and 3D system. The cost and the time of ablation increases many times. The last but not the least, the coordination with the second operator on the system and his personal experience and guidance to the principal operator matters a lot.

On contrary to all these, we found ICE very much friendly both to the operator and patient. It does not need special expertise. The catheter can be curved to turn it around the ridge for proper contact, and reduce the time of procedure and the numbers of burns, fluoroscopy time is reduced many folds and the effective bidirectional block is achieved very well. The reproducibility for locating the area of interest is excellent with ICE.

CONCLUSION

The ICE-guided ablation of CTI permitted high success rate and low recurrence rate. ICE guided ablation of CTI reduced procedure time, fluoroscopy time, radiation exposure, RFA time and ensured the delivery of effective radiofrequency energy. ICE can be used as a tool for the visualization of area of interest and can be used for conventional ablations.

REFERENCES

- Granada J1, Uribe W, Chyou PH, Maassen K, Vierkant R, Smith PN, Hayes J, Eaker E, Vidaillet H. Incidence and predictors of atrial flutter in the general population. *J Am Coll Cardiol.* 2000;36:2242-6.
- Bun SS1, Latcu DG2, Marchlinski F3, Saoudi N4. Atrial flutter: more than just one of a kind. *Eur Heart J.* 2015; 36:2356-63
- Rubín JM, Calvo D, Pérez D, Fidalgo A, de la Hera JM, Martínez L, Capín E, Arrizabalaga H, Carballeira L, García D, Morís C. Characterization of a stepwise approach in cavotricuspid isthmus ablation for typical atrial flutter: A randomized study comparing three catheters. *Pacing and Clinical Electrophysiology.* 2017;40:1052-8.
- Cosío FG1 Atrial Flutter, Typical and Atypical: A Review. *Arrhythm Electrophysiol Rev.* 2017;6:55-62
- Mendenhall GS, Voigt A, Saba S. Insights into atrioventricular nodal function from patients displaying dual conduction properties: interactive and orthogonal pathways. *Circ Arrhythm Electrophysiol.* 2013; 6:364-70.
- Huang JJ, Reddy S, Truong TH, Suryanarayana P, Alpert JS. Atrial appendage thrombosis risk is lower for atrial flutter compared with atrial fibrillation. *The American journal of medicine.* 2018;131:442-e13.
- Sundbøll J, Hováth-Puhó E, Adelborg K, Ording A, Schmidt M, Bøtker HE, Sørensen HT. Risk of arterial and venous thromboembolism in patients with atrial fibrillation or flutter: a nationwide population-based cohort study. *International journal of cardiology.* 2017;241:182-7..
- Rosés i Noguer F, Albert Brotons DC, Ferrer Menduïña Q, Gran Ipiña F, Escobar Díaz MC, Moya Mitjans A. Dilated cardiomyopathy secondary to atrial ectopic tachycardia. *An Pediatr (Barc).* 2006; 65:263-5
- Dhar S, Lidhoo P, Koul D, Bakhshi M, Deger FT. Current concepts and management strategies in atrial flutter. *Southern medical journal.* 2009;102:917-22.
- Peters RW, Weiss DN, Carliner NH, Feliciano Z, Shorofsky SR, Gold MR. Overdrive pacing for atrial flutter. *The American journal of cardiology.* 1994;74:1021-3.
- Zimetbaum P. Antiarrhythmic drug therapy for atrial fibrillation. *Circulation.* 2012;125:381-9..
- Page, R.L., Joglar, J.A., Caldwell, M.A., Calkins, H., Conti, J.B., Deal, B.J., Estes, N.M., Field, M.E., Goldberger, Z.D., Hammill, S.C. and Indik, J.H., 2016. 2015 ACC/AHA/HRS guideline for the management of adult patients with supraventricular tachycardia: a report of the American College of Cardiology/American Heart Association Task Force on Clinical Practice Guidelines and the Heart Rhythm Society. *Journal of the American College of Cardiology,* 67, pp.e27-e115..
- Pozen RG, Pastoriza J, Rozanski JJ, Kessler KM, Myerburg RJ. Determinants of recurrent atrial flutter after cardioversion. *Br Heart J.* 1983;50:92-6.
- Gössinger HD1, Siostrzonek P, Jung M, Wagner L, Mösslacher H. Electrophysiologic determinants of recurrent atrial flutter after successful termination by overdrive pacing. *Am J Cardiol.* 1990;65:463-6.
- Podrid PJ. Proarrhythmia, a serious complication of antiarrhythmic drugs. *Curr Cardiol Rep.* 1999;:289-96.
- Podrid PJ1 Safety and toxicity of antiarrhythmic drug therapy: benefit versus risk. *J Cardiovasc Pharmacol.* 1991;17 :65-73
- Dan M. Roden Risks and Benefits of Antiarrhythmic Therapy. *N Engl J Med* 1994; 331:785-791
- Hylek EM1 Complications of oral anticoagulant therapy: bleeding and nonbleeding, rates and risk factors *Semin Vasc Med.* 2003;3:271-8.
- Stirratt MJ, Curtis JR, Danila MI, Hansen R, Miller MJ, Gakumo CA. Advancing the science and practice of medication adherence. *Journal of general internal medicine.* 2018;33:216-22..
- Sado E, Sufa A. Availability and affordability of essential medicines for children in the Western part of Ethiopia: implication for access. *BMC Pediatr.* 2016;16:40.
- Jung Y1, Kwon S2. The Effects of Intellectual Property Rights on Access to Medicines and Catastrophic Expenditure. *Int J Health Serv.* 2015;45:507-29
- Natale A, Newby KH, Pisano E, et al. Prospective randomized comparison of antiarrhythmic therapy versus first-

- line radiofrequency ablation in patients with atrial flutter. *J Am Coll Cardiol.* 2000;35: 1898–1904.
23. Willems S, Weiss C, Ventura R, et al. Catheter ablation of atrial flutter guided by electroanatomic mapping (CARTO): a randomized comparison to the conventional approach. *J Cardiovasc Electrophysiol.* 2000;11:1223–30.
 24. Kottkamp H, Hugel B, Krauss B, et al. Electromagnetic versus fluoroscopic mapping of the inferior isthmus for ablation of typical atrial flutter: a prospective randomized study. *Circulation.* 2000;102: 2082–6.
 25. Nakagawa H, Shah N, Matsudaira K, et al. Characterization of re-entrant circuit in macrore-entrant right atrial tachycardia after surgical repair of congenital heart disease: isolated channels between scars allow “focal” ablation. *Circulation.* 2001;103:699–709.
 26. Morton JB, Sanders P, Davidson NC, Sparks PB, Vohra JK, Kalman JM. Phased-array intracardiac echocardiography for defining cavotricuspid isthmus anatomy during radiofrequency ablation of typical atrial flutter. *J Cardiovasc Electrophysiol.* 2003; 14: 591-7.
 27. Cabrera JA, Sanchez-Quintana D, Ho SY, Medina A, Anderson RH. The architecture of the atrial musculature between the orifice of the inferior caval vein and the tricuspid valve: the anatomy of the isthmus. *J Cardiovasc Electrophysiol.* 1998; 9: 1186-95.
 28. Kalman JM1, Olgin JE, Saxon LA, Fisher WG, Lee RJ, Lesh MD. Activation and entrainment mapping defines the tricuspid annulus as the anterior barrier in typical atrial flutter. *Circulation.* 1996 ;94:398-406
 29. Cosio FG, Lopez-Gil M, Goicolea A, et al. Radiofrequency ablation of the inferior vena cava-tricuspid valve isthmus in common atrial flutter. *The American Journal of Cardiology.* 1993;71:705–9.
 30. Chen J1, de Chillou C, Basiouny T, Sadoul N, Filho JD, Magnin-Poull I, Messier M, Aliot E. Cavotricuspid isthmus mapping to assess bidirectional block during common atrial flutter radiofrequency ablation. *Circulation.* 1999 ;100:2507-13.
 31. Klimek-Piotrowska W, Hołda MK, Koziej M, Hołda J, Piątek K, Tyrak K, Bolechała F. clinical anatomy of the cavotricuspid isthmus and terminal crest. *PLoS One.* 2016;11:e0163383
 32. Gami AS1, Edwards WD, Lachman N, Friedman PA, Talreja D, Munger TM, Hammill SC, Packer DL, Asirvatham SJ. Electrophysiological anatomy of typical atrial flutter: the posterior boundary and causes for difficulty with ablation. *J Cardiovasc Electrophysiol.* 2010;21:144-9.
 33. Asirvatham SJ Correlative anatomy and electrophysiology for the interventional electrophysiologist: right atrial flutter. *J Cardiovasc Electrophysiol.* 2009 Jan; 20:113-22
 34. Spector P1, Reynolds MR, Calkins H, Sondhi M, Xu Y, Martin A, Williams CJ, Sledge I. Meta-analysis of ablation of atrial flutter and supraventricular tachycardia. *Am J Cardiol.* 2009; 104:671-7.
 35. Gábor Bencsik Novel Strategies in the Ablation of Typical Atrial Flutter: Role of Intracardiac Echocardiography. *Curr Cardiol Rev.* 2015; 11: 127–33.

CONTRIBUTORS

IK conceived the idea and drafted the manuscript. IK and BS collected the data, did statistical analysis and interpretation of the data. BS did critical revision of the article. ZAA supervised the study and carried out final proofreading. All authors contributed significantly to the submitted manuscript.