

# MEASUREMENT OF CHANGES IN CHOROIDAL THICKNESS BY OPTICAL COHERENCE TOMOGRAPHY OF DIABETIC PATIENTS AFTER PAN-RETINAL PHOTOCOAGULATION

Imran Ahmad<sup>1</sup>, Mubashir Rehman<sup>2</sup>, Muhammad Tariq Khan<sup>3</sup>,  
Mohammad Zeeshan Tahir<sup>4</sup>, Jahanzaib Khan<sup>5</sup>

<sup>1,4,5</sup> Department of Ophthalmology, Gajju Khan Medical College, Bacha Khan Medical Complex, Swabi - Pakistan.

<sup>2</sup> Department of Ophthalmology, Nowshera Medical College, Qazi Hussain Ahmad Medical Complex, Nowshera - Pakistan.

<sup>3</sup> Department of Ophthalmology, Hayatabad Medical Complex, Peshawar - Pakistan.

**Address for correspondence:**  
**Dr. Mubashir Rehman**

Associate Professor,  
Department of Ophthalmology,  
Nowshera Medical College,  
Qazi Hussain Ahmad Medical Complex,  
Nowshera - Pakistan.

Email: drmubashirrehman78@gmail.com

Date Received:

May 29, 2019

Date Revised:

October 25, 2019

Date Accepted:

November 02, 2019

## ABSTRACT

**Objective:** To find out changes in choroidal thickness by optical coherence tomography (OCT) of diabetic patients after pan-retinal photocoagulation (PRP).

**Methodology:** This case series study was conducted at Hayatabad Medical Complex, Peshawar and Bacha Khan Medical Complex, Swabi from January 2015 to February 2018. One hundred patients with diabetic retinopathy (DR) undergoing PRP were selected by consecutive sampling. All patients underwent enhanced depth images of spectral domain OCT for choroidal thickness at baseline before PRP. After PRP, all patients were followed up after 4 and 12 weeks with repeated OCT to check for choroidal thickness.

**Results:** A total of 146 eyes of 100 patients were included in the study. The mean age was  $58.35 \pm 4.89$ . Mean baseline choroidal thickness on OCT for central 1mm zone was  $312.92 \pm 23.73\mu$ , for intermediate 3 mm it was  $321.22 \pm 18.88\mu$  while for outer 6 mm zone it was  $329.11 \pm 27.22\mu$ . After four weeks of PRP, mean choroidal thickness on OCT for central 1mm zone was  $331.67 \pm 15.22\mu$ , for intermediate 3 mm was  $344.21 \pm 19.33\mu$  while for outer 6 mm it was  $349.99 \pm 21.56\mu$ . At 12 weeks, mean OCT for central 1mm was  $281.1 \pm 17.11\mu$ , for intermediate 3 mm was  $276.21 \pm 19.21\mu$  while for outer 6 mm it was  $269.49 \pm 21.34\mu$ .

**Conclusion:** There was transient increase in choroidal thickness after PRP. However, after 12 weeks there was gradual decline in choroidal thickness which was more than the initial pre-treated state.

**Key Words:** Pan-retinal photocoagulation, Choroidal thickness, Optical coherence tomography

This article may be cited as: Ahmad I, Rehman M, Khan MT, Tahir MZ, Khan J. Measurement of changes in choroidal thickness by optical coherence tomography of diabetic patients after pan-retinal photocoagulation. *J Postgrad Med Inst* 2019; 33(3): 242-6.

## INTRODUCTION

The alarming rise in prevalence of diabetes is a worldwide public health problem<sup>1</sup>. According to world health organization (WHO) 2011 report, 12.9 million people are diabetic and this figure is expected to reach to 14 million by the year 2030 in Pakistan<sup>2</sup>. The main reason of visual loss in diabetic patients is proliferative diabetic retinopathy (PDR) and diabetic macular edema<sup>3</sup>. Globally approximately 17 million and 21 million are suffering from PDR and diabetic macular edema respectively<sup>4</sup>. Pan-retinal photocoagulation (PRP) is a well-established treatment for proliferative diabetic retinopathy and timely intervention can reduce visual loss by more than 50% as proven by diabetic retinopathy

study (DRS) and early treatment diabetic retinopathy study (ETDRS)<sup>5</sup>.

The choroid is one of the most richly blood supplied tissues of the body and is responsible for nourishing the outer retinal layers. Disturbance in the blood supply or anatomical changes in the choroid may also affect the retinal structure and function<sup>6</sup>. Pan retinal photocoagulation is assumed to be associated with reduction in blood supply to choroid leading to choroidal thinning in patients with diabetic retinopathy. With the invention of enhanced depth imaging in the form of OCT, we can find the different changes that can occur in the choroid with various diseases like DR, central serous chorio-retinopathy or age related macular degeneration<sup>6-8</sup>. Various

studies have shown that blood flow to the choroid is reduced after PRP in patients with diabetic retinopathy and diabetic macular edema<sup>9</sup>. The aim of this study was to determine the changes in choroidal thickness by OCT in sub-macular region after PRP. Studies have been carried out showing the relationship of various diseases with choroidal thickness but so far no data has been published showing the relationship of choroidal thickness in diabetic patients after PRP using OCT.

## METHODOLOGY

This case series was conducted at Hayatabad Medical Complex, Peshawar and Bacha Khan Medical Complex, Swabi from January 2015 to February 2018. Hundred patients were selected by consecutive sampling with diabetic retinopathy undergoing PRP. All patients with proliferative diabetic retinopathy (PDR) needing PRP according to the Early Treatment of Diabetic Retinopathy Study (ETDRS) were enrolled. Written informed consent was obtained from all the patients. Patients were excluded if they had undergone PRP with other vascular diseases along with diabetic retinopathy, media opacities like cataracts and vitreous hemorrhage, central serous chorioretinopathy, glaucoma, intraocular surgery, trauma or uveitis, history of intra vitreal injections and high Myopia.

Detailed ocular examination was done including visual acuity, best corrected visual acuity (BCVA), anterior segment examination including pupillary examination and dilated fundus examination. The pupils were dilated using 1% tropicamide eye drops and 2.5% phenylephrine eye drops. After enrolment in the study, all the patients underwent enhanced depth images of spectral domain OCT for choroidal thickness at baseline before pan retinal photocoagulation (Figure 1). The zero delay line was placed at the level of choroid while the automatic reference line was plotted at the junction of retinal pigment epithelium (RPE) and Burch's membrane; and the choroid and scleral junction, to exactly measure the choroidal thickness.

All patients underwent pan-retinal photocoagulation using vitra Argon laser photocoagulator. The eyes were anaesthetized by using 0.5% proparacaine eye drops. Mainster lens was used for the procedure with a coupling fluid. In one session, 1000 to 1500 burns were applied as per ETDRS protocol. Laser setting was made to produce effective burns of retina using a spot size of 200 to 300 microns, with duration of 200 to 300 milliseconds and energy range of 120 mJ to 450mJ.

Post PRP, all patients were followed after 4 and 12 weeks with repeated OCT to check for choroidal thickness. Data were entered and analyzed with SPSS version 20. Descriptive statistics were recorded in terms of percentages and frequencies for categorical data and means and standard deviation for numerical data respectively.

## RESULTS

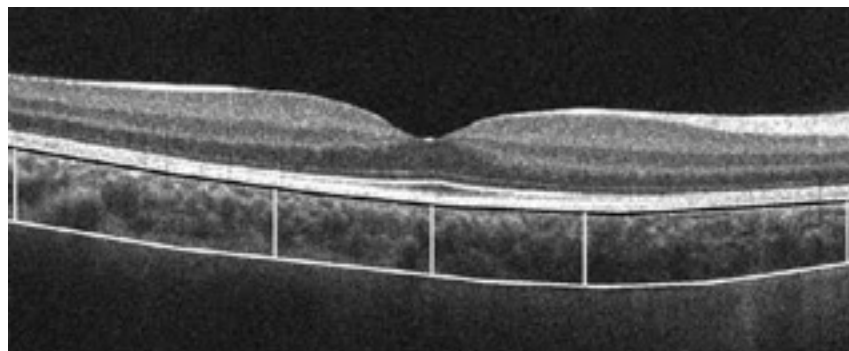
A total of 146 eyes of 100 patients were included. There were 56 males and 44 females in the study. Mean age was  $58.35 \pm 4.89$  years. Age distribution is shown in Table 1.

Baseline choroidal thickness on OCT is shown in Table 2. Mean baseline OCT for central 1 mm was  $312.92 \pm 23.73\mu$ . Mean baseline OCT for intermediate 3 mm was  $321.22 \pm 18.88\mu$  while mean baseline OCT for outer 6 mm was  $329.11 \pm 27.22\mu$ .

Four weeks after PRP there was a transient increase in choroidal thickness as evident in Table 3. After four weeks of PRP, mean OCT for central 1mm was  $331.67 \pm 15.22\mu$ ; for intermediate 3 mm was  $344.21 \pm 19.33\mu$ ; and for outer 6 mm was  $349.99 \pm 21.56\mu$ .

This transient increase in OCT was reduced and there was overall decrease in choroidal thickness after 12 months of PRP as is shown in Table 4. At 12 weeks mean OCT for central 1mm was  $281.11 \pm 17.11\mu$ ; mean OCT for intermediate 3 mm was  $276.21 \pm 19.21\mu$ ; while mean OCT for outer 6 mm was  $269.49 \pm 21.34\mu$ .

**Figure 1: Enhanced depth image of spectral domain OCT**



**Table 1: Age-wise distribution of patients (n=100)**

Age Range (Years)	Frequency	Percentage
41-50 Years	22	22.00 %
51-60 Years	39	39.00 %
61-70 Years	28	28.00 %
71-80 Years	11	11.00 %
Total	100	100 %

**Table 2: Choroidal thickness at base line OCT (n=146 eyes)**

Choroidal Thickness	Central 1 mm	Percentage	Intermediate 3 mm	Percentage	Outer 6 mm	Percentage
250 – 270 $\mu$	11	7.53 %	9	6.16 %	5	3.42 %
270 – 290 $\mu$	15	10.28 %	17	11.64 %	3	2.05 %
290 – 310 $\mu$	43	29.46 %	33	22.61%	48	32.88 %
310 – 330 $\mu$	39	26.71 %	44	30.14 %	34	23.29%
330 – 350 $\mu$	38	26.02 %	43	29.45 %	56	38.36 %
Total	146	100 %	146	100 %	146	100 %

**Table 3: Choroidal thickness 4 weeks after PRP (n=146 eyes)**

Choroidal Thickness	Central 1 mm	Percentage	Intermediate 3 mm	Percentage	Outer 6 mm	Percentage
250 – 270 $\mu$	8	5.48 %	5	3.42 %	3	2.05 %
270 – 290 $\mu$	9	6.16 %	8	5.48 %	7	4.79%
290 – 310 $\mu$	37	25.34 %	29	19.86 %	29	19.86 %
310 – 330 $\mu$	36	24.66 %	37	25.35 %	49	33.57%
330 – 350 $\mu$	56	38.36 %	67	45.89 %	58	39.73 %
Total	146	100 %	146	100 %	146	100 %

**Table 4: Choroidal thickness 12 weeks after PRP (n= 146 eyes)**

Choroidal Thickness	Central 1 mm	Percentage	Intermediate 3 mm	Percentage	Outer 6 mm	Percentage
250 – 270 $\mu$	55	37.67 %	48	32.87 %	37	25.34 %
270 – 290 $\mu$	41	28.08 %	56	38.36 %	63	43.15 %
290 – 310 $\mu$	29	19.86 %	21	14.38 %	19	13.01 %
310 – 330 $\mu$	11	7.54 %	5	3.43 %	11	7.54 %
330 – 350 $\mu$	10	6.85 %	16	10.96 %	16	10.96 %
Total	146	100 %	146	100 %	146	100 %

## DISCUSSION

In our study, we observed the sub-macular choroidal thickness in patients with proliferative diabetic retinopathy without significant macular edema after PRP. It was observed that there was transient increase in choroidal thickness after PRP which was in line with the study by Cho et al<sup>10</sup>. They measured choroidal thickness one week after PRP and proposed that after PRP the blood flow is shifted from the peripheral retina to the central retina and choroid. Similarly, another study by Lee et al<sup>11</sup> reported that there was a transient change in choroidal thickness after PRP but the thickness decreases significantly after 3 months of PRP. The exact mechanism for the transient increase in choroidal thickness was not known but the suggested mechanisms mentioned in previous studies was vasodilatation of choroidal vessels after PRP due to obstruction of blood flow by lasers as shown by choroidal Doppler flowmetry technique in patients with diabetic retinopathy. Another possible explanation is that after PRP there is inflammation in the untreated choroidal tissues leading to increase production of nitric oxide resulting in vasodilation in this region<sup>12</sup>. There is increased production of leukocytes after PRP which increases the vascular permeability in choroid and is responsible for the transient increase in its thickness<sup>13,14</sup>.

In the present study, we found that there was a decrease in choroidal thickness 12 weeks after PRP in patients with diabetic retinopathy. The decline in thickness was more than the initial pre-treated state. One reason for this decrease in thickness might be the thermal damage caused by PRP which dissipates to the surrounding tissues resulting in failure to perfuse when the inflammation subsides. Another reason was that after PRP there was destruction of RPE resulting in decrease in vascular endothelial growth factors (VEGF) responsible for normal vascular functions in humans which is in

accordance with another study by Maharaj et al<sup>13</sup>. With decrease production of VEGF, there was decrease in the permeability of sub-macular choroidal vessels leading to reduced thickness in this region<sup>15</sup>. In another study conducted by Kim et al<sup>16</sup>, it was showed that the choroidal thickness increases according to the severity of diabetic retinopathy (from mild to moderate or severe non-proliferative diabetic retinopathy or proliferative diabetic retinopathy) but the thickness reduces significantly if the patients are treated with PRP.

## CONCLUSION

There was transient increase in choroidal thickness after PRP. However, after 12 weeks there was gradual decline in choroidal thickness which was more than the initial pre-treated state. Pan-retinal photocoagulation (PRP) is associated with decrease in choroidal blood flow leading to decrease in choroidal thickness. So PRP is not a risk free procedure and should be done as gentle as possible only in proliferative stage of diabetic retinopathy.

## REFERENCES

1. Sivaprasad S, Gupta B, Crosby-Nwaobi R, Evans J. Prevalence of diabetic retinopathy in various ethnic groups: A worldwide perspective. *Surv Ophthalmol* 2012; 57:347-70.
2. Bahadar H, Mostafalou S, Abdollahi M. Growing burden of diabetes in Pakistan and the possible role of arsenic and pesticides. *J Diabetes Metab Disord* 2014; 13:117.
3. Lains I, Figueira J, Santos AR, Baltar A, Costa M, Nunes S et al. Choroidal thickness in diabetic retinopathy: The influence of antiangiogenic therapy. *Retina* 2014; 34:1199-207.
4. Yau JW, Rogers SL, Kawasaki R, Lamoureux EL, Kowalski JW, Bek T et al. Global prevalence and major risk factors of diabetic retinopathy. *Diabetes Care* 2012; 35:556-64.

5. Relhan N, Flynn HW Jr. The early treatment diabetic retinopathy study: Historical review and relevance to today's management of diabetic macular edema. *Curr Opin Ophthalmol* 2017; 28:205-12.
6. Sudhalkar A, Chhablani JK, Venkata A, Raman R, Rao PS, Jonnadula GB. Choroidal thickness in diabetic patients of Indian ethnicity. *Indian J Ophthalmol* 2015; 63:912-16.
7. Rahman W, Chen FK, Yeoh J, Patel P, Tufail A, Da Cruz L. Repeatability of manual subfoveal choroidal thickness measurements in healthy subjects using the technique of enhanced depth imaging optical coherence tomography. *Invest Ophthalmol Vis Sci* 2011; 52:2267-71.
8. Margolis R, Spaide RF. A pilot study of enhanced depth imaging optical coherence tomography of the choroid in normal eyes. *Am J Ophthalmol* 2009; 147:811-5.
9. Nagaoka T, Kitaya N, Sugawara R, Yokota H, Mori F, Hikiuchi T et al. Alteration of choroidal circulation in the foveal region in patients with type 2 diabetes. *Br J Ophthalmol* 2004; 88:1060-3.
10. Cho GE, Cho HY, Kim YT. Change in subfoveal choroidal thickness after argon laser pan-retinal photocoagulation. *Int J Ophthalmol* 2013; 6:505-9.
11. Lee SH, Kim J, Chung H, Kim HC. Changes of choroidal thickness after treatment for diabetic retinopathy. *Curr Eye Res* 2014; 39:736-44.
12. Nonaka A, Kiryu J, Tsujikawa A, Yamashiro K, Nishijima K, Kamizuru H et al. Inflammatory response after scatter laser photocoagulation in non-photocoagulated retina. *Invest Ophthalmol Vis Sci* 2002; 43:1204-9.
13. Maharaj AS, D'Amore PA. Roles for VEGF in the adult. *Microvasc Res* 2007; 74:100-13.
14. Brucker AJ, Qin H, Antoszyk AN, Beck RW, Bressler NM, Browning DJ et al. Observational study of the development of diabetic macular edema following pan-retinal (scatter) photocoagulation given in 1 or 4 sittings. *Arch Ophthalmol* 2009; 127:132-40.
15. Yiu G, Manjunath V, Chiu SJ, Farsiu S, Mahmoud TH. Effect of anti-vascular endothelial growth factor therapy on choroidal thickness in diabetic macular edema. *Am J Ophthalmol* 2014; 158:745-51.
16. Kim JT, Lee DH, Joe SG, Kim JG, Yoon YH. Changes in choroidal thickness in relation to the severity of retinopathy and macular edema in type 2 diabetic patients. *Invest Ophthalmol Vis Sci* 2013; 54:3378-84.

### CONTRIBUTORS

IA conceived the idea, planned the study, wrote protocol and manuscript of the study. MR critically appraised the manuscript and helped collecting and analyzing the data. MTK appraised and approved the initial manuscript, supervised the data and carried out editing. MZT and JK carried out literature search after reading the proposal, helped in collection of data and correction of references. All authors contributed significantly to the submitted manuscript.