

EOSINOPHILIC ASCITES WITH MARKED PERIPHERAL EOSINOPHILIA IN A MIDDLE AGED FEMALE

Nabeela Iqbal¹, Syed Khalid Shah², Shamima Hanif³

¹⁻³ Department of Medicine,
Sandeman Provincial Hospital,
Quetta - Pakistan.

Address for correspondence:

Dr. Nabeela Iqbal

05/04/79A, Madrissa Road Quetta
Cantt., Balouchistan - Pakistan.

Email: nabeela.khan50@yahoo.
com

Date Received: July 01, 2019

Date Revised: September 26, 2019

Date Accepted:

September 31, 2019

ABSTRACT

Eosinophilic disease of gastrointestinal tract is an uncommon condition characterized by non-specific gastrointestinal symptoms in association with peripheral eosinophilia. Depending upon the predominantly involved layer, three types (mucosal, muscular and sub serosal) are described. The later being the most uncommon variant characterized by eosinophilic ascites and peripheral eosinophilia. Endoscopic biopsy is usually non-diagnostic due to uninvolved GI mucosa, thus peripheral hyper-eosinophilia and ascitic fluid rich in eosinophils are the mainstay for the diagnosis. We report a 40 years old female who presented with abdominal distention for 3 weeks. Ascitic fluid analysis showed an exudative picture with raised protein and moderate cellularity with 65% eosinophils. Endoscopic biopsy showed nonspecific chronic inflammatory changes with no evidence of eosinophilic infiltration.

Key Words: Ascites, Eosinophilia, Endoscopic biopsy

This case report may be cited as; Iqbal N, Shah SK, Hanif S. Eosinophilic ascites with marked peripheral eosinophilia in a middle aged female. *J Postgrad Med Inst* 2019; 33(3): 263-5.

INTRODUCTION

Eosinophilic gastroenteritis (EGE) is a rare disorder of GI tract characterized by recurrent eosinophilic infiltration of parts of GIT¹. It presents with vague GI symptoms and presence of peripheral eosinophilia^{2,3}. The clinical manifestations of EGE depends upon the location, extent and depth of infiltration of GI wall. Eosinophilic ascites is an atypical presentation of EGE which is mostly associated with subserosal variant and is least common⁴. The subserosal type of EGE is frequently missed on upper GI endoscopic biopsy rendering the diagnosis of the disease a challenge to the clinician. The etiology of EGE is unknown, although the response to corticosteroids is excellent.

CASE PRESENTATION

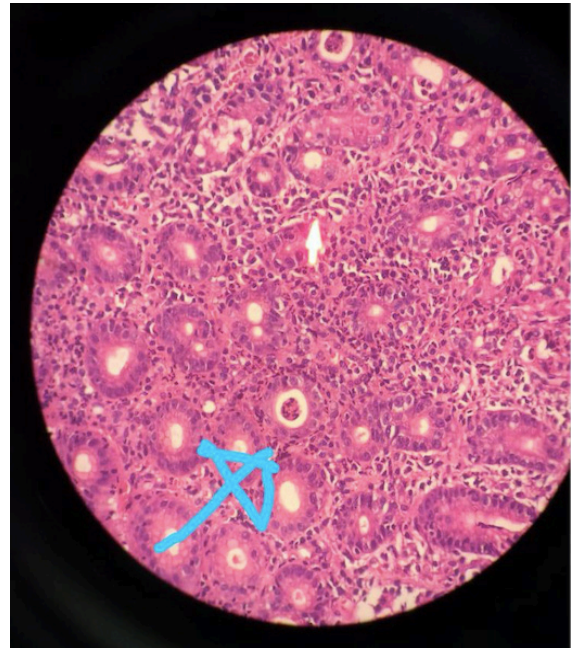
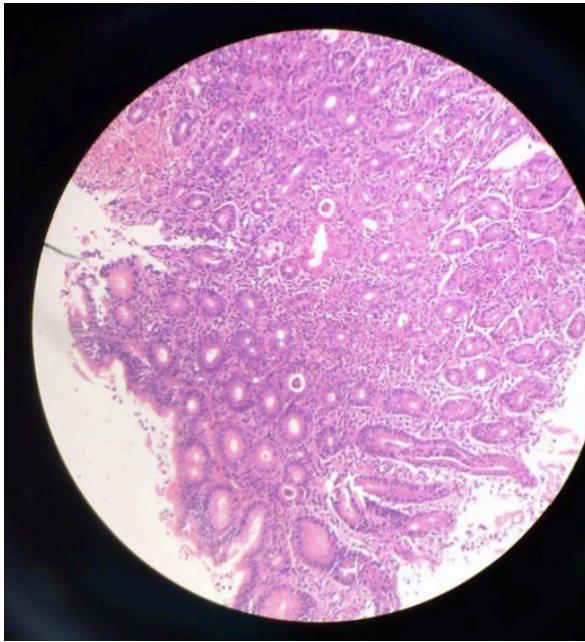
A 40 years old female presented with abdominal distention and postprandial abdominal fullness for 3 weeks. There was no history of pain, vomiting or fever. There was no history of worm infestation and she had no history of jaundice as well. She was a non-smoker and had no significant family or medical history. On examination she had gross ascites and was edematous. Peripheral stigmata of chronic liver disease were not found. Investigations revealed marked eosinophilic leukocytosis with 30% eosinophils (total leucocyte count 15100/cmm and no immature myeloid precursors). Routine biochemical tests were normal. Abdominal ultrasound demonstrated moderate ascites with no evidence of hepatosplenomegaly, intra-abdominal lymph-

adenopathy or signs of portal hypertension. Ascitic fluid analysis showed an exudative picture with raised protein, low SAAG and moderate cellularity with 65% eosinophils, with no evidence of malignant cells or AFB. Endoscopy showed moderate erythema of gastric antrum with an unremarkable duodenum. Histopathology revealed chronic nonspecific inflammatory changes with numerous neutrophils scattered in the mucosa. Thus diagnosis of eosinophilic ascites due to eosinophilic gastroenteritis was made. The patient was put on oral prednisolone 30 mg per day for 10 days followed by slow tapering for 3 weeks. The patient gave a dramatic response to corticosteroids treatment evidenced by resolution of ascites and labs.

DISCUSSION

Eosinophilic gastroenteritis is an uncommon condition. The etiology remains unknown but family history of atopy has been demonstrated in 50% of cases with EGE⁵. It presents with non-specific symptoms, usually overlapping with other GI disorders. Mucosal subtype presents with altered bowel habits, nausea and vomiting. Intestinal obstruction is common presenting feature of intra mural type due to thickened and rigid gut, whereas sub serosal type presents with gross ascites. The latter sub-group is clinically distinct in having peripheral eosinophilia and dramatic response to corticosteroids^{6,7}. The diagnostic criteria for EGE, as defined by Talley et al⁵, consist of the following: 1) presence of GI symptoms; 2) eosinophilic infiltration of GI tract on histo-pathologic examination or typical radiological

Figure 1: Histopathology showing chronic nonspecific inflammatory changes with numerous neutrophils scattered in the mucosa



features and presence of ascites rich in eosinophils or peripheral eosinophilia; and 3) no evidence of extra intestinal or parasitic disease.

The sub serosal type of EGE is primarily diagnosed on the basis of peripheral hyper-eosinophilia in combination with ascites rich in eosinophils. EGE has an overall good prognosis with dramatic response to corticosteroids treatment⁸. Prednisolone is found to have excellent efficacy within 14 days of treatment initiation regarding symptoms resolution as well as normalization of eosinophil counts when administered in 20-40 mg per day⁹.

The clinical course of the disease might show relapses after the cessation of steroid therapy. Anti-histamines, leukotriene antagonists, mast cell stabilizers and anti-interleukin drugs act as steroid sparing agents and hence prevent the unwanted or adverse effects of steroids. Rarely, patients may fail to show a response to steroids, therefore, total parental nutrition and immunosuppressive agents like azathioprine and cyclophosphamide may be added to the therapy¹⁰.

CONCLUSION

Eosinophilic disease of gastrointestinal tract is uncommon. High index of suspicion is needed in patients with peripheral hyper-eosinophilia and presence of eosinophils rich ascitic fluid to diagnose EGE as it is a treatable entity with dramatic response to corticosteroids.

REFERENCES

1. Agostino A, Parenzi A. Eosinophilic gastroenteritis. A case with predominant involvement of mucosal and muscular layers. *Minerva Med* 1994; 85:655-8.
2. Klein NC, Hargrove RL, Slesinger MH, Jeffries GH. Eosinophilic gastroenteritis. *Medicine* 1970; 49:299-319.
3. Lee M, Hodges WG, Huggins TL, Lee EL. Eosinophilic gastroenteritis. *South Med J* 1996; 89:189-94.
4. Durieu I, Nove-Josserand R, Cathebras P, Vital Durand D, Rousset H, Levrat R. Eosinophilic ascites: Report of two cases. *Rev Med Interne* 1992; 13:446-8.
5. Talley NJ, Shorter RG, Phillips SF, Zinsmeister AR. Eosinophilic gastroenteritis: A clinicopathological study of patients with disease of the mucosa, muscle layer and sub-serosal tissues. *Gut* 1990; 31:54-8.
6. Rothenberg ME. Eosinophilic gastrointestinal disorders (EGID). *J Allergy Clin Immunol* 2004; 113:11-28.
7. Wachter B, Jager-Arand E, Engers, Meyer Zum Buschenfelde KH, Manns M. Eosinophilic gastroenteritis with serosa involvement: A rare differential diagnosis of ascites. *Z Gastroenterol* 1992; 30:469-72.
8. Antonini F, Saltarelli P, Frieri G, Latella G. Education and imaging: gastrointestinal: Eosinophilic ascites. *J Gastroenterol Hepatol* 2012; 27:1759.

9. Zhang L, Duan L, Ding S, Lu J, Jin Z, Cui R et al. Eosinophilic gastroenteritis: Clinical manifestations and morphological characteristics-a retrospective study of 42 patients. *Scand J Gastroenterol* 2011; 46: 1074-80.
10. Triantafyllidis JK, Parasi A, Cherakakis P, Sklavaina M. Eosinophilic gastroenteritis: Current aspects on etiology, pathogenesis, diagnosis and treatment. *Ann Gastroenterol* 2007; 15:106-15.