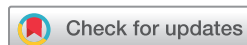



OPEN ACCESS



COMMON LOCATIONS OF TRAUMATIC ULCERATION IN TISSUES UNDERNEATH NEW CONVENTIONAL COMPLETE DENTURES

Ehtesham Khan, Asifullah Khan✉, Akbar Khalil, Mohsin Khan, Sheema Shakir

Department of Prosthodontics, Khyber College of Dentistry, Peshawar – Pakistan.

Address for correspondence:
Asifullah Khan

Department of Prosthodontics, Khyber College of Dentistry, Peshawar – Pakistan.

E-mail:
drasifullah@hotmail.com

Date Received:
June 28, 2020

Date Revised:
March 10, 2021

Date Accepted:
March 11, 2021

This article may be cited as

Kamadajaja MJK, Augustono B, Pratma IK. Biocompatibility of UV light-sterilized hydroxyapatite graft from crab shell (*Portunus Pelagicus*) with human gingival fibroblast cell culture. *J Postgrad Med Inst* 2021; 35(1): 19-22. <https://doi.org/10.54079/jpmi.35.1.2731>

ABSTRACT

Objective: To determine the common locations of traumatic ulceration in denture supporting tissues following implantation of new complete dentures by prosthodontic postgraduate students.

Methodology: This cross sectional study was conducted in the department of prosthodontics, Khyber College of Dentistry, Peshawar on 184 patients. Patients with newly placed dentures were examined after 3 to 4 days, on their first follow up visit, for the presence of traumatic ulceration. Pre-defined locations in the edentulous jaw were examined for the presence of traumatic ulcers. Data was entered and analyzed with the help of SPSS version 20.

Results: The mean age was 55.85 ± 2.22 years with male to female ratio of 1:1.9. Patients returning with one or more traumatic ulcers 3 to 4 days following the placement of their complete dentures were 141 (76.6%). More traumatic ulcers were found in tissues beneath mandibular dentures ($n=134$, 72.82%) compared to tissues beneath maxillary dentures ($n=105$, 57.06%). The most common sites to develop traumatic ulcers were the retromylohyoid area ($n=73$, 39.7%), maxillary vestibular sulcus between labial frenum and buccal frenum ($n=52$, 28.3%), maxillary tuberosity ($n=51$, 27.7%), mandibular vestibular sulcus at buccal shelf region ($n=47$, 25.5%) and the lingual sulcus at paralingual region ($n=36$, 19.6%).

Conclusion: Traumatic ulcers in denture bearing tissues were reported in majority of the patients who received complete dentures. Retromylohyoid area was reported as the most prone area to the ulceration than others.

Key Words: Traumatic ulcer; Maxilla; Mandible; Complete denture

INTRODUCTION

Self esteem and quality of life have a significant association with the presence or absence of teeth especially with regard to elderly individuals.¹ Tooth loss at any age may affect aesthetics as well as speaking and masticatory abilities.² Hence dentists, and more so prosthodontists, have a major role in reestablishing the patients dentition and a functional occlusion.² The most common and relatively least expensive option for the replacement of entire dentition for completely edentulous patients in our set up is a conventional complete denture. The responsibility of a prosthodontist does not conclude with the placement of a set of complete dentures in an edentulous patient. The post insertion period of complete dentures is critical to the success of the treatment since patients face many problems in adapting to and in accepting newly provided dentures.³ It has also been reported that with aging, the challenge to manage and adapt to any conventional removable prosthesis becomes even steeper for the geriatric population.⁴

Despite the fact that conventional complete denture is a relatively cheaper and widely used treatment mo-

dality for edentulous patients, its fabrication requires numerous steps that demands several visits by the patient along with several clinical and laboratory procedures.^{2,5,6} It is thus quite prone to manufacturing faults resulting in various complications such as inadequate retention and stability, ulcerations in denture bearing tissues, fracture of denture teeth or the denture base, speech difficulties, denture related stomatitis and other mucosal injuries.²

Traumatic ulcers associated with removable complete denture wearing are the most common complications faced by the patients.⁷ In a study, it was found that out of 122 patients with placement of complete dentures, 106 (87%) returned with minor or severe lesions of oral mucosa.⁸ The most frequent regions of denture irritations in the maxilla were labial frenum, buccal frenum, maxillary tuberosity, edentulous ridge, vestibular sulcus between labial and buccal frenum, vestibular sulcus between buccal frenum and maxillary tuberosity. In the mandible, retromylohyoid area, retromolar pad area, lingual sulcus at the paralingual region, edentulous ridge, vestibular sulcus between buccal and labial frenum and vestibular sulcus at the buccal shelf

region⁸. These ulcers may cause patients stop wearing their dentures and lose faith in their dentist.⁸

The purpose of this study was to report the frequently occurring locations of traumatic ulcers in patients who return with the complaint of pain following placement of new conventional complete dentures. Dissemination of this information will facilitate education of dental practitioners in constructing conventional complete dentures and for provision of diagnostic information of the culprit areas involved and thus shall improve patients comfort and reinforce the patients trust in the care provider.

METHODOLOGY

This cross-sectional descriptive study was performed at the Prosthodontics Department of Khyber College of Dentistry, Peshawar over a period of 18 months. A sample size of 184 was calculated using the results of a study carried out by Kivovics et al of 87% at a 5% confidence interval.⁸ Adults of both genders in the age range of 50-60 years, having received new conventional complete dentures in both arches and denture, with a wearing history of less than a week, were included in the study. All dentures were made by post-graduate trainees using the same materials and steps for fabrication, under supervision. Data was collected using a structured performa. After recording the personal data, the nature of the patient's complaint and the relevant history, intra oral examination was performed. The complete denture was evaluated outside and inside the patient's mouth.

Statistical analysis of the data was done using the software Statistical Package for Social Sciences (SPSS) version 20.0. Post stratification chi-square test was applied keeping p value of ≤ 0.05 to be significant.

RESULTS

The mean age of the sample was 55.85 ± 2.22 years. Age distribution is given in figure 1. Out of 184 edentulous patients, majority (n=121, 65.76%) were females and 63 (34.24%) were males with a male to female ratio of 1:1.9. Out of these 184 patients fitted with new conventional com-

plete dentures, 141 (76.63%) returned with single or multiple traumatic ulcers in one or both arches.

As shown in table 1, 105 subjects developed traumatic ulcers in the maxilla while 134 subjects returned with the same complaint in the mandibular jaw. Ninety eight of these subjects had developed a traumatic ulcer in both arches. Table 2 shows distribution of ulcers at various sites in maxilla.

Table 3 shows that in the mandible, the most frequent site for the development of traumatic ulcers was the retromylohyoid area with ulcers occurring in 73 (39.7%) patients.

Chi square test showed no significant relationship between age and location of traumatic ulcers in general with the exception of vestibular sulcus between labial and buccal frenum in the maxilla which showed a p-value of 0.010 which was significant.

DISCUSSION

Edentulism is important as a correlate of self esteem and quality of life in regard to older adults. Loss of dentition significantly impairs appearance, speech and oral functions, consequently prosthodontic procedures are vital in re-establishing dentition.

In our set up, conventional complete dentures are the most commonly used treatment modality as the replacement of natural dentition in edentulous patients. The role of a prosthodontist does not end with the placement of a set of complete dentures in an edentulous patient. The post insertion period of complete dentures is critical to the success of the treatment since patients face many problems in adapting to and in accepting newly provided dentures. Traumatic ulcers associated with removable complete denture wearing are the most common complications faced by the patient.

The mean age of the patients in our study was similar to another study.³ The large proportion of females resulting edentulous between the age of 50 and 60 years may be due to cultural values imposing restriction on free movement of females for seeking treatment of dental illnesses affecting access to dental care which has also been pointed out in another study by Ojanuga.⁹

Traumatic ulcers were more commonly found in tissues underneath mandibular complete dentures compared to maxillary complete dentures, which is consistent with other studies.^{3,8} These results are not unexpected. Mandibular denture has less support and retention compared to maxillary denture due to a smaller denture bearing area. Presence of tongue and greater movement range of mandibular denture makes this situation more complicated. Further, clinicians may attempt to extend the base as far as possible and resorption of the supportive mandibular alveolar submuco may make the mucosal tissue extremely sensitive to injury.^{3,8}

In the current study, most prevalent traumatic ulcerations in the maxillary denture bearing tissues were found in the vestibular sulcus between labial and buccal frenum followed by the maxillary tuberosity region and the vestibular sulcus between buccal frenum and maxillary tuberosity. This is consistent with the study carried out by Kivovics et. al.⁸ In the mandible, traumatic ulcers were most prevalent at the retromylohyoid region, followed by the vestibular sulcus at the buccal shelf region and the lingual sulcus at the paralingual region, which is consistent with the studies carried out by Kivovics et al and Sadr et al.^{3,8} Since dentists tend to extend denture flanges as much as possible to overcome the retention problem, the highest number of injuries are seen in the borders and the flanges.³

In general, the location of traumatic ulcers did not have any significant relationship with age or gender of the subjects with only two exceptions. Only the maxillary vestibular sulcus between labial and buccal frenum showed a significant relationship with age, while the posterior palatal seal region showed a significant relationship with gender.

The limitations of this study are that it did not include patients with extended bony deformations or medically unfit patients. Therefore, further investigations are suggested to reflect post insertion treatment and needs of patients with these anatomic deformations and medical illnesses. Moreover, the study was limited to only the first follow up appointment, three to four days following placement of the complete dentures. Further studies need to be carried out regarding the prev-

Table 1: Location of traumatic ulcer

Arch	Frequency of traumatic ulcers	Percentage
Maxilla	105	57.06%
Mandible	134	72.82%

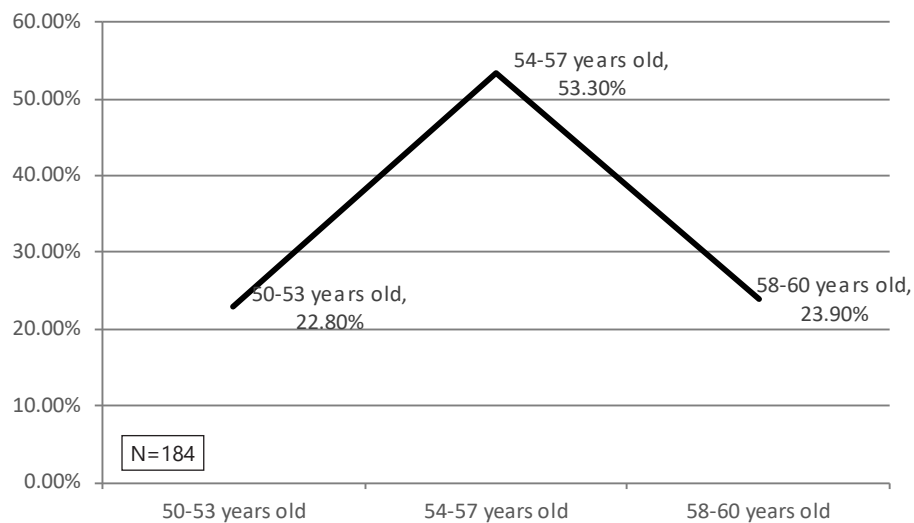
Table 2: Location of traumatic ulcers in maxilla

Location	Subjects returning with traumatic ulcers	Percentage
Labial Frenum	25	13.6%
Buccal frenum	16	8.7%
Maxillary tuberosity	51	27.7%
Posterior Palatal Seal	25	13.6%
Edentulous ridge	04	2.2%
Vestibular Sulcus between labial frenum and buccal frenum	52	28.3%
Vestibular sulcus between buccal frenum and maxillary tuberosity	31	16.8%

Table 3: Location of traumatic ulcers in mandible

Location	Subjects returning with traumatic ulcers	Percentage
Retromylohyoid area	73	39.7%
Retromolar Pad	32	17.4%
Edentulous ridge	16	8.7%
Lingual sulcus at paralingual region	36	19.6%
Vestibular sulcus between labial frenum and buccal frenum	34	18.5%
Vestibular sulcus at buccal shelf region	47	25.5%

Figure 1: Age distribution



alent causes for traumatic ulcers as well as the presence of ulcerations after adjustments made in the first follow up visit. The complete dentures were made according to the same procedure and by postgraduate students, yet operator bias may be present regarding skill level in fabricating complete dentures, despite a similar education level. Therefore, these findings cannot be generalized to the population. In order to accomplish this, further studies are needed.

CONCLUSION

Traumatic ulcers are more frequent in the tissues underneath mandibular complete dentures compared to the maxillary ones. Since most mucosal injuries are located in the borders and vestibule areas, it can be concluded that dentists tend to extend the denture flanges as much as possible in order to improve retention and stability, thus resulting in overextended flanges.

REFERENCES

1. Da Silva HF, Filho PRSM, Piva MR. Denture related oral mucosal lesions among farmers in a semi arid Northeastern Region of Brazil. *Oral Pathol Oral Cir Bucal*. 2011; 16(6):740-4. <https://doi.org/10.4317/medoral.17081>
2. Bilhan H, Geckili O, Ergin S, Erdogan O, Ates G. Evaluation of satisfaction and complications in patients with existing-complete dentures. *J Oral Sci*. 2013; 55(1):29-37. <https://doi.org/10.2334/josnusd.55.29>
3. Sadr K, Mahboob F, Rikhtegar E. Frequency of traumatic ulcerations and post insertion adjustment recall visits in complete denture patients in an Iranian Faculty of Dentistry. *J Dent Res Dent Prospects*. 2011;5(2):46-50 <https://doi.org/10.5681/jodddd.2011.010>
4. Aghdaee NA, Rostamkhani F, Ahmadi M. Complications of complete dentures made in Mashud Dental School. *J Mash Dent Sch*. 2007;31:3.
5. Bilhan H, Erdogan O, Ergin S, Celik M, Ates G, Geckili O. Complication rates and patient satisfaction with removable dentures. *J Adv Prosthodont*. 2012; 4(2):109-15. <https://doi.org/10.4047/jap.2012.4.2.109>
6. Goiata MC, Filho HG, dos Santos DM, Barao VAR, Junior ACF. Insertion and follow up of complete dentures: a literature review. *Gerodontology*. 2011;28(3):197-204. <https://doi.org/10.1111/j.1741-2358.2010.00368.x>
7. Jainkittivong A, Aneksuk V, Langlais RP. Oral mucosal lesions in denture wearers. *Gerodontology* 2010;27(1):26-32. <https://doi.org/10.1111/j.1741-2358.2009.00289.x>
8. Kivovics P, Jahn M, Borbely J, Marton K. Frequency and location of traumatic ulcerations following placement of complete dentures. *Int J Prosthodont*. 2007; 20(4):397-401.
9. Ojanuga DN, Gilbert C. Women's access to healthcare in developing countries. *Soc Sci Med*.1992;35(4):613-7. [https://doi.org/10.1016/0277-9536\(92\)90355-t](https://doi.org/10.1016/0277-9536(92)90355-t)

Author's Contribution

EK Conceived the idea, made the plan, carried out data collection, did script writing and statistical compilation according to the research proposal. AK did data collection as per methodology, refined the manuscript and did statistical analysis. AK, MK, SS did data collection as per methodology, refined the manuscript and did literature search and bibliography. Authors agree to be accountable for all aspects of the work in ensuring that questions related to the accuracy or integrity of any part of the work are appropriately investigated and resolved.

Conflict of Interest

Authors declared no conflict of interest

Grant Support and Financial Disclosure

None

Data Sharing Statement

The data that support the findings of this study are available from the corresponding author upon reasonable request.