

## Post-Prostatectomy Stricture Clinical Evaluation and Management

H. Bilal,\* M.B., B.S., M.S.,  
F.I.C.S.

Postgraduate Medical Institute,  
Lady Reading Hospital,  
Peshawar, Pakistan

### Summary

*Seven cases of Urethral Strictureing are discussed in this article with emphasis on clinical, radiological and endoscopic evaluation. It is suggested that the physio-pathological basis of the disease lends itself to certain clinical syndromes in respect of benign prostatic fibroadenomatous disease, which itself clearly demarcates the parameters of definitive surgical treatment. The author believes that the preventive measures largely originate from rational understanding of the whole mechanism and the objective of the exercise is the prevention of these strictures.*

### Case Reports

#### CASE NO 1 : Median lobe syndrome

Mr. M.A.K., age 64, was admitted on 23/3/1983 to a certain surgical unit with a history of haematuria and clot retention. He had been, for the previous four months, complaining of frequency of micturition during the night.

No urogram or blood chemistry was available at the time of his referral. He was emaciated, anaemic, severely dehydrated and had a persistent purulent supra-pubic fistula. The previous surgery consisted of an attempted catheterization followed 12 hours later by supra-pubic operation, the details of which were not known to the patient. Apparently the prostatic cavity was packed: the pack remained for 4-5 days and later repacked alongwith series of bouginage and dilatation which followed over a period of 3-4 months.

An infusion nephro-urogram showed bilateral hydro-nephrosis and hydro-ureter. The bladder was re-opened and a virtually complete stenotic internal urethral orifice was found. A wide trigonectomy was done using a diathermy

---

\*Associate Professor and Head, Department of Urology, Postgraduate Medical Institute and Consultant Urologist, Lady Reading Hospital.

cutting electrode. A wedge of the detrusor muscle under dense fibrotic scar was excised from the posterior aspect (this was sent for biopsy: reported to be benign) and internal urethral orifice was widened sufficiently to admit the index finger. A 24 ch Foley's catheter was introduced per urethrum and the bladder was closed with retropubic drian. No antibiotics were used and the patient made an uneventful recovery, the urethral catheter having been removed on the 10th day.

This patient obviously had a median lobe adenoma which bled and produced clot retention. An attempted enucleation led to laceration of the bladder neck and the packing produced massive infection with fibrosis which was then added by intermittent bouginage. If a proper and a radio'logical investigation had been done after supra-pubic cystostomy or preferably earlier, the condition would have been fairly obvious. Ideally transurethral resection (T.U.R.) would have been the method of choice, but for this purpose a pre-operative endoscopic examination was an absolute necessity. For an extensive T.U.R., supra-pubic large bore channel can be used through a very small skin incision from which irrigation can be done much more efficiently than through the resectoscope channel.

#### CASE NO. 2

Mr. Z.K., age 65, was referred in January 1983 with severe frequency, difficulty and dribbling of urine and occasional bouts of fever. About 6 weeks earlier he had been admitted and operated elsewhere for his prostate adenoma. The supra-pubic scar had not adequately healed and this added to his discomfort. The patient had, prior to his surgery, not complained of any particular urological symptoms. He had sudden bouts of retention of urine following a longish journey to his village and was admitted to a local hospital where an attempted catheterization failed and he was operated upon. A supra-pubic tube had been inserted which was removed after 2 weeks and although the wound healed but his urinary stream became poor and it became extremely difficult for him to pass urine. When first examined, he had obvious distended bladder, empty rectum, looked distressed and dehydrated with a very dry tongue. An emergency intravenous pyelogram revealed complete absence of function of both kidneys but at the end of third hour faint shadow of the dye was visualised in a small contracted bladder.

An 18ch Foley's catheter was introduced per urethrum which drained only a few c.c. of pus and approximately 100 cc of blood stained urine. The urinary bladder was opened and dense scarring found at the internal urethral orifice. It was difficult to locate the orifice and it appeared that as if the Foley's catheter was lying in the posterior urethra which encountered for the fact that very little urine came through earlier.

A wide resection of the internal vesical orifice was carried out with diathermy electrode (cutting) and the resultant bleeding was controlled with coagulation. A small stone in the posterior urethra was also removed. A 20 ch Foley's catheter was guided and the bladder drained. Pyopen injections 500 mg/8 hourly for one week on account of the culture and sensitivity report were given. The patient made a slow but steady recovery and was discharged on the 25th day.

This case again illustrates the extreme hazard of attempting to enucleate the small median lobe and failure to do a trigonectomy as an essential part of the operation. It is suggested that transurethral resection is the most important single procedure in such cases and the surgeon must make sure that no fibrous tags or mucous folds are allowed to remain before closing the bladder. A preliminary endoscopy is a must and transurethral resection is the ideal procedure in such cases.

#### CASE NO. 3 : Malignant prostate

Mr. M.S., age 72, was admitted to a general surgical unit in November, 1982. He had been complaining of frequency and difficulty of urination for some months; and apparently his prostatic fibroadenoma removed through transvesical approach from which he made slow recovery. He started having extreme difficulty in passing urine and about 4½ months later, he was re-admitted at another hospital and a supra-pubic cystostomy done. A wide bore rubber catheter was left in the bladder for weeks and at the time of his referral, he had developed supra-pubic fistula with considerable infection of the supra-pubic tissues.

Rectal examination revealed a hard nodular prostate, particularly on the right side with complete obstruction of its morphology. He had a second degree haemorrhoids which made this examination rather distressing.

Intravenous urogram showed bilateral hydroureters with leakage from the bladder. The bone scan was negative. The right inguinal lymph nodes were palpable. There was slight oedema of the right ankle.

The bladder was reopened through the original fistula, major portion of the dense trigone resected and a urethral and a bladder Foley's catheters put in. The bladder was closed somewhat loosely. As the histological examination revealed a well-differentiated prostatic carcinoma, therefore he was put on stillbestrol 5 mg daily. In addition he had five points of blood over a period of 3 days. The bladder wound healed in 2½ weeks time and the urethral catheter was removed one month later. He responded well to stillbestrol and is now on maintenance dose of 1 mg daily and is symptom free.

This case emphasises the necessity of histopathological examination of all prostatic adenoma which are removed. This is particularly necessary when the surgeon has difficulty in enucleation or is obliged to cut any part of the posterior lobe which feels dense and hard. In fact forceful enucleation should never be carried out and whenever malignancy is suspected the case should be put on stillbestrol or Honvan without waiting for the histology report. Further in such cases the bladder must always be drained and no prostatic surgery should ever be attempted without previous endoscopic or radiological assessment.

#### CASE NO. 4 : Malignant prostate.

Mr. S.A., age 75, admitted on 13.6.1983. This patient was referred with distressing frequency, first nocturnal, and dribbling of urine and severe pain in both legs. He had been bed-ridden for the last 2 months and was a picture of misery and helplessness.

He blamed much of his trouble to an operation which he had over a year ago at another hospital where according to him some "flesh" had been removed from his urinary bladder. He had gone to this hospital presuming that he had a stone in the urinary bladder but no stone had been found. He was sent home although he had some leak from the supra-pubic wound.

A rectal examination revealed frank carcinoma of the prostate and it was impossible to guide a bougie through it. The bladder was reopened and the entire glandular tissue blocking the urethra was resected and a 20 ch. Foley's catheter was guided in and the bladder drained with a 14 ch. Foley's. He was then Honvonised using 125 mg per day in an intravenous drip for 7 days, monitoring his liver function test every alternate day. He was on the maintenance dose of Honvan tablets. He developed a mild transient jaundice on the 9th and 10th day but cleared up rapidly. The bladder drain was removed on the sixteenth day and urethral catheter on the 25th day. Apart from occasional dribbling, he has a good stream and the leg pain has been completely cured. He can not only sit up but walks around and his general health and blood chemistry have improved tremendously.

At an earlier operation, it was obvious that, it was malignant prostate, parts of which were removed forcibly. This emphasises the necessity of histological examination of all adenoma removed. Forcible enucleation nearly always leads to immediate or delayed disaster and any failure of supra-pubic leak to heal should always make the surgeon suspicious. A proper rectal examination is of great help but there is no substitute for an endoscopic assessment.

#### CASE NO. 5 : Prostatic adenoma.

Mr. A.G.S., age 65, had a prostatic adenoma removed in January, 1980 in the general surgical unit. Subsequently he developed gross haematuria with reten-

tion of urine: in all probability due to the fact that the vital dictum of absolute haemostasis at the end of the procedure was not observed. Later he had bilateral vasectomy done which led to further serious complications.

The bladder was reopened, drained and retrograde in-dwelling catheterization done. Virtually a chronic supra-pubic fistula formed as a result of repeated, frequent urethral bouginage. Severe perineal urethral infection followed, leading to sloughing of the proximal 2 cm of penile urethra, extending to the membranous portion. Perineal urethrostomy was carried out which required almost daily dilatation; a rubber catheter was tied in, which turned prostatic cavity into a series of fibrous horizontal bars as a result of persistent pyocyanous infection. The author reformed the penile urethra using Denis-brown technique which healed extremely well but the resultant angulation at the site of the perineal urethrostomy and the persistent fibrosis at the site of the prostatic cavity necessitated dilatation under general anaesthesia a month later.

This case illustrates the extreme necessity of endoscopic assessment as well as judicious enucleation and clean cutting of the urethra. Further, in the author's opinion, it is better to have a supra-pubic tube than a mal-aligned perineal urethrostomy: this point has repeatedly been emphasised in this article. The case is now being followed up.

It is necessary to have a complete, judicious and effective haemostasis in all prostatic surgery. Reopening the bladder following prostatic surgery does occasionally occur even in the best of hands but at this repeated operation, the time spent on controlling all bleeding sources is handsomely rewarded and packing should very seldom be resorted to. Bouginage should never be attempted in such cases for the chances of creating false passages are great and hazardous after the prostatic surgery. Perineal urethrostomy should be avoided at all costs and there is no necessity for resorting to this procedure in any case. Further, rubber catheter and tubes must never be used. An endoscopic assessment, here in this case, would have surely revealed the presence or absence of diverticulae which might have prevented the diagnosis of "ruptured appendicitis following dilation". Another necessity is the regular intermittent dilatation for at least 3 years following plastic repair of the urethra.

#### CASE NO. 6

Mr. J.M., age 62, was admitted on 7.6.1983. This patient developed nocturnal frequency of micturition approximately three years ago with initial hesitancy, thinning of the stream, a feeling of incomplete evacuation and substantial dribbling towards the end of the act. He was admitted to one of the general hospital in a state of retention and when attempt-

ted catheterisation failed, a supra-pubic Freyer partial prostatectomy was carried out. The bladder was drained with a Foley's catheter; the urethral catheter was removed two weeks later and supra-pubic catheter on 22nd post-operative day. He was discharged with a fairly good stream. A few days later, he continued to complain of dribbling and an intermittent stream.

This state of affairs continued for a year at which time he had urethral dilatation done by another surgeon with some relief. Since he had got used to this state of affairs, he continued for another year when an attempted cystoscopy failed at the general hospital and he had some bleeding following the procedure. He was told that the condition would improve and another year passed, by which time he was passing small quantity of urine without much difficulty but had gross frequency of micturition, averaging 20–25 times a day.

On examination he had a very distended urinary bladder reaching almost the umbilicus and it was fairly obvious that it was overflow with incontinence. I.V.P. showed fairly poor functioning kidneys, though the blood chemistry was within normal limits. Cysto-urethroscopy revealed a well-defined median lobe adenoma which was virtually filling up the entire prostatic cavity having multiple small diverticulae. Median lobe was resected under general anaesthesia, weighed 20 gm and was benign on histology. The patient made an uneventful recovery.

This case illustrates the prime necessity of enucleation, resecting all adenomatous tissues during the operation. It is very likely that, during an open procedure, the large lateral lobes are enucleated whereas the much smaller adenomata lying under the trigone escape enucleation and these subsequently grow, producing stricture-like effects of the bladder neck. A similar position arises during resection when the larger lateral lobes have been dealt with whereas the smaller median lobe adenomata are left in situ because of poor visibility towards the end of the procedure. Contrary to what some urologists have advocated, the author resects the median lobe before dealing with the lateral lobes.

It is necessary to remove all adenomata, residual tags of fibrous and mucus tissues as well as cutting the urethra clearly with a pair of scissors. Forcible tearing of the urethra is very likely to lead to stricture formation which is worse than the original disease. The category of prostatic fibroadenosis is of course the easiest one to deal with and an eventuality of stricture developing would be very remote if the modality of the pre-operative assessment and basic principles of prostatic surgery are comprehensively observed.

#### CASE NO. 7

Mr. A.R., 68 years of age, was admitted to the urological unit in April, 1982 with a supra-pubic fistula following prostatic surgery elsewhere about

eight months earlier. It appears that enucleation of the prostate led to considerable bleeding for which the bladder was reopened and packed. The pack and the bladder drain were left inadvertently for a long period and part of the pack got disconnected and remained in the prostatic cavity.

When first examined, the supra-pubic fistula gave an unpleasant smell. A Foley's catheter could not be introduced per urethrum and on re-opening the bladder, some mucky material was removed from the prostatic cavity and two residual adenomata were also removed. He had developed a stricture possibly due to tearing of the urethra. This stricture was excised from the perineal route and a first stage repair of the membranous urethra was carried out. The bladder was closed and a 22 ch Foley's catheter was left in the urethra. Two months later it was relatively easier to repair the urethra with a flap procedure. He made a slow but smooth recovery.

This case emphasises the necessity that all adenomas must be removed at the time of surgery and also the length and number of packs must be observed; and the necessity of removing the packs on second or third day of the operation. A radiological and endoscopic assessment is a must and as said earlier that in all prostatic surgery, strictures are avoidable.

## **Discussion**

### **PHYSIO-PATHOLOGY**

The prostate gland is basically a sex organ and like others in this category, it is subjected to certain continuous changes during the span of human life. When sexual activities begin, the cells of the gland undergo certain changes under neuro-harmonal influences wherein due to increase quantum of these influences, the cells of the glandular acini become bigger (hyperplasia) and after the stimulus is over, there is a return of the cells to normal size. This phenomenon of physiological adenosis with return to normalcy is perhaps the human body's most delicate physiological action and is seen in most of the sexual glandular acini.

It would be seen subsequently that this theory of clinico-pathological categorisation has a profound effect on the surgical aspect of the disease. The age-old term "Enlarged prostate" must cease to exist, since it has been repeatedly pointed out that the gland need not be enlarged to cause the detrusor irritability. On the contrary, the smaller the gland, the more likely it is going to compress on the prostatic urethra. One single major grave drawback of the term 'Enlarged prostate' is that if on rectal examination, the prostate gland is not palpably enlarged, the physician or the surgeon is very apt to dismiss the gland as the

cause of bladder neck irritability or obstruction. On the other hand patients with a minimal detrusor instability, who have a palpably enlarged gland may undergo surgery with deleterious or occasionally very injurious results. The traditional description that the urethra becomes long and tortuous is not factually correct since the index finger is easily inserted in the posterior urethra to enucleate the adenomas: it is the detrusor hypertrophy or dysfunction that accounts for most of the bladder neck symptomatology.

Sometimes due to an imbalance in the neuro-harmonal influences, the return to normalcy does not occur and one of the three alternative begins to take shape. (Table I). It has been suggested by the author that since the mechanism is similar to that seen in the female breast, a similar terminology be adopted in respect of the prostatic gland (as well as the thyroid). The advantages of adopting it for the prostatic gland are of clinical as well as treatmental importance as is illustrated in Table I.

The advantages of afore-mentioned scheme is that the prostate gland need not be enlarged at all to cause any obstructive phenomenon. The size of the gland is no index to the symptomatology it causes. In the dog the gland grows to the size of human fist without creating any urinary flow disturbances.

When the acinar cells fail to return to normal size and if a substantial number of them follows likewise, the physiological adenosis takes the shape of pathological adenoma since it acquires a false capsule. Element of fibrosis or fibrous tissue invariably mingles in the mass and hence a fibro-adenomatous condition develops. The differentiation is purely arbitrary, much the same way, as has been adopted for the female breast.

When the fibrous element predominates over the adenomatous element, the clinical condition that ensues is conveniently referred to as fibrotic gland. However it is a mixed affair and fibro-adenoma of the prostate accounts for approximately half the cases having bladder-neck symptomatology of an obstructive nature.

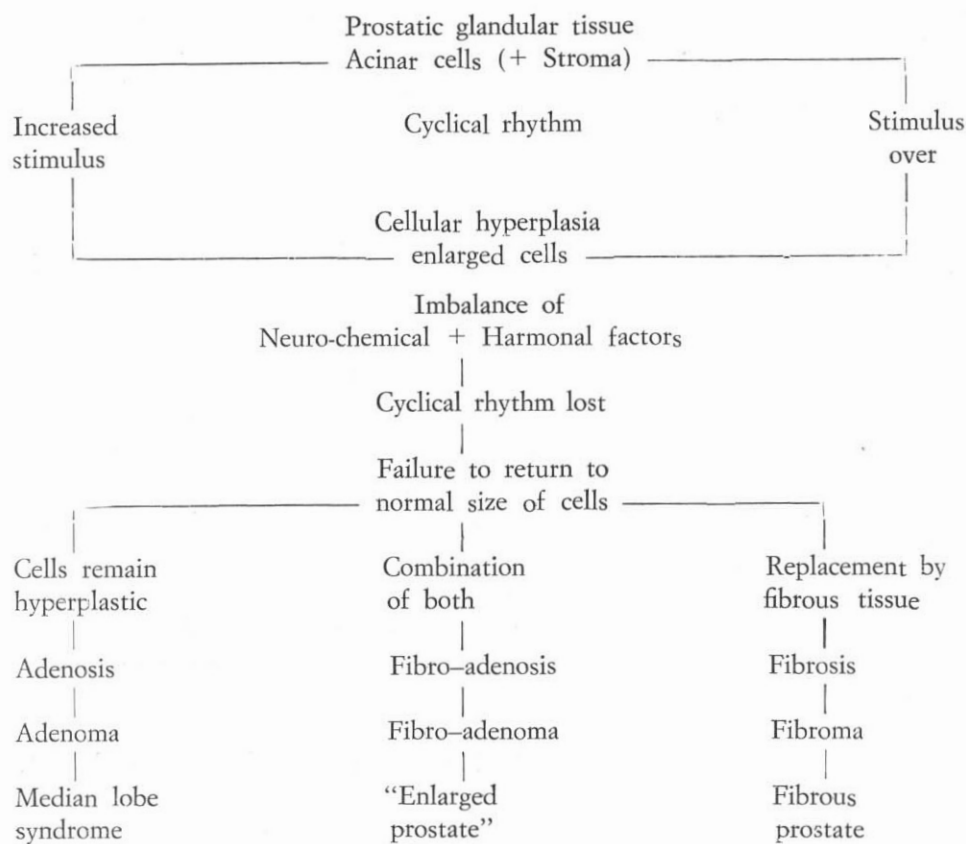
The clinical picture of a prostatic fibro-adenoma, fibrosis and a median lobe adenoma are distinct and different as shown in Table II.

Mere rectal examination is not enough. Endoscopic assessment is vital and cannot be substituted by any other mode of investigation.

It would be seen that in a typical prostatic median lobe adenoma, the patient usually gives a short history, has a plethoric build, is usually obese and presents with a bout of sudden urinary retention or gross haematuria. On the contrary, the fibrous prostate syndrome usually presents in a younger patient with long clinical history which is dominated by an increasing difficulty



Table I – SCHEMATIC REPRESENTATION OF PROSTATIC FIBRO-ADENOSIS



in voiding, progressive thinning of the stream which improves on straining and in some cases, there is a previous history of prostatitis; so that such a category of patients is easily distinguishable. In both these categories, rectal examination is basically negative.

The prostatic fibro-adenosis, as said earlier, accounts for nearly 50% of the patients; the classical text book history is obtainable with nocturnal and subsequently diurnal frequency or initial hesitancy in voiding which is aggravated by straining, occasional bout of haematuria, thin or interrupted stream with moderate to severe dribbling or the odd case of retention. On rectal examination, the classical morphological pattern of the gland is obtained.

Table II – CLINICAL EVALUATION OF PROSTATIC FIBRO-ADENOSIS

Clinical Features	Prostatic Adenoma	Prostatic Fibrosis	Prostatic Fibro-Adenoma
Patient	Plethoric	Younger	—
History	Short	Long	Classical
Haematuria	Present	—	Present
Urine :—			
— Frequency	—	Present	Present
— Difficulty	—	Present	Present
— Stream	—	Thin stream	Thin stream dribbling
— Retention	Sudden	—	Present
Per Rectum examination	Negative	Negative	“Enlarged Prostrate”

Table III – ENDOSCOPIC FINDINGS

Findings	Median Lobe Adenoma	Prostatic Fibrosis	Prostatic Fibro-Adenoma
Passage of instrument	No difficulty	Hold-up of cystoscope	—
Posterior urethra	Normal	Strictered	—
Verumontanum	Normal	—	Congested
Ureteric opening	Normal	Deformed and patulous	Displaced
Bladder trabeculation	Smooth mucosa and normal capacity	Present	Present
Diverticulae	—	Present	—

The endoscopic appearances in these cases are shown in Table III.

In median lobe adenoma, there is no difficulty in the passage of the instrument, the posterior urethra is normal, the verumontanum is normal, the ureteric openings are normal and the bladder has smooth mucosa as well as normal capacity.

In prostatic fibrosis, there is a holdup of the cystoscope in the region of the neck of the bladder (gripping), the bladder is severely to moderately trabeculated with small to large size diverticulae, morphologically deformed ureteric orifices and a soft calculus may be present.

In prostatic fibro-adenoma (bilobar or trilobar), enlargement of the gland is seen with congested verumontanum, displaced ureteric orifices and possibly trabeculation of the bladder mucosa.

I would emphasise that intravenous pyelogram as well as blood chemistry is mandatory before undertaking endoscopic assessment as well as making sure that concomitant urinary infection has been dealt with. In my practice, although I consider these prerequisite qualifications as necessary, yet in emergency cases I have based my surgical approach purely on endoscopic assessment.

The causes of post-surgical stricturing are given in Table IV.

Table IV – CAUSES OF POST-SURGICAL STRICTURING  
(Lack of Endoscopic Assessment)

<p>Enucleation of Median Lobe Adenoma</p> <ul style="list-style-type: none"> <li>— Infection</li> <li>— Lack of Trigonal Resection</li> <li>— S.P. Fistula</li> <li>— Detrusor Instability</li> <li>— Neck Stenosis</li> </ul>	<p>Enucleation of Fibrous Prostate</p> <ul style="list-style-type: none"> <li>— Technically Impossible</li> <li>— Severe Stenosis</li> <li>— Scarring of B/Base *</li> <li>— S.P. Fistula</li> <li>— Persistent Infection *</li> </ul>
<p>Enucleation of Prostatic Fibro-Adenoma</p> <ul style="list-style-type: none"> <li>— Forcible Removal *</li> <li>— Tearing of M/Urethra *</li> <li>— Residual Adenomata *</li> <li>— Malignant Nodule</li> <li>— Prolonged Catheterization</li> <li>— Post-op. Frequent Bouginage *</li> </ul> <p>(* Incomplete Haemostatic Measures)</p>	

**Conclusion**

In an attempt to prevent or minimise the incidence of post-surgical stricturing, I have presented these 7 cases to highlight the failure of the clinician in evaluating the aforesaid categories. A surgical attempt to enucleate a fibrous prostate or median-lobe adenoma would invariably result either in bladder-neck

stenosis or detrusor instability if trigonal resection is not simultaneously done. It would be seen that enucleation of the fibrous prostate is not only technically impossible but paves the way for severe stenosis and scarring of the bladder base and development of supra-pubic fistula. Incomplete haemostasis at the time of operation, forcible removal, tearing of urethra, residual adenomata, malignant nodule, prolonged catheterisation, indiscriminate and injudicious post-operative bouginage: all add up to post-surgical stricture.

With the advent of newer concepts in this field and developments in the realm of detrusor instability, we have to consider the refinements both in the technique of ultra-sounding/suction resectoscope, bladder cannula, fluid inflow as well as induction of hormonal based substances i.e. Primostat; and thus the management of prostatic pathology is undergoing a fairly rapid change. All said and done, many urologists have come across such cases where temporary use of indwelling urethral catheter followed by its removal has led to a prolonged spell of complete freedom from symptoms.

Moreover there are numerous cases on record where an otherwise certain candidate for surgery has been treated just by the control of infection, temporary drainage and prolonged course of Primostat. The only exception to this is a malignant prostate. Much can be done to prevent these nasty post-operative strictures by avoiding injudicious surgery and, when surgery is resorted to, by careful assessment of the patient as well as defining the right surgical technique which varies from patient to patient.

#### References

1. Turner Warwick, R.T., (1969): The investigation and management of the benign prostate in relation to the sphincter mechanism. *Transaction of the Medical Society of London*; 86: 51—54.
2. Turner Warwick, R., Whiteside, C.G., Worth, P.H.L., Milroy, E.J.G., Bates, C.P., (1973a): A urodynamic view of the clinical problems associated with bladder neck dysfunction and its treatment by endoscopic incision and transtrigonal posterior prostatectomy. *British Jour. of Urology*; 45: 44—59.
3. Turner Warwick, R., Whiteside, C.G., Arnold, E.P., Bates, C.P., Worth, P.H.L., Milroy, E.C.J., Webster, J.R., Weir, J., (1973b): A urodynamic view of prostatic obstruction and the results of prostatectomy. *British Jour. of Urology*; 45: 631—645.
4. Duxbury, J.H., Leadbetter, G.W., Leadbetter, W.D.F., (1969): Can prostatectomy be improved. *British Jour. of Urology*; 32, 5: 600.
5. Tanagho, E.A., Meyers, F.H., (1965): Trigonal Hypertrophy. *British Jour. of Urology*; 93: 678.