

## Speech Rehabilitation in Cleft Palate Surgery

Naveed Yousaf,\* M.B., B.S.,  
M.D., D.L.O., F.A.C.S.

and  
Mohibullah Khan,\*\* M.B., B.S.,  
D.L.O., F.R.C.S.

Postgraduate Medical Institute,  
Lady Reading Hospital,  
Peshawar, Pakistan

### Abstract

*An attempt for a simultaneous anatomical closure of a congenital cleft palate with reconstruction of a functionally competent Velopharyngeal sphincter is the ultimate goal of a surgical craftsmanship. Hypernasality and nasal escape of air are common unwanted stigma associated with a congenital cleft palate. It is a situation where Velopharyngeal sphincteric function is incomplete. To overcome such a situation, a surgical reconstruction of a functional Velopharyngeal sphincter is important.*

*All 56 patients, who were treated between 1982 to 1985, were of the age group: 2 years to 7 years. Routine closure of the palate with associated palatal lengthening procedures were performed. Attempting Pharyngoplasties in a few cases, majority of the patients under-went primary (22%) and secondary (78%) Pharyngopalatoplasties with superiorly based pharyngeal flaps. Improvement in overcoming hypernasality and nasal escape of air, associated with these palatal defects, was achieved in all cases to a variable extent.*

### Introduction

There are three main objectives of cleft palate surgery in order of their importance; first is to produce a normal speech in a developing child with an accurate articulation of words and an acceptable resonance in spoken speech pattern; second is to achieve a near-normal anatomical closure to prevent air and food regurgitation and lastly to minimize growth defects due to repeated surgical interventions in these cases.

---

\* Asstt. Professor, Oto-rhino-laryngology.

\*\* Associate Professor and Head, Department of Oto-rhino-laryngology,  
Postgraduate Medical Institute and Consultant E.N.T. Surgeons, Lady Reading Hospital.

The Velopharyngeal sphincter is situated at the junction between oropharynx and nasopharynx, bounded posterolaterally by superior constrictor muscle and in front by soft palate which consists of a dynamic pair of levator and tensor palatini muscles. The elevation and medial excursion of superior constrictor muscle and a simultaneous backward and upward movement of palate produces an effective closure of Velopharyngeal sphincter.

Incompetency of Velopharyngeal sphincter results in hypernasality and associated sudden escape of air from oropharynx towards nasopharynx during speech performance. Excessive nasal tone in speech is unpleasant and unintelligible for the listener. This is because of the fact that less pounding of words in oral cavity is achieved. The words like vowels are heard in hypernasal tone which adds more than required resonance to the speech.

The Velopharyngeal sphincter has been studied by researchers of remarkable variety of background. The structural evaluation of a normal and anomalous anatomy of this region, in the light of functional loss or defect, has led to a better understanding of speech and further provided a variety of approaches to the problem and its ultimate correction.<sup>1-7</sup>

Majority of cases with congenital cleft palate and some cases of mega-nasopharynx are responsible for the defective closure of Velopharyngeal sphincter. Other causes which produce Velopharyngeal incompetence are post-operative cleft palates, post-adenoidectomy cases, paralytic palates and in palates where neoplastic lesions are resected.

In management of these cases, the primary concern in the past was just to close the defect and leave the speech defect for a natural resolution. Later on, as the knowledge of functional anatomy grew, surgeons started thinking of reconstruction of the Velopharyngeal region. Initially improvement was focussed on palate mobility in terms of musculature retro-displacement and its repair; then improvement in length of the palate was entertained.<sup>8-10</sup> Later on studies proved that superior constrictor muscle imparted an important role in the closure of Velopharyngeal sphincter; thus Pharyngoplasties, Pharyngeal augmentation and Pharyngeal flap for cleft palate repair came into picture.

## **Material and Methods**

During 1982 to 1985, we have managed 56 cases of Velopharyngeal incompetence. Majority of these cases were congenital palatal clefts; these included new and some previously repaired cases. The age at which surgery was undertaken in new cases was between 2-7 years. This was done keeping in view the morality and morbidity related to surgery, speech developing age and facial bony growth.

The second important consideration was type of surgery and general condition of the patient. Staging of surgery was done in view of patient's age and built as well as the type and length of anaesthesia available to us.

In all the cases, where associated cleft lip was present, a separate repair was carried out earlier.

In our surgical protocol, we divided our patients into three major groups with respect to their degree of palatal defect, speech disability and surgical procedures:—

Groups/Lesions	Speech Disability	Surgery Performed
<b>GROUP-I</b>		
(a) Unilateral isolated cleft.	Nil to minimum hypernasality.	(a) Simple closures, Von Lengenbeck type. (Fig. 1, 2, 3).
(b) Cleft palate with normal nasopharynx.		(b) Push back Palatoplasty. (Fig. 4).
(c) Cleft of the soft palate including submucous clefts.		(c) Primary Palato-pharyngoplasties. (Fig. 9).
(d) Repaired clefts of the palate.		
<b>GROUP-II</b>		
(a) Complete unilateral cleft of the <b>palate.</b>	Marked hypernasality with nasal escape of air.	(a) Muco-periosteal flap techniques with lengthening and palatal push back procedures. (Fig. 4-8).
(b) Complete bilateral wide cleft of the palate.		(b) Stage closure of soft palate followed by hard palate (done after 6/9 months). Palato-pharyngoplasties with superiorly based flaps (one year later). (Fig. 9).
<b>GROUP-III</b>		
Nasopharyngeal Lesion:	Minimum to mild hypernasality.	Primary Palato-pharyngoplasty with superiorly based pharyngeal flap. (Fig. 9).
(a) Mega-nasopharynx.		
(b) Paralysed palates (Long standing).		
(c) Post-surgical palates.		

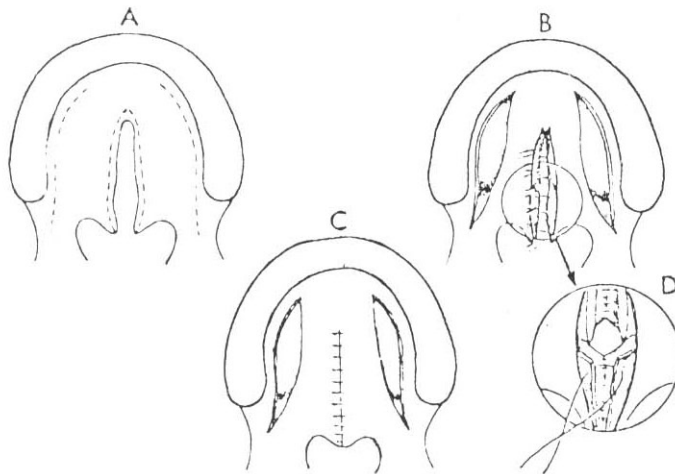


Fig. 1 Von Langenbeck palato-plasty for isolated cleft palate.

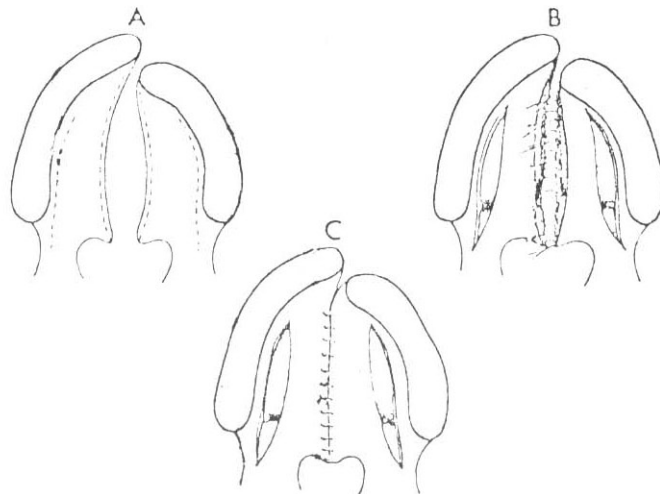


Fig. 2 Von Langenbeck palato-plasty for complete unilateral cleft palate and cleft lip.

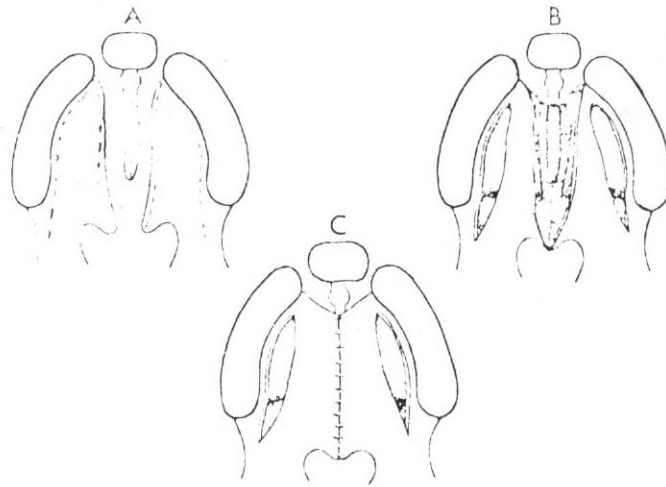


Fig. 3. Von Langenbeck palato-plasty for complete bilateral cleft palate and cleft lip.

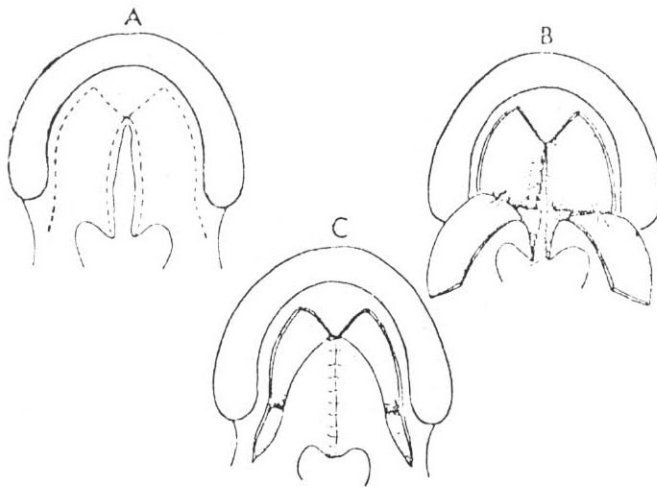


Fig. 4. Palatal lengthening or push back procedure in isolated cleft palate.

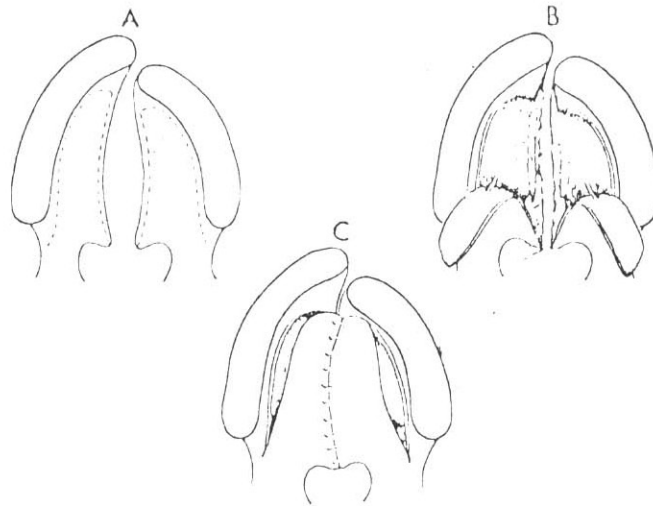


Fig. 5. Palatal lengthening procedure in complete cleft palate.

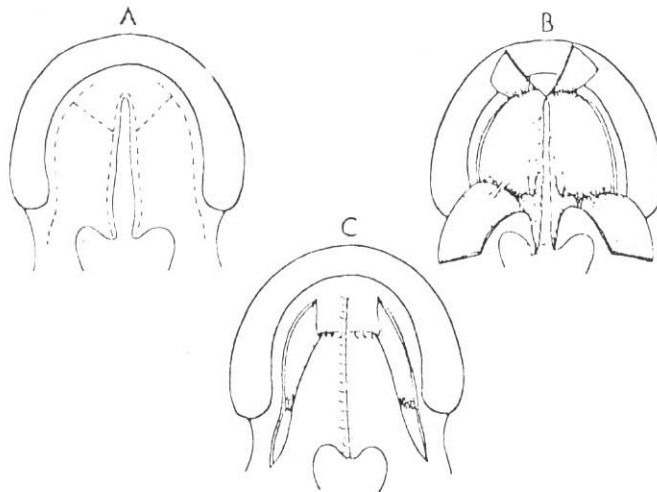


Fig. 6. Palatal lengthening procedure by four flaps technique in isolated cleft palate.

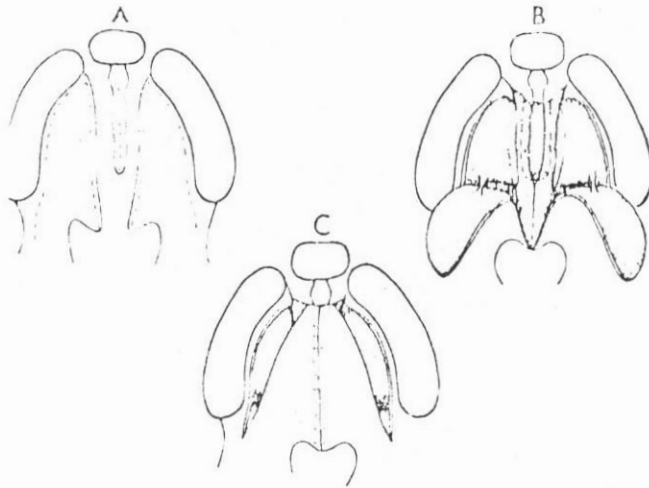


Fig. 7. Two flaps technique in bilateral complete cleft palate.

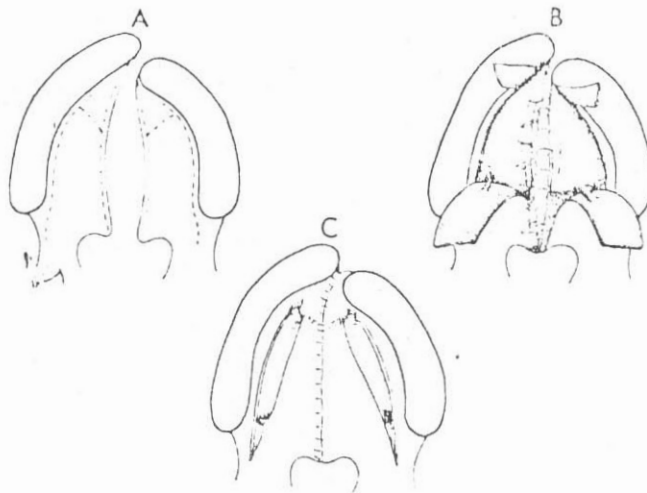


Fig. 8. Four flaps palatal lengthening procedure in unilateral complete cleft palate.

FIGURE 9. PALATO-PHARYNGOPLASTY USING SUPERIORLY BASED PHARYNGEAL FLAP.

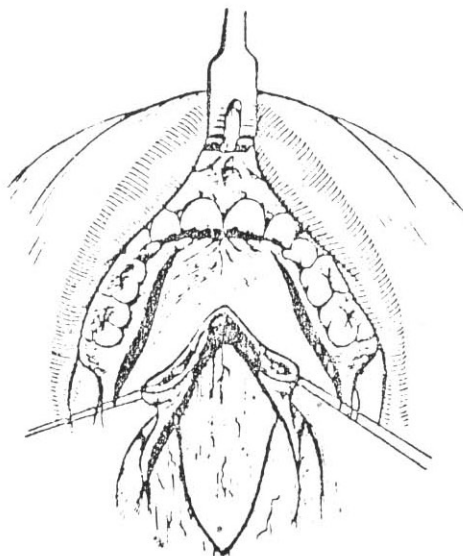


Fig. 9. (A) Cleft soft palate split in mid-line, superiorly based pharyngeal flap designed, lateral release incisions given on sides of palate to prevent post-operative tension in mid-line sutured area.

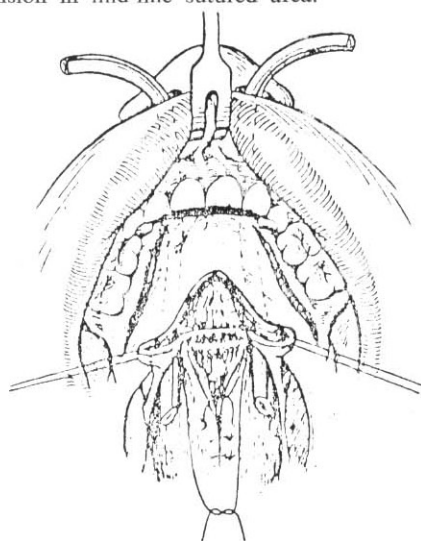


Fig. 9. (B) Pharyngeal muco-muscular flap from posterior pharyngeal wall incorporated with palate.



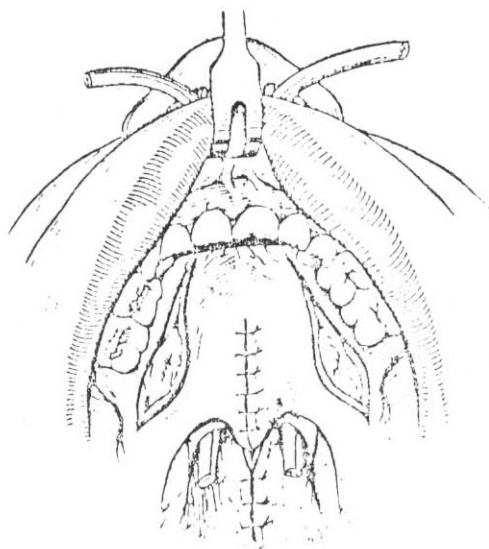


Fig. 9. (C) Posterior pharyngotomy gap sutured, thus narrowing the pharynx. The palate closed on top of pharyngeal flap in mid-line.

### **Conclusion**

Simple anatomical closure of a congenital cleft palate is surgery of the past. Improved surgical reconstructive techniques, to achieve a competent Velopharyngeal sphincter, are ultimate goals for achieving a better speech performance. The understanding of the subject and scope of early, easy and improved surgical methods are still a challenge for the future. Presently Pharyngo-palatoplasty with superiorly based flap is method of choice. Post-operatively the nasopharynx and oropharynx communicate via two lateral narrow ports. This procedure thus achieves a competent and a dynamic Velopharyngeal sphincter using pharyngeal flap as a biological obturator.

---

## References

1. Cotton, R.T., (1977): Lateral defects in Velopharyngeal Incompetence. *Archives of Otolaryngology*; 103 : 90.
2. Edgerton, M.T., Declan, A.L., (1971): Surgical retro-displacement of the Lavator Veli Palative muscle. *Plastic Reconstruction, Surg.*; 47 : 154-165.
3. Hogan, N.N., (1973): Clarification of the Surgical goals in Cleft Palate Speech and the introduction of the lateral port control Pharyngeal Flap. *Cleft Palate J.*; 10:337.
4. Broohan Sommerlab, I.G. (1985): Lavator Palati & Palatal Dimples Anatomy + Clinical Significance. *British Journal of Plastic Surg.*: 326-332.
5. Komar, P.A.V., (1985): The use of Vomerine flap for Palatal lengthening. *British Journal of Plastic Surgery*; 343-346.
6. Millard, R., (1973): The Island flap in Cleft Palate Surgery. *Surg G.*; 065: 116, 297-300.
7. Pigott, R.W., (1969): The Nasendoscopic appearances of the normal Palato Pharyngeal valve. *Plast: Reconst: Surg.*; 43: 19-24.
8. Skoinick, M.L., (1969): Video Velopharyngographs in patients with nasal speech with emphasis on lateral pharyngeal motion in Velopharyngeal closure. *Radiology*; 93: 747-755.
9. Skoinick, M.L., (1970): Videofluoscope examination of the Velopharyngeal Palatal during Phonation in lateral and base projections, *Cleft Palate J.*; 7: 803-816.
10. Stark, R.B., Dew Wamlen, C.R., (1960): Addition of a Pharyngeal Flap to Palatoplasty *Plastic Reconstructive Surg.*; 26: 378.
11. Warren, D.W., DU. Bois, A.B., (1964): A pressure flow technique for measuring Velopharyngeal Orifice area during continuous speech, *Cleft Palate J.*; 1: 52-71.
12. Yousaf, N., (1985): Velopharyngeal Incompetence: Functional Evaluation. *Pak. J. of Otolaryngology*: 95-98.