

# TC99m LABELLED WHITE CELL IMAGING IN INFLAMMATORY CONDITIONS

GM SHAH SYED, SW NEWTON AND JJ BARRETT

*Department of Nuclear Medicine,  
Kings College Hospital, Denmark Hill, London, U.K.*

## SUMMARY

Tc99m HMPAO labelled white cell imaging was performed in 12 patients with suspected inflammatory foci. Images were acquired at 1, 2 and 3 hours post-injections. Scanning was helpful in 11 patients to detect the sites of inflammation.

## INTRODUCTION

Tc99m labelled hexa-methyl propylene amine oxime, HMPAO, (Ceretek, Amersham International, U.K) is a lipophilic tracer and has the capability to bind to blood cells. Roddie et al demonstrated that this agent labelled white cells of blood and could be used to detect inflammatory foci in vivo.<sup>1</sup> Patients presenting with the pyrexia of unknown origin (PUO) and the group of patients in whom a distinction between the loosening of prosthesis and infection is required, this methodology can be very useful.

## MATERIAL AND METHODS

Twelve patients were included in this study (five males and seven females). Four patients had clinical diagnosis of inflammatory bowel disease, remaining eight patients presented with PUO. White cell labelling was carried out according to the protocol described by Peters et al.<sup>2</sup> In patients with PUO, overlapping views of the whole body were acquired in anterior and posterior position including the limbs. In patients with suspected inflammatory bowel disease, anterior views of abdomen were acquired. Images were acquired at 1, 2 and 3 hours after the injection of 200 MBq of Tc99m HMPAO white cells. Each image was acquired for five minutes.

## RESULTS

Eleven of twelve studies performed with labelled white cells revealed sites of infection. Table - 1 lists the sites of infection/inflammation detected with white cell imaging. Figure 1 demonstrates an example of a positive scan in a patient suspected of inflammatory bowel disease.

TABLE - 1  
SITES OF INFLAMMATION  
DETECTED ON WHITE CELL  
SCANNING

1. Inflammatory bowel disease	Four patients
2. Pelvis	Three patients
3. Hip joint	One patient
4. Hand (bones)	One patient
5. Lower limb (tibia)	One patient
6. Spine (lumbar)	One patient

## DISCUSSION

Radiolabelled white cell imaging to localise the focus of inflammation is based on the fact that white cells accumulate at the site of inflammation. Gallium-67 and Indium-111 labelled white cell imaging has been employed to localise the inflammatory sites.<sup>3,4</sup> However, these tracers have limited availability, imaging has to be delayed (3-5 days with Ga-67 and 6-24

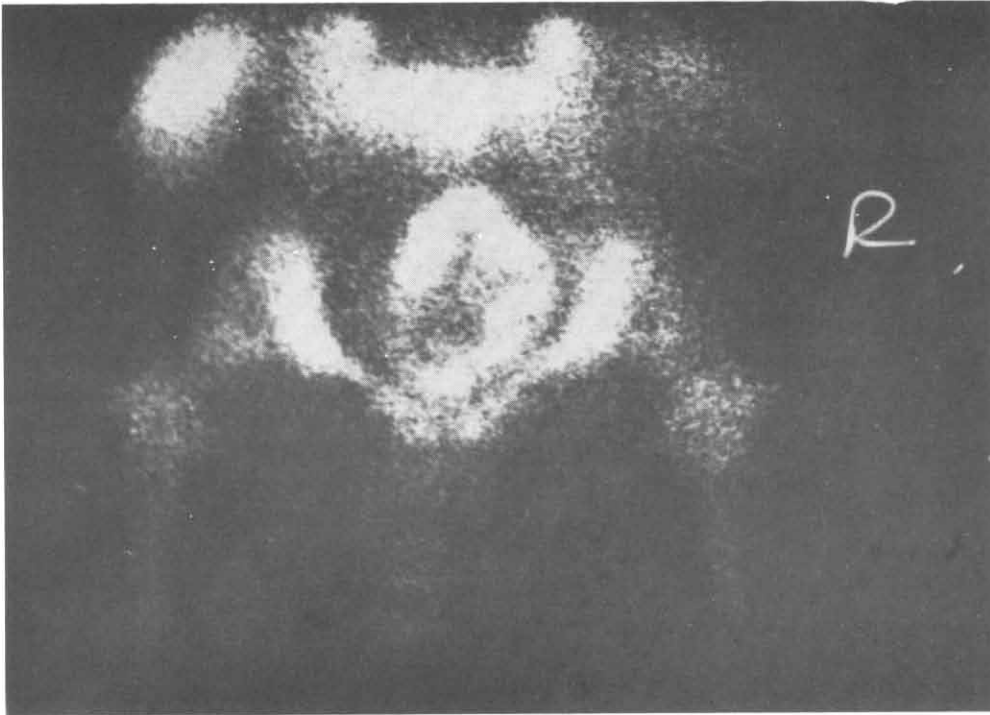


Fig. 1. A scan of inflammatory bowel disease.

nours with Indium 111). Image quality is also poor. In comparison, Tc99m imaging can be performed at any time, imaging is complete within 3 hours and images are of very good quality.

In our study one of the twelve studies was negative. This patient was on antibiotics for four days and this could be the cause of a negative scan. In eleven positive scans the findings of white cell imaging were confirmed on other investigations such as ultrasonography, radiology in 8 cases and surgical drainage in three cases. Hence the sensitivity was 95% and the specificity was 100%. However, other groups have reported false positive studies in patients with abnormal bone marrow distribution.<sup>5</sup>

#### CONCLUSION

We conclude that the white cell imaging is a non-invasive, sensitive and specific technique to localise the inflammatory foci in vivo.

#### REFERENCES

1. Roddie ME, Peters AM, Danpure HJ, et al. Inflammation: Imaging with Tc99m HMPAO labelled leucocytes. *Radiology*. 1988; 166: 767.
2. Peters AM, Osman S, Handersan BL, et al. Clinical experience with Tc99m HMPAO for labelling leucocytes and imaging inflammation. *Lancet* 1986; 2: 946.
3. Peters AM, Saverymuttu SH, Keavy HJ, et al. Imaging of inflammation with In-111 labelled leucocytes. *J Nucl Medicine*. 1983; 24: 39.
4. Lavender JP, Lowe JL, Barker JR, et al. Ga-67 citrate scanning in neoplastic and inflammatory lesions. *Br J Radiology*. 1971; 44: 361.
5. Cunningham DA. Abnormal bone marrow distribution following unsuccessful hip replacement: a potential confusion on white cell scanning. *Eur J Nucl Med*. 1991; 18: 67.