

AN ANALYSIS OF SKELETAL ABNORMALITY IN ACUTE CHILDHOOD LEUKAEMIA

MOHAMMAD ARSHAD KHAN, ALI NAWAZ KHAN AND
INAYAT SHAH ROGHANI

*Department of Radiology,
Postgraduate Medical Institute, Lady Reading Hospital, Peshawar.
North Manchester General Hospital, Manchester.*

SUMMARY

Bone changes seen in one hundred children diagnosed as having acute leukaemia have been analysed and related to difficulties in diagnosis, survival time and atypical forms of bone changes. We found no clear relationship between the presence or type of bone changes at presentation and eventual survival. However, patients who developed bone involvement during the course of the illness did not do as well. Generalised disease such as neuroblastoma may closely mimic or a solitary lesion may closely resemble a bone sarcoma. The previous publications in this field have been comprehensively reviewed.

INTRODUCTION

The longer survival and increasing incidence of complete remission in children with acute leukemia, has been brought about by recent advances in the understanding and treatment of this condition. A retrospective study of one hundred children with acute leukaemia has enabled us to assess the significance of bone involvement, seen radiologically, in establishing the prognosis and in relation to the effects of treatment. The considerations were as follows.

- a. Whether the early finding of bone involvement altered the long term survival rate.
- b. Whether the pattern of bone involvement was a useful index of the success or failure of therapy.
- c. To note the types and frequency of atypical bone changes.
- d. To present a comprehensive review of the types of bone involvement seen in acute leukemia in children.

MATERIAL AND METHODS

One hundred case records of children treated for acute lymphocytic leukaemia, were inspected, of these 88 had Acute Lymphocytic Leukaemia and 12 had the acute myeloid form. Formal skeletal surveys had been carried out in 27 of these children, either because they had symptoms referable to bone, or because the condition was thought to be widespread on clinical grounds. In 42 instances only chest radiographs were available, limiting observations to the thoracic cage. Chest radiographs were combined with spine or limb examinations in 18 children, and with abdomen films in 7 cases. The ages of the children in this study varied from two months to fourteen years, 56 were boys.

None of the children with acute myeloid leukaemia were alive at the time of this study, a mean survival time of 6.25 months. Of the 88 children with the acute lymphocytic form 47 were alive at the time of the study, a mean survival time of 22.9 months.

RESULTS

Bone changes were present in 34 children, their distribution in various groups are shown in Table I and the types of bone changes found in Table II. Twenty-five children had bone changes at presentation, 13 of these are alive and in remission. The children who died showed no difference in the extent or type of bone involvement. Nine children developed bone involvement 3 to 8 months after the initial diagnosis, of these two were alive at the time of writing. The correlation between bone changes and clinical findings was high in cases with periosteal reaction seen on the radiographs, and poor in all other types of change. (Fig 1). All four children with periosteal reaction had localised bone pain and tenderness. Conversely 13 patients with bone pain or hip pain and limp had no obvious bone involvement radiologically at that time. Several children with advanced dissemi-

TABLE-I

Types of bone changes	No. of patients
Patchy destruction and lytic lesions	11
Metaphyseal Lucency & destruction	9
Loss of bone density	9
Growth arrest lines	9
Periosteal reaction	4
Suture diastasis	4
Fractures	4
Growth disturbance (other than growth arrest lines)	3
Vertebral Collapse	2
Osteomyelitis of rib	1
Joint effusions	1
Paravertebral mass	1

TABLE-II

Survival	Total Number of Patients	Number of Patients with bone changes
5 years	7	4
4 years	5	2
3 years	11	1

nated bone involvement had no skeletal symptoms.

Loss of bone density (Fig 2 & 3) was a feature in 9 children, this was seen as a generalised change most marked in the metaphyses and vertebrae. Loss of bone density was found in 5 children at

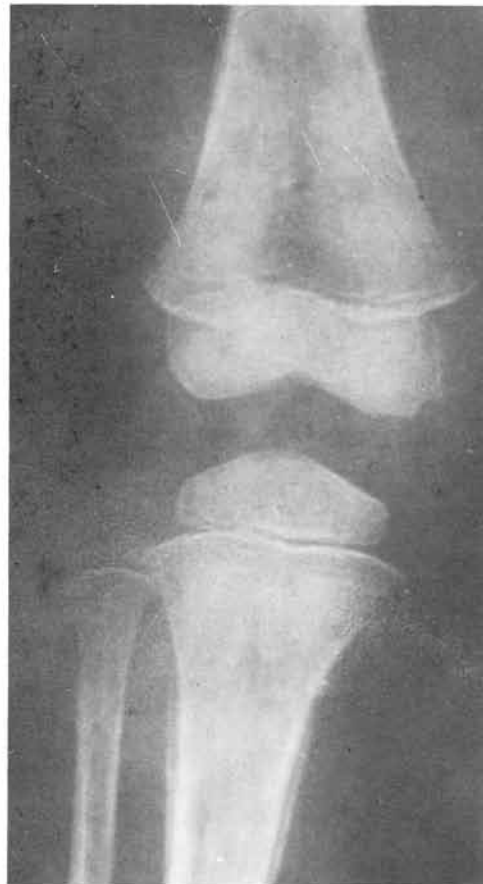

Fig. 1. Periosteal new bone formation with patchy destruction.

presentation and appeared in the remaining four at times varying from 3 months to 4 years after initial examination. Vertebral collapse was a sequel to marked loss of bone density and extensive leukaemic deposits were found in the vertebrae at autopsy in one such patient.

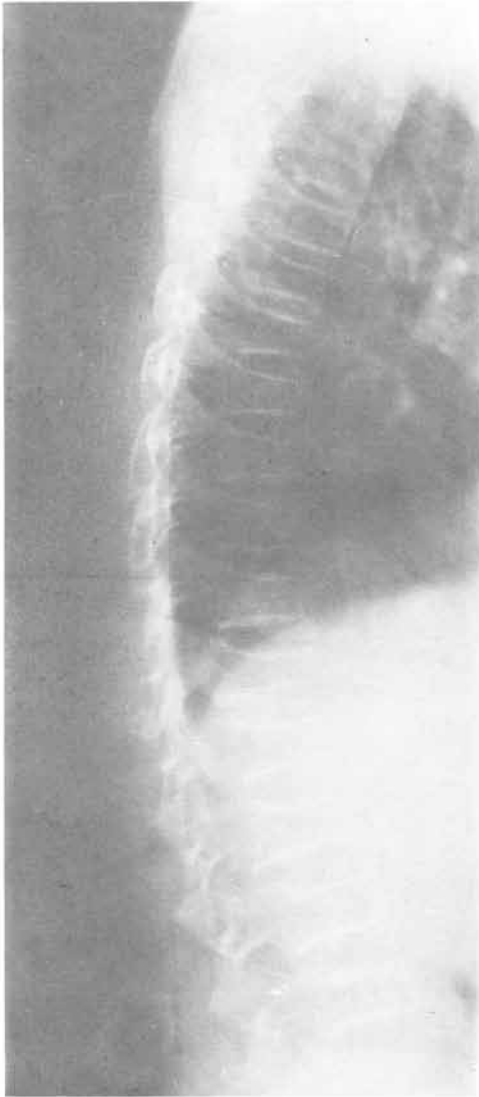


Fig. 2. Marked loss of bone density with vertebral collapse.

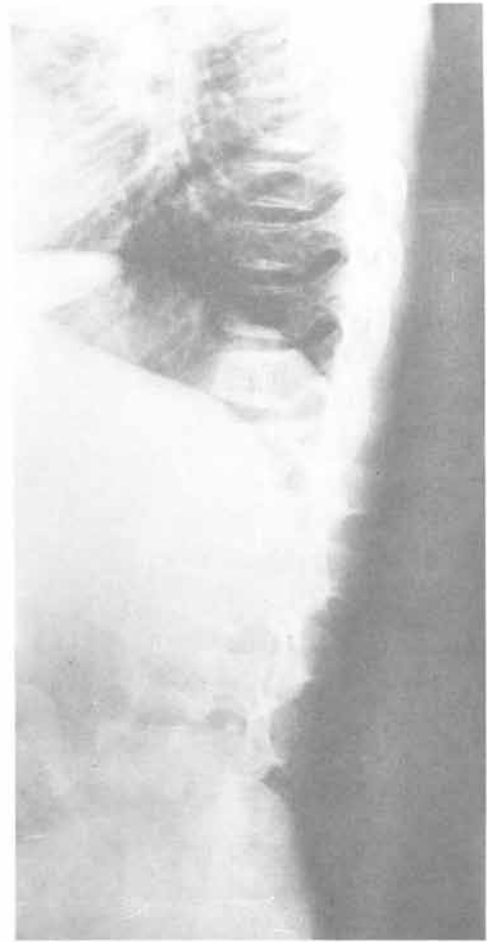

Fig. 3. Same patient as in Fig 2 after Chemotherapy and in remission.

Suture diastasis (Fig 4) was found in the skull of two children at presentation, in one there was papilloedema and evidence of CNS involvement. The other child had no neurological abnormality and normal CSF suggesting that the skull changes were due to bone involvement at the suture lines. Two patients developed suture diastasis at 10 and 20 months after presentation, both had evidence of CNS leukaemia and one developed narcolepsy. Further two patients with clinical signs of

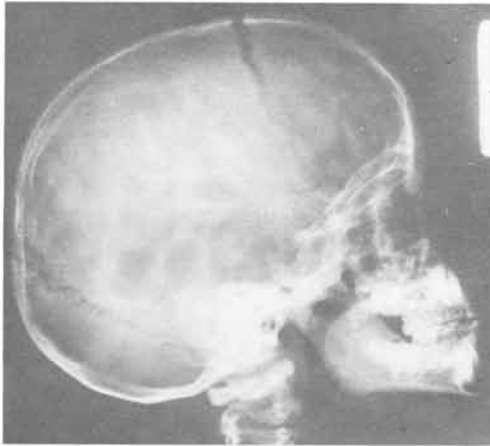


Fig. 4. Suture diastasis in leukaemia.

CNS involvement had normal sutures. A carotid angiogram was carried out in one child with left sided motor weakness who showed suture diastasis. A space occupying lesion was found in the right hemisphere but the diagnosis of acute leukaemia was made later when blast cells appeared in the peripheral blood.

Ewings type of bone sarcoma was considered in one child with bone pain and a localised area of multi-layered periosteal reaction in the mid-right tibia. (Fig 5). The peripheral blood film was normal and the possibility of neuroblastoma excluded. This child subsequently developed lymphadenopathy and splenomegaly, at which time the peripheral blood picture was one of acute leukaemia. A further destructive bone lesion appeared in the left upper femoral metaphysis. This child was alive at the time of review seven years later.

Growth disturbance is common in acute leukaemia, and was present in twelve of the twenty seven patients who had a full skeletal survey. A particular form not referred to previously is seen as vertical bands of coarse striation in the lower femoral shafts due to altered trabeculation, although these changes are sometimes en-




Fig. 5. Multilayered periosteal reaction due to leukaemia.

countered in normal children, the frequency of these in our series were quite significant (3 out of the 27 children who had a full skeletal survey) to be related to chance.

The patients with patchy metaphyseal destruction showed changes similar to those already described extensively in the literature. (Fig 6). One child, however, showed very large destructive areas not commonly seen in this series. (Fig 7). The more usual "moth-eaten" appearance was seen in twenty cases and makes the single largest group in this series.

Fractures are common in the presence of bone destruction. In this series four patients had fractures, in two there was obvious bone destruction at the site of fracture, in the other two, the fractures appeared not to be related to the leukaemia. One patient with knee pain developed a joint effusion but with no evidence of bone involvement. A child

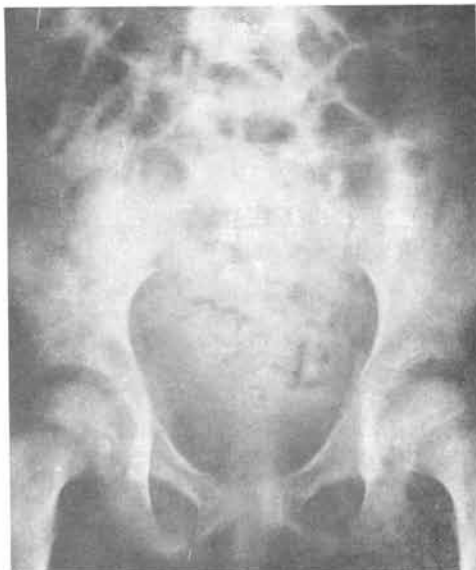

Fig. 6. Patchy destruction of pelvis with upper femoral metaphyseal lucencies.

who had extensive destructive bone lesion at presentation is alive and in complete remission, seven years after presentation and on careful correlation it was found that there was no obvious prognostic significance in the presence or absence of radiological evidence of bone destruction at presentation. The same lack of significance even applied to the severity of bone involvement at presentation. (Table 3).

DISCUSSION

Skeletal changes are common in children with acute leukaemia and may suggest the diagnosis before a more definite clinical picture emerges.^{2,3}

The general pattern of bone involvement in acute leukaemia has been recorded by several authors.^{4,5}

Studies have also described the metaphyseal lucencies as radiolucent zones some two to five cm. wide and parallel to the epiphyseal line, also as sub-cortical lesions in flat bones. This is one of the

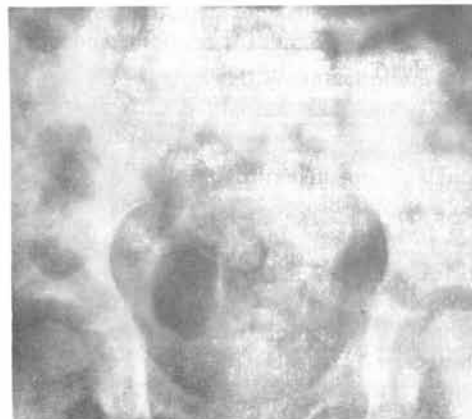

Fig. 7. Same patient as in Fig 6 "Blow out" and radiograph of the hip.

earliest radiological changes but is nonspecific and is also seen in scurvy, malnutrition and congenital lues, septicaemia, juvenile rheumatoid arthritis and neuroblastoma. The latter, apart from a different clinical presentation, is usually seen as a part of a more widespread pattern of bone destruction.^{6,7}

Bone pain was recorded in about half the patients in this series, it may be due to periosteal infiltration or to periosteal elevation by leukaemic tissue or to haemorrhage.⁸ Where there is no evidence of bone destruction pain may be due to the expanding hyper-plastic marrow.

Osteoporosis with secondary bone collapse will account for some instances of bone pain. Intramedullary pressure is raised in leukaemia^{10,11} and is raised further by the Valsalva manoeuvre. This may account for patients in whom there is bone pain without evidence of bone destruction.¹² However the Valsalva manoeuvre did not increase bone pain in one series of eighty-five patients. There is good correlation between the presence of periosteal reaction and bone pain but poor correlation with osteolytic areas and lucent metaphyseal bands.

Periosteal reaction has been discussed previously, and is closely related to bone pain.

Transverse lines of arrested growth in the metaphyses are commonly seen in children with acute leukaemia¹³ and are related to remission, relapse, infections, and to cytotoxic agents. These bands stand out even more clearly against the adjacent rarefield bone.

In children over two, multiple metaphyseal lucencies without other bone changes is highly suggestive of leukaemia.^{14,16} Slipping of the femoral and humeral capital epiphyses in association with metaphyseal leukaemia destruction is recorded. This may be due to infiltration and every recorded case has also shown patchy bone destruction and periosteal reaction as well. However slipping also occurs in other debilitating conditions.

Another early bone change in acute leukaemia is that of cortical erosions at the medial proximal aspects of the humeral and tibial shafts.¹⁵

Multiple osteolytic lesions are common early manifestations of acute leukaemia. These are usually less than five mms. diameter when first seen and are the single most characteristic lesion. The lesions are usually symmetrical and tend to coalasce. at this stage the appearances are similar to those found in neuroblastoma.

Diastasis of the skull sutures is due either to raised intracranial pressure due to leukaemic CNS deposits or to bone involvement in the edges of the vault bones as occurs in neuroblastoma.

Arthritis may precede the other manifestations of leukaemia by up to two years. Eventually fifteen per cent of patients will exhibit this symptom. In ninety per cent the lower limbs are the site of symptoms often bilateral and

symmetrical, ten per cent are non-articular. There are no radiological changes in forty per cent. Opportunistic infection is an alternative cause in leukaemia.

Presentation with or the lateral onset of arthralgia is recorded in acute leukaemia,¹⁷ the pathogenesis is obscure but may be due to the extension of metaphyseal periosteal involvement of the joint capsule with resultant effusion.

Bone infarcts are frequently demonstrated histologically but are rarely shown radiologically, unless necrosis is followed by bone destruction.

Paravertebral masses may be seen in leukaemia, due either to extramedullary hemopoiesis or to chloroma, an unusual manifestation of acute granulocytic leukaemia where tumoral deposits are found in the meninges, orbits, lymphnodes and skeleton.^{18,19}

Osteosclerosis is rarely a manifestation of leukaemia, the appearance of dense metaphyseal bands in children with leukaemia is similar to the well known changes associated with heavy metal poisoning. This change may be due to attenuation of enchondral bone formation by chemotherapy, the bands often become less dense with longer survival. They have also been reported in children in spontaneous remission, and in untreated patients. sclerotic lesions rarely appear independently and are usually associated with areas of bone destruction. The bone marrow can now be effectively investigated using M. R. I.⁹ Focal abnormalities such as seen in acute myelogenous leukaemia are readily identified as areas of reduced signal or T1 WSE and increased signal or T2 WSE or STIR sequences. However, diffuse marrow changes in acute lymphatic leukaemia does not produce readily discernible changes through chemical shift techniques and measurement of relaxation

time may be helpful in monitoring response to treatment.

REFERENCES

1. Aisner, M and Hoxie, T B., Bone and joint pain in leukaemia, simulating acute rheumatic fever and subacute bacterial endocarditis. *New England Medical Journal*. 1948; 238: 733.
2. Aur, R J A , Westbrook NW, Riggs, W. Jr., Childhood acute Lymphocytic leukaemia. *American Journal of Diseases of Childhood*. 1972; 124: 653.
3. Baty, J M , Vogt, E C. Bone changes of leukaemia in children. *American Journal of Roentgenology*. 1935; 34: 310.
4. Bichel, J, Arthralgic leukaemia in children. *Acta Haematologica* 1948; 1: 153.
5. Brunner, S, Gudbjorg, C E, Iverson T. Skeletal lesions in leukaemia in children. *acta Radiologica*. 1958; 49: 419.
6. Craves, L F R, & Copeland, M M, Changes of bone in leukaemias. *archives of Surgery*. 1935; 30: 639.
7. Dale, J H Jr, Leukaemia in childhood. Clinical and roentgenographic study of 72 cases, *Journal of Paediatrics*. 1949; 34: 421.
8. Hustu, H O , Pinker, D, Lymphosarcoma Hodgkins disease and leukaemia in bone, clinical orthopaedics and related research 1967; 52: 83.
9. Keslake R W, Paediatric Musculo skeleton M R I Clinical M.R. 1992; 4: 121.
10. Pear B L, Skeletal manifestations of the lymphomas and leukaemias. seminars in Roentgenology. 1947; 3: 229.
11. Petrakis, N L, Bone marrow pressure in leukaemic and non-leukaemic patients. *Journal of Clinical Investigation*. 1954; 33: 27.
12. Rosenfield, N S, McKintosh, S, Prospective Analysis of bone changes in treated childhood leukaemia. *Paediatric Radiology* 1977; 123: 413.
13. Silverman, F N, Skeletal lesions in leukaemia. Clinical and Roentgenographic observation in 103 infants and children with a review of literature. *American Journal of roentgenology*. 1948; 59: 819.
14. Silverstein, M N Kelly P J, Leukemia with ospteoarticular symptoms and signs. *Annals of Internal Medicine*. 1963; 59: 637.
15. Simons, C R , Thomas S H , Edwards B S, The osseus manifestations of leukaemia. *Radio-logical clinics of North America*, 1968; 6: 115.
16. Strauch, A, Acute Lymphatic leukaemia in early life. *American Journal Diseases of Childhood*. 1913; 5: 43.
17. Thoas L B, Forkner C E, frei E, Besse B E, and Stabenance, J R, The skeletal lesions of acute leukaemia. *Cancer*. 1961; 3: 608.
18. Wilson, J K V, The bone lesions of childhood leukaemia. A survey of 140 cases. *Radiology*, 1959; 72: 672.
19. Wolstein, M, Leukaemia in youn children. *American Journal Diseases of Childhood*. 1932; 72: 672.