

## THE INTERNAL MALE PSEUDOHERMAPHRODITE (HERNIA UTERIE INGUINALE)

M VIQAR AFRIDI AND ABID ASLAM AWAN

*Department of Surgery,  
Postgraduate Medical Institute,  
Lady Reading Hospital, Peshawar.*

### INTRODUCTION

Hermaphroditism is described as discrepancy between the morphology of gonad and external genitalia. A person may be a true or Pseudohermaphrodite. The true hermaphrodite possess both functioning ovaries and testicular tissues as ovary or testis or ovotestes. Pseudohermaphrodites possess features of both the sexes but the gonads are either that of male or female and the status of being a male or female is prefixed according to whether they have ovaries or testes.<sup>1</sup>

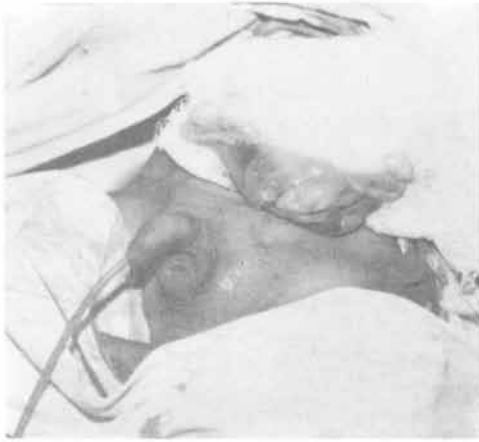A female pseudo-hermaphrodite is genotype xx and the gonades are ovaries but the external genitalia are virilized. Male Pseudohermaphrodite usually presents with small penis and bifid underdeveloped scrotum. The testis may be present or undescended. At times, male Pseudohermaphrodite presents with normal external appearances but possess remnants of mullarian ducts in the form of uterus and fallopian tubes and they may present through inguinal hernia as hernia uterie inguinale. Two such cases and its treatment are discussed.

### CASE NO. 1

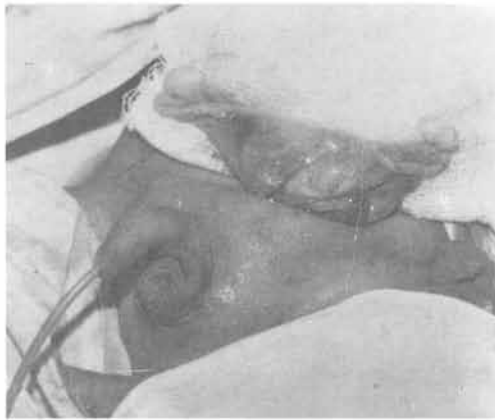
A child ten months old was presented to us with a left obstructed inguinal hernia. The mother said that

the swelling would disappear when the child was resting. The mother also said that there were no testis till the 40th day of birth, and then only left testicle appeared. On examination, the child was healthy looking with well developed penis and scrotum. There was no hypospadias. The left scrotum was tense and the hernia was irreducible as the child was crying and the scrotum was tender to touch. The right scrotum was empty and normally developed. The perineum and abdominal examination revealed no abnormality. The child was admitted to the ward and after necessary pre-op investigations he was operated under general anaesthesia.

The left inguinal hernia was explored through groin incision, the cord dissected to look for the hernial sac. It was a difficult dissection and during dissection sac was opened and the left testicle delivered in the wound. When the left testis was slightly pulled, the right testicle also came from the peritoneal cavity into the wound. Both the testis were normal looking and attached to these were purple looking fallopian tubes arising from a well developed uterus. The testis had normal epididymus and vas deference. See Photograph No. I and Photograph No. II. The uterus size corresponded with chronological age and had well developed



Photograph No. I



Photograph No. II

broad ligaments. Biopsy was taken from both testis and sent for histopathology. The left testis was fixed in the scrotum after dissecting the vas defference and cord structures from the flimsy peritoneal attachments. The right testis with the uterus and fallopian tube was left in the peritoneal cavity to be done at a later date. Post operatively the patient had uneventful recovery. The histology showed semineferous tubules lined with germinal epithelium consistent with Testicular tissue.

## CASE NO. 2

A 25 years old unmarried man presented to us with right reducible inguinal hernia and left undescended testis. On examination he was a young healthy looking Afridi of Kukikhail tribe. He had well developed external genitalia with reducible right inguinal hernia. The left testis was undescended and the left scrotum was normally developed. He had normal distribution of hair and the perineum was normal. Per rectal examination was also normal.

After routine pre-operative investigations the patient was operated. The right inguinal hernia was explored. When the inguinal canal was opened, the right testis was pulled out from the peritoneum into the wound. When slightly pulled, the left testis also came into the wound. When the two were spread they were connected to a well developed uterus with fallopian tubes with normal fimbriated ends attached to the testis. They were exactly like the photograph of the first case. The left testis with the uterus were excised. The right testis was fixed in the scrotum. The hernia was repaired and the wound was closed. The patient had uneventful post-operative recovery. Biopsy from the testis and uterus was taken and sent for histopathology.

Histopathology showed a well developed uterus, the wall of the uterus showed non-secretory endometrium and myometrium. Sections from the other solid glandular, tissue showed sheets of semineferous tubules lined by the germinal epithelial cells also showing spermatogenesis. Interstitial tissues were not remarkable. There was no evidence of malignancy in the sections examined. The opinion was Inguinal Mass Uterus and Testicular Tissue.

## DISCUSSION

In male foetus the testis develop by the 6-8 weeks of foetal life from the genital ridge under the influence of the Y-chromosome and Hy-Antigen.<sup>2</sup> The testis secrete testosterone which help the development of masculine structures and Wollfian duct, sertoli cells of the testis secrete Mullarian-inhibiting hormone (Josso-N).<sup>3</sup> This prevents the development of uterus and the Fallopian tubes (Joness-HW).<sup>4</sup> In male hermaphrodite, the external genitalia are more like that of a female. This is due to testicular feminization, end organ resistance, defective synthesis of testosterone and steroids and familial pseudohermaphroditism due to testis secreting oestrogens. In the internal male pseudohermaphrodite which is more common than female the external genitalia may be normal with no defect at all as noted in our two cases, yet both cases had well developed uterus and Fallopian tubes presented as hernia uterie inguinale.

In prepubertal children removal of testis would result in impotence. In one case we did not remove the testis. One was left in the peritoneal cavity for fixation at a later date and right testis fixed in the scrotum. In the second case we removed the undescended left testis along with the uterus and fixed the right testis in the scrotum after repair of the inguinal hernia. In cases where histology is reported malignant then there is no alternative but orchiectomy.

## REFERENCES

1. Cowadías A P, Hermaphrodite, the human intersex. London Heinemann 1964.
2. Donahoe P K, Crawford J D, Henderen W H. Pseudohermaphrodite. *J. Paediatric Surgery* 1977; 12: 1045.
3. Josso N, Danison W. *Surgery in infancy and childhood*, 3rd ed. Churchill Livingstone Edinburgh 1974.
4. Jones H W Jr, Scott W. *Hermaphroditism, genitalia and related endocrine disorder* 3rd ed. Williams and Wilkins, Company, Baltimore 1971.