

# CHOLEDOCHODUODENOSTOMY IN THE MANAGEMENT OF CHOLEDOCHOLITHIASIS

ATTA ULLAH JAN AND MUHAMMAD ARIF

*Department of Surgery,  
Postgraduate, Medical Institute,  
Lady Reading Hospital, Peshawar.*

## SUMMARY

Of the 2500 patients who had surgical intervention for benign biliary tract disease between 1977-1995, 385 (15.4%) had their common bile duct (CBD) explored and of these 275 had stones present (11.0%). Choledochoduodenostomy was done in 220 cases. There were 165 women and 55 men making ratio of 3:1. Age ranged between 22-80 years (mean 50 years) with maximum incidence in 5th and 6th decade. Morbidity was 2.2%. Mortality was nil in the series. "Sump" syndrome was not recorded in any case; however few nonspecific symptoms occurred in some cases which responded well to conservative treatment. Choledochoduodenostomy should be performed as primary procedure in management of CBD stones as it is safe and effective.

## INTRODUCTION

Management of common bile duct (CBD) stones remains controversial<sup>1,2</sup> especially with the introduction of new, less invasive technologies. However, in the North West Frontier Province (N.W.F.P) where these technologies are in infancy, Choledochoduodenostomy (CDD) is still the gold standard. The same is considered by other surgeons world over,<sup>1</sup> even in the era of Laparoscopic/Endoscopic surgery.

In the present series a study of 220 Choledochoduodenostomies (CDD) is presented. It includes clinical presentation, diagnosis, treatment and discussion in detail, excluding long term results.

## MATERIAL AND METHODS

The data was compiled from hospital record of Surgical "A" Unit Hayat Shaheed Teaching Hospital (July 1977 to June 1989) and Postgraduate Medical Institute, LRH, (July 1989 to June 1995) Peshawar. This duration extends over a period of eighteen years. A combined data is presented in this

article. A total of 2500 cases were operated for cholelithiasis. 385 patients had cholecystectomy and CBD exploration i.e. 15.4%. Out of these, 275(11%) had CBD stones. Amongst 275 cases 220, patients had choledochoduodenostomy and 55 patients underwent choledochotomy and T-Tube drainage (Table-I).

Youngest patient was 22 years old and eldest was 80 years, with average age of 50 years. There were 165 women and 55 men making sex ratio of 3:1.

## Diagnosis of Choledocholithiasis:

Flow chart used for the diagnosis of Choledocholithiasis (CDL) is given, (see Table-2)

## Treatment:

All cases presenting to us with choledocholithiasis (CDL) and upper abdominal pain were investigated according to the flow chart (Table-2)

Liver Function Test (L.F.T.) and Prothrombin Time (P.T.) were done in

TABLE - I  
 CHOLECYSTECTOMY AND COMMON BILE DUCT EXPLORATION

	Number	Percent
Cholecystectomy	2500	100%
Cholecystectomy & Common Bile Duct Exploration	385	15%
Common Bile Duct Stones present	275 (of 2500)	11.0%

cases of jaundice and the P.T. brought to normal pre-operatively by administration of Vit. K 10 mgm intravenously twice a day. If the patient was not diabetic and markedly jaundiced, intravenous Glucose infusion with Inj. Vit. C 500 mgm was administered twice daily. In early part of the study at Hayat Shaheed Teaching Hospital in all cases where Ultrasonogram ( US ) showed dilated bile ducts without any stone, Percutaneous Transhepatic Cholangiography (P.T.C) was done under cover of broad spectrum antibiotic (Inj. Kefzol 1 gm I.V 8 hourly or Rociphen 1 gm I.V Q.D). These antibiotics were also continued postoperatively, due to high incidence of positive bile cultures<sup>4</sup> in such cases. In this series P.T.C was helpful in 14 benign lesions of C.B.D i.e 11 cases of calculus and 3 cases of stricture CBD, all treated by CDD.<sup>7</sup>

In pre and post-operative phases good hydration was maintained to ensure urine out put and if required Mannitol was given to prevent renal shutdown.

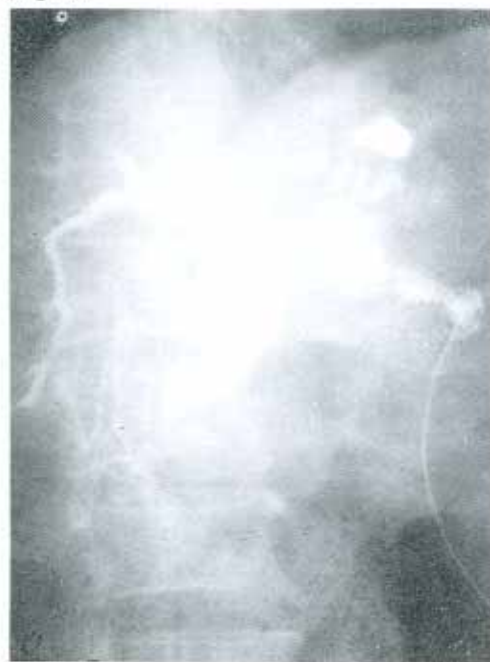#### Operative procedure of Choledochoduodenostomy (CDD):

Indications of CDD are of two types.<sup>16</sup>

1. Malignant Obstruction of CBD e.g carcinoma head of pancreas; carcinoma distal CBD.
2. Benign Obstruction of CBD.
  - a) Choledocholithiasis where we did this procedure in 220 cases.
  - b) Recurrent Choledocholithiasis.

- c) Retained hepatic and CBD stones.
- d) Recurrent stones after previous sphincterotomy.
- e) Extra-hepatic stricture of the bile duct.
- f) Intrabiliary rupture of Hydatid cyst.
- g) Duodenal diverticulum.

In our series the main indication was choledocholithiasis as primary problem. In 5 cases this procedure was performed for retained/missed bile duct stone (1.8%), which is also offered by Lagidakis NJ, as definitive solution to this problem<sup>1</sup> (Fig. 1).

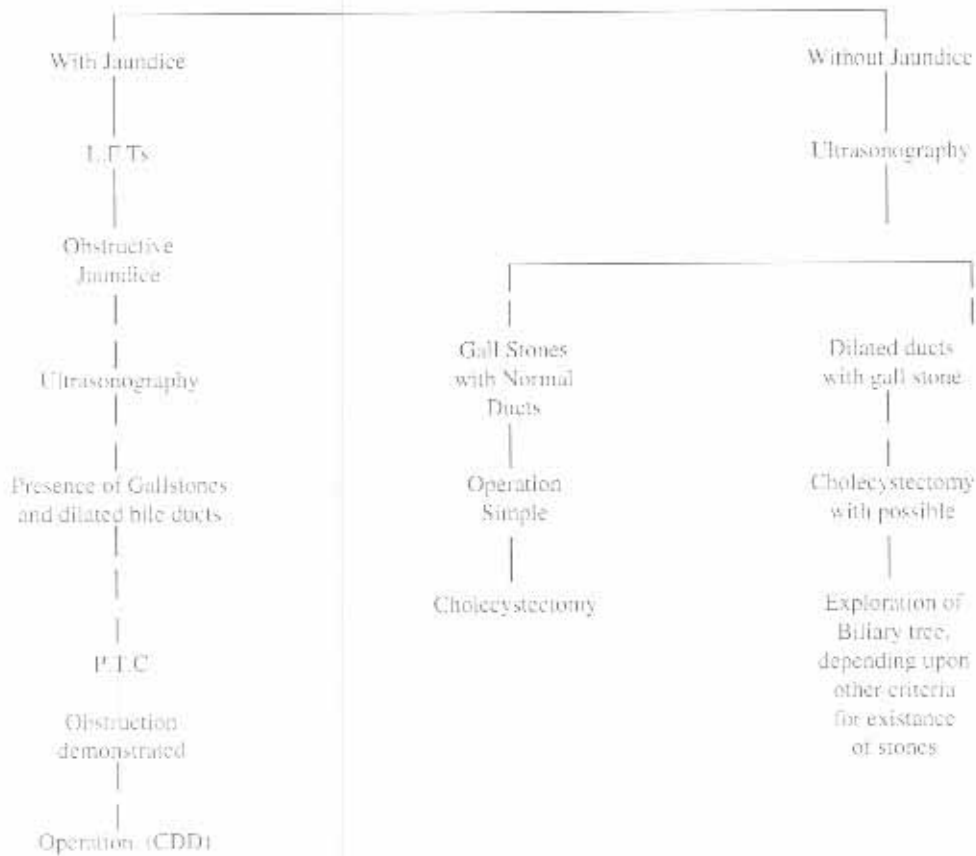


1. Technique of Choledochoduodenostomy.

TABLE-2

FLOW CHART FOR DIAGNOSIS OF CHOLEDOCHOLITHIASIS

Episode of upper abdominal pain/Right upper quadrant pain with vomiting, positive signs for clinical diagnosis of cholecystitis.

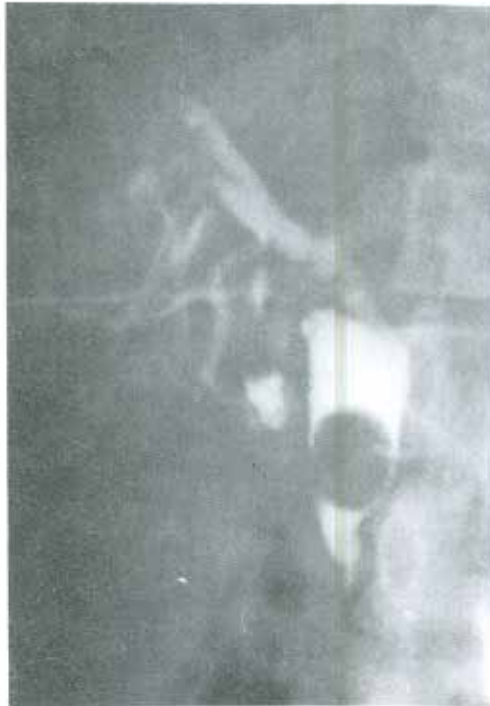

Procedure of Choledochoduodenostomy; (Fig. I)

In the average patient the CBD is dilated and thick walled and both these characteristics of CBD containing stones make the anastomosis easy to perform.

Before the anastomosis is made, the duodenum can be mobilised by process of Kocherisation to reduce tension on suture line. Longitudinal incision is made in the

CBD adjacent to duodenum as low as possible to reduce the distal blind stump. Two stay sutures are applied on either side of the incision in middle part so that when the sutures are pulled the incision become transversely placed somewhat similar to procedure of pyloroplasty of the Heineke-Mikulicz type. Incision along the long axis of duodenum is made and the posterior seromuscular, interrupted silk 3/0 sutures are placed. (Fig. II). The mucosa to



11- Photograph showing P.T.C of a patient having residual stone C.B.D. This patient had Choledocholithotomy and C.D.D.

mucosa full thickness sutures are applied continuous, with 2/0 catgut. The mucosal suture may be continued to anterior inner layer after locking at the corner. Anterior outer layer is stitched with 3/0 interrupted silk sutures. Sometimes few additional interrupted sutures with silk 3/0 or Chromic catgut 2/0 can be applied to reduce tension on suture line. Some other modifications have been mentioned in literature.<sup>12</sup>

## RESULTS

### (A) Presentation:

The following is a break down of presentation of 275 cases having CBD stones.

1. Jaundice 172 (62.5%)
2. Upper abdominal pain with nausea and vomiting 178(65.2%)

3. Recurrent attacks of pain with Intermittent Jaundice 35(12.7%)
4. External biliary fistula after drainage of anterior abdominal wall abscess 1 case (0.4%).

Rare presentation like weight loss and anorexia were not seen in this study.

### (B) Surgical procedures

- \* Total cases of Choelthiasis - 2500
- \* Number of patients requiring choledochotomy - 385 (15.4%)
- \* Number of patient with CBD stones - 275 (11.0%)
- \* Choledochotomy + T-Tube Drainage & clearance of CBD - 55 (2.2%)
- Choledochoduodenostomy - 220 (8.8%)
- \* Mortality - Nil (0%) in CDD
- \* Morbidity in CDD:
  - Leakage beside drainage tube - 5 (2.2%)
  - Which stopped in 3-7 days
- \* Morbidity in Choledochotomy + T-Tube in 10 cases (18.2)
  - a) Wound infection 3 cases
  - b) Leakage beside T-Tube 5 cases
  - c) Cholangitis 2 cases
- All patient recovered.
- \* Average stay in the Hospital.
  - Choledochostomy + T-Tube - 12 days
  - Choledochoduodenostomy - 6 days.

### (C) Complications of Choledochoduodenostomy

1. Leak from anastomotic site. (5 cases in this study 2.2%)

TABLE - 3

INCIDENCE OF CHOLEDOCHOTOMY AND CHOLEDOCHOLITHIASIS AND CHOLECYSTECTOMY IN VARIOUS SERIES COMPARED WITH OUR STUDY AT H.S.T.H. & P.G.M.I (LRH) SURGICAL-A- UNIT FROM JULY-1977 TO JUNE-1995.

Authors:	Cholecys- tectomy	CBDE%	CBDE% positive for stone	CLD. Chole- cystectomy %
Colcock et al (30)	1754	29	28	8
Meyer et al (31)	1193	26	44	12
Jolly et al (32)	1460	21	62	13
Kakos et al (33)	753	25	62	15
Way et al (34)	952	21	65	14
Mc Sherry et al (35)	7413	18	60	11
Duetsch et al (36)	2000	20.35	22.2	5.15
HSTH & PGMI/LRH (Jan-A.U) Jul-77 to June-95	2500	15	71	11

2. Haemorrhage from anastomotic site due to ulceration. (1 case).

## DISCUSSION

Peshawar is capital of NWFP and Hayat Shabeed Teaching Hospital and Postgraduate Medical Institute, Lady Reading Hospital are the two main Hospitals. There are seven surgical units which cater for patients from all over NWFP except Hazara Division which to certain extent is looked after by Ayub Medical College Hospital. The two teaching Institutions at Peshawar also receive patients from neighbouring areas of Afghanistan and intervening tribal belt. Health Services in peripheral hospitals, and Basic Health Units (BHUs) are primitive and therefore much of surgery for Cholelithiasis is performed in these two teaching hospitals at Peshawar.

Detection and management of CDL had been and still a challenge to the surgeon. (Table-II)

## Natural History of Choledocholithiasis

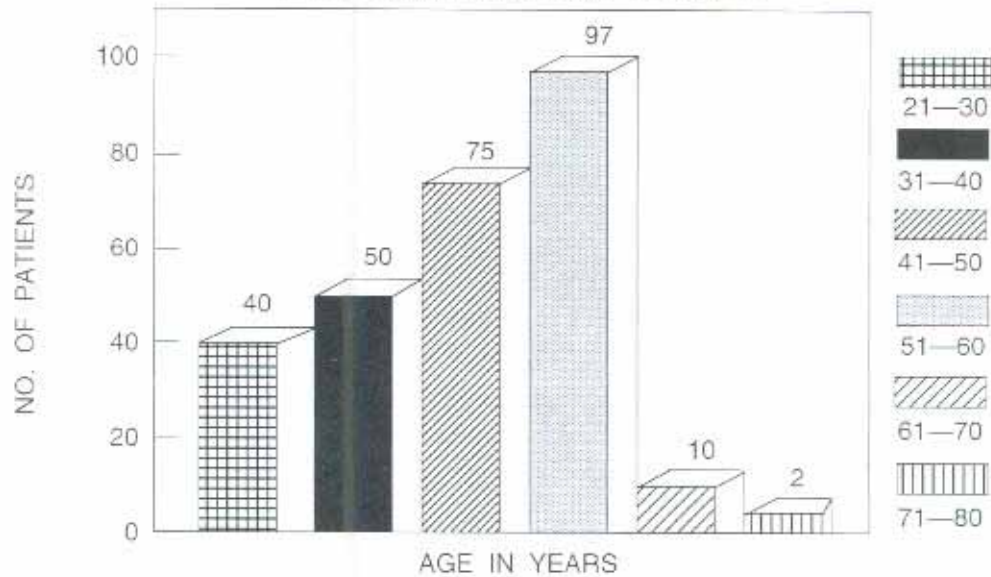
The following facts have been established:

1. Most common bile duct stones migrate from gall bladder. Several observations seem to support this fact. Firstly CBD stones are present in approximately 12% of patients with gall bladder stones at time of cholecystectomy and these stones usually resemble gall-bladder stones in type and morphology.<sup>19</sup>
2. Secondly CBD stones are uncommon in absence of gall-bladder stones.

Primary ductal stones do occur and it is well documented that in patients with agenesis of gall-bladder, common bile duct stone may be formed. In Gerwig's study of 57 patients with gall-bladder agenesis who had biliary symptoms, 53% had CBD stones.<sup>22</sup> Wilson and Detrick reported 25-50% incidence of CDL in patient with agenesis of gall bladder at surgery.<sup>23</sup> Primary

TABLE 4

## AGE WISE DISTRIBUTION OF 275 PATIENTS WITH COMMON-DUCT STONES



ductal stones, are also formed in cholecystectomised animals.<sup>21</sup>

The association of stasis, infection and stone formation in the common bile duct is well recognised in human being. Primary duct stones have different form and composition, often being soft and friable or consisting of mud like mixture with brown pigments.<sup>22</sup>

Common bile duct stones may be asymptomatic. In a large autopsy series of 1000 case, Crump found that 24% of cases with cholelithiasis had also stones in the biliary ducts and this proportion was independent of age.<sup>23</sup>

Crump also noted that the prevalence of gall stone increase with age and so the number of patient with CBD stone also increase with age (Table-IV). In an operative series where gall stones were presumably symptomatic, the prevalence of choledocholithiasis was 6% in younger patients but rise to 33% in those over 80 years of age. Combining the above data

suggest that CBD stones are not only present in elderly but a far greater proportion is symptomatic. In our series the incidence of CBD stones has been 11.5% which compare well with others (Table-II).

In this series all cases had stones in gall bladder and therefore appears to have migrated from gall bladder. The maximum incidence has been recorded in 5th and 6th decade (Table-IV). The incidence of stone CBD has been low in earlier and later age groups. In those patients with long standing histories and grossly dilated ducts, one could encounter soft stone and mud like structure resembling primary stones which could have formed as a result of stasis.

#### Diagnosis

Several studies have attempted to evaluate the existence of Choledocholithiasis on the basis of symptoms, blood biochemistry and ultrasound examination. The clinical symptoms of abdominal pain, rigor and jaundice almost always indicate the presence of common bile duct stone.<sup>24</sup> In this

series incidence of such cases were 7 out of 20 patients who were having rigors with jaundice, turned out to have CBD stones. Vast majority of patients with CBD stones do not have typical Charcot Triad.<sup>27</sup> This has been the case in our study. Patient who are not obviously jaundiced, CBD greater than 12mm in diameter plus either raised Alkalinephosphatase, minimally raised Bilirubin or history of jaundice gave 90-100% predictive value of presence of CBD stones.<sup>8</sup>

Lacaine et al<sup>26</sup> measured CBD with pre operative Ultrasound scan while in our series before the introduction of ultrasound in Peshawar, the size of CBD was assessed intraoperatively.

It is important to note that CBD alone (more than 20mm diameter) was an unreliable indicator of CBD stones. This may be understood from Lagidakis experience who found that in addition to stone CBD dilatation depends on age, previous biliary surgery, biliary infection and long history.<sup>27</sup> He found CBD stones in 93% of patients with CBD diameter of more than 15mm, but 6% with CBD stones had a normal diameter duct. Nevertheless, the definition of CBD dilatation is confusing when the normal diameter can be as little as 6mm.

The ability to measure the duct diameter by ultrasound is excellent and ever since its introduction we are relying on this examination in defining our strategies for management of CDL.

Ultrasound examination by itself is not a highly reliable means of detecting CBD stones pre-operatively.<sup>4</sup> Detection rate was 15% in patients who were subsequently found to have CBD stones.<sup>28,29</sup> In jaundiced patients this figure rises to 53%<sup>30</sup> but is still too low to make ultrasound of real value in correct prediction of CBD stones.

Experience with C.T. Scan indicates that it is also accurate in diagnosing biliary

dilation but like ultrasound is rather less successful in demonstrating C.B.D stones.<sup>17</sup>

In non-jaundiced patient pre-operative duct visualisation with E.R.C.P. or P.T.C. is not performed routinely as both the techniques are invasive with mortality of 2% and 5% respectively. Stones can be identified as per operative cholangiography. Their main use is in patients with obstructive jaundice to establish the cause and site of obstruction. There is some evidence that E.R.C.P. and P.T.C. can be avoided even in jaundiced patient, as good quality ultrasound examination showing a dilated CBD and small gall bladder containing stones is probably sufficient to diagnose calculus C.B.D obstruction.<sup>31</sup> However when ultrasound does not show these typical features for any reason, E.R.C.P. and P.T.C. become necessary.<sup>17</sup> In our series in 40% of patients we have utilised only the clinical criteria already mentioned in predicting stones in C.B.D. P.T.C. was done in 62 jaundiced patient in which 14 patients had benign biliary tract lesion i.e. 11 C.B.D. stones & 3 cases of stricture C.B.D. (post-operative). All were treated by C.D.D.<sup>1</sup> In 60% patients we combined clinical criteria with ultrasonography and thereby were able to reduce the incidence of negative exploration.

#### Diagnosis of CBD Stones at Operation

We have already seen that duct dilatation alone is unreliable indication of CBD stones and palpation of the duct will often miss a small stone as well as intrahepatic stones. Most surgeons perform cholangiography routinely as part of cholecystectomy. Routine use of the technique reduces the number of retained stone and also decrease the number of negative CBD exploration.<sup>17</sup>

Cholangiography criteria for exploration of CBD vary from centre to centre, but there is considerable evidence that over exploration rather than under exploration

takes place. Most series report that 25% of patients undergoing cholecystectomy will have surgical exploration of the CBD but stones are found only in 60% of these patients,<sup>11</sup> (see table - I) Hauer-Jensen et al advise Intra-operative cholangiography, when clinical criteria suggest the presence of CBD stone or to clarify duct anatomy.<sup>12</sup> The incidence of retained stones in those undergoing common bile duct exploration varies between 1-10% with average of 4.3%,<sup>13</sup> and this usually occurs in patients in whom stones from common bile duct are recovered. In our series we did not perform operative cholangiography and relied on criteria already mentioned. The CBD was explored in 15.4% of patients (who had undergone cholecystectomy) and the stones were found in 72% of the patients of choledochotomy. This compares very well with the available data.

The incidence of retained stones in our series is 2.4%. At present there is little evidence to define which criteria other than palpable stones, obstructive jaundice, filling defect on cholangiography or operative ultrasonography should be used to explore the common bile duct. Recently endoscopic sonography has given promising results in the diagnosis of CDL.<sup>14</sup>

#### Immediate Post Exploratory Evaluation of CBD

Following exploration of CBD many surgeons wish to check duct clearance by either post-exploratory T-Tube cholangiography or choledochoscopy. The main drawback in former is difficulty in obtaining a satisfactory cholangiogram. Air bubble is a common problem and the contrast often does not enter the duodenum after instrumentation of ampulla.

The alternative method of visualising the duct after exploration is choledochoscopy using flexible instrument. There are several consistent reports showing that post-exploratory choledochoscopy virtually

eliminates retained stones. Recently Morris et al advocate use of Ultra-thin fiberoptic endoscopy.<sup>15</sup>

#### Treatment

A variety of methods and techniques have been described for management of choledocholithiasis; each has its advocates, philosophy, advantages and potential drawbacks.<sup>16</sup> In our series 55 cases of CBD stones were treated with T-Tube choledochotomy after exploration of CBD. All these patients underwent post-operative T-Tube cholangiography. Five patients had retained calculi, this incidence of 1.87% and required second operation. Tritapepe has used non invasive treatment for retained bile duct stones in patients with T-Tube in situ with saline wash out after intravenous Cerulitide,<sup>17</sup> but we have no such experience. In view of 18.2% complication rate in T-Tube drainage, we have preferred internal drainage of the CBD. Two standard procedures commonly performed,<sup>18</sup> are:

1. Choledochoduodenostomy.
2. Transduodenal Sphincteroplasty

Choledochoduodenostomy is popular operation in Europe, South America and in Socialist countries ever since it was first reported by Riedel in Berlin in 1892.<sup>19</sup>

In 1969 Madden's report aroused new interest as he recommended CDD for prophylaxis and treatment of residual stones of C.B.D.<sup>20</sup> and it still continues to enjoy an important role in management of CDL.

The procedure did not receive general acceptance by surgeons in United States, the objection they raised to it was ascending cholangitis as an inevitable operative complication. However, the belief is false as neither Madden et al nor the collective experience of others have this problem.<sup>21</sup>

Cholangitis may occur as complication of C.D.D but it is believed to be related to



obstruction of stoma rather than reflux of duodenal contents into biliary tree, therefore it should be called descending cholangitis rather than ascending cholangitis.<sup>9</sup> In the only prospective trial of the two procedures, Choledochoduodenostomy was considerably better.<sup>48</sup> We have applied the policy of internal drainage to all patients in our unit undergoing choledochotomy, because of the therapeutic & prophylactic effectiveness even in the era of Endoscopic papillotomy & Biliary Lithotripsy. In this series 220 patients for choledochotomy have been treated with Choledochoduodenostomy (C.D.D). Bile leak occurred in 3 cases (2.2%) which stopped in a week's time. No other post-operative complication was encountered. Over a period of time 10 patients reported with mild dyspeptic symptoms which responded to conservative treatment.

I recommend that we should continue to utilise clinical criteria along with ultrasound assessment of the size of C.B.D. as pre-operative predicting factor<sup>49</sup> and corroborate these criteria with intra-operative assessment of C.B.D. by inspection, palpation and ultrasonography in suspicious case as indication for exploration of C.B.D. Post exploratory check of the C.B.D. to assess the clearance is best done by intraoperative cholangiography.<sup>35</sup> We like Baker<sup>1</sup> and so many others think that the best way to avoid recurrence of stones, reduce the morbidity and shorten the hospital stay is to perform choledochoduodenostomy as method of choice rather than external drainage.

## CONCLUSION

Choledocholithiasis may be asymptomatic but may become symptomatic and can cause life threatening complications. We presented our experience in treating 220 cases of choledocholithiasis by choledochoduodenostomy and results of the procedure in our series are at par with

widely published past and most recent international series.

The operation of Choledochoduodenostomy has been adopted as procedure of choice at primary operation for C.D.L and for prevention of retained stones.

## REFERENCES

1. Pitt HA. Role of Open Choledochotomy in the Treatment of Choledocholithiasis. *Am J Surg* 1993; 165: 483.
2. Anderberg B, Bolin S, Henman R, et al. "Choledochoduodenostomy for Choledocholithiasis. Indications and Functional results. *Acta Chir Scand.* 1984; 150(1): 75.
3. Lagidakis NJ. Surgical approach to post-cholecystectomy Choledocholithiasis. *Arch Surg* 1982; 117(4): 481.
4. Yaqin H, Sultan G. "The results of culture of Gall Bladder bile and gall stones. *J.P.M.A.* 1978; 28: 31.
5. Jan AU, Zaman Q, Mohyuddin QK. "Use of fine needle P.T.C. in diagnosis of Jaundice in Surgical Practice. *J.P.M.I* 1990; 4: 1:47.
6. Anciaux ML, Pelletier G, Attali P. Prospective study of clinical & biochemical features of symptomatic Choledocholithiasis. *Dis: Dis-Sci* 1986; 31(5):449.
7. Vernava. Pancreatitis after Biliary tract Surgery. *Arch Surg* 1987; 122: 575.
8. Wagner HE, Barbier P. Reoperation on Biliary tract System for benign disorder is still indicated. *Surg Gynecol & Obstet* 1987; 164: 57.
9. Gabrielsen K, Sondenö K, Halversen L, et al. Massive Hemobilia in a patient with residual stone after Choledochoduodenostomy; case report, treatment with endoscopic papillotomy. *Acta Chir Scand* 1986; 152:387.
10. Lennon GM, Browne R, Watson RG, O'Conner J. Gall stone ileus following Cholecystectomy and side to side Choledochoduodenostomy. *Ir J Med Sci* 1990; 159(912): 287.

11. Fischer MJ. Liver abscess. Successful treatment with Choledochoduodenostomy. *South Med J.* 1990; 87(2): 253.
12. Colcock BP, Percy B. Exploration of Common Bile Duct. *Surg Gynecol & Obst.* 1964; 118: 20.
13. Jolly PC, Baker JW, Schmidt HM, et al. Operative Cholangiography A case for its routine use. *Ann Surg.* 1972; 104: 484.
14. Kakos GS, Tompkins RK, Turnipseed W, et al. Operative Cholangiography during routine cholecystectomy. *Arch Surg* 1972; 104: 484.
15. Way LW, Admirand WH, Dumphy JE. Management of Choledocholithiasis *Ann Surg* 1972; 176: 347.
16. Mc Sherry CK, Green F. The Incidence and cause of death following surgery for non malignant biliary tract disease. *Ann Surg* 1980; 191: 271.
17. Deutsch A A, Nudelman I, Gutman H. Choledochoduodenostomy an important surgical tool in the management of C.B.D stones. A review of 126 cases. *Eur J Surg* 1991; 157(9): 531.
18. Bell Betson LL, Doty JE. Pathogenesis and Management of Choledocholithiasis; *Surg Clin N Am* 1981; 61: 893
19. Blenn F, Beitar. Choledocholithiasis demonstrated at 586 operations. *Surg Gynecol & Obstet* 1964; 118: 499.
20. Gerwig WH, Countrymen LK, Comez AC. Congenital absence of gall bladder and cystic duct. *Ann Surg* 1961; 153: 113.
21. Tsou-Hsin C, Liu CH. A new method for biliary tract reconstruction for primary bile duct stones. *Arch Surg* 1986; 122: 720.
22. Wilson JE, Dietrick JE. Agenesis of Gall Bladder: a case report and Familial Investigation. *Surg* 1986; 99(1): 106.
23. Carey MC. Pathogenesis of Gall Stones. *Am J Surg* 1993; 165: 410.
24. Crump C. Incidence of Gall Stones with Gall Bladder disease surgery. *Gynecol and Obst* 1931; 53: 447. Quoted from Johnson AGI and Hoskin SW. "Appraisal of Management of Bile Duct Stones. *Br J Surg* 1987; 74: 55.
25. Berk JE. Choledocholithiasis. *Am J Surg* 1941; 55: 96. Quoted from, Johnson AG, Hosking SW. Appraisal of management of Common Bile Duct Stones. *Br. J Surg* 1987; 74: 55.
26. Lacaine F, Corlette MB, Bismuth H. Pre operative evaluation of the risk of Common Bile J Duct Stones. *Arch Surg* 1980; 115: 1114.
27. Lygidakis NJ. The incidence and significance of Common Bile Ducts dilation in biliary calculus disease. *World J Surg* 1984; 8: 327.
28. Cooperaberg PL. High resolution real time Ultrasound in the evaluation of normal and obstructed biliary tract. *Clin Radio* 1978; 129: 447.
29. Vallon AG, Less WR, Cotton PB, Grey Scale Ultrasonography in cholestatic jaundice. *Gut* 1979; 20: 51.
30. Pedrose CS, Casanova R, Rodriguez R. Computed Tomography in Obstructive Jaundice. *Radiol* 1981; 139: 727.
31. Cotton PB. Endoscopic Retrograde Cholangiopancreatography (ERCP). *Gut* 1977; 81: 316.
32. Eyre, Brook JA, Ross B, Jones AG. Should Surgeon operate on the evidence of Ultrasound alone in jaundiced patients? *Br J Surg* 1983; 70: 587.
33. Jeffrey RB, Federle MP, Lani FC, et al. Computed Tomography of C.D.L. *AJR/Am J Roentgenology* 1984; 143(5): 949.
34. Laing FC, Jeffrey RB. Choledocholithiasis & Cystic duct Obstruction Difficult Ultrasound Diagnosis. *Radiology* 1983; 146 (2): 475.
35. Parukkar SG, Mc Namara MP. Ultrasonography of Choledocholithiasis *J Ultrasound Med* 1983; 2(9): 395.
36. Mitchell SA, Jacyna MR, Chadwick S. Common Bile Duct Stones: a controversy revisited. *Br J Surg* 1993; 80(6): 759.

37. Wang TA, Yue CH, Wang JJ, et al. Endoscopic approach in diagnosis of Obstructive Jaundice with special reference to Endoscopic Retrograde Cholangiography. *J Formos Med Assoc* 1992; 91(2): 164.
38. Hauer Jensen M, Karsen R, Nygard K, et al. Prospective Randomised Study of routine Intraoperative Cholangiography during open cholecystectomy, long term follow up & multivariate analysis of predictors of choledocholithiasis. *Surg* 1993; 113 (3): 318.
39. Glen F. Trends. Surgical treatment of Calculus disease of biliary tree. *Surg Gynecol & Obstet*. 1975; 140: 877.
40. Myenberger C, Bertschinger P, Wirth HP. Dilatation of C.B.D. What does Endoscopic Sonography contribute *Schweiz Med Wochenschr* 1994; 124 (15): 642
41. Morris DL, Harrison J. "Operative Cholelithoscopes via the cystic duct. a pilot study with ultrathin fiberoptic endoscope." *Br J Surg* 1987; 74(6): 613.
42. Otomi Y, Tanaka Y, Goto K, et al. Extracorporeal Shock Wave Lithotripsy of Choledocholithiasis. *Hippon Geka Gakkai Zasshi* 1992; 93(9): 1123.
43. Tritapepe R, Padova C, Padova F. Non Invasive Treatment for retained common bile duct stones. in a patient with T-Tube in situ: Salin wash out after intravenous Ceruletide. *Br J Surg* 1988; 75: 144.
44. Ramirez P, Parrilla P, Bueno FS, et al. Choledochoduodenostomy, Sphincterotomy in the treatment of Choledocholithiasis. *Br J Surg* 1994; 81(1): 121.
45. Reidel BMCL. Erfahrungen Uber Die Gallensteinkrankheit Mit Und Ohne Icterus. Berlin. Hrschwald, 1982, p-116. Obtained from *Surg Clin N Am*, 1973; 53(5): 1133.
46. John LM, et al. The nature and surgical significance of Common Bile Duct stones. *Surg Gynecol & Obstet* 1968; 162(1): 328.
47. Medden JL, Chun JY, Kandalafi S, et al. Choledochoduodenostomy An unjustly maligned Surgical procedure. *Am J Surg* 1970; 119: 45.
48. Lagidakis NJ. Perspective randomised study of recurrent Choledocholithiasis. *Surg Gynecol Obstet* 1982; 155:679.
49. Taylor TV. Prediction of Choledocholithiasis using a pocket microcomputer. *Br J Surg* 1988; 75(2): 138.
50. Thompson JE, Bennion RS. The role of endoscopy of Biliary Tract in assessing the function of ampula of Vater. *Surg Gynecol & Obstet* 1987; 165: 13.
51. Baker AR, Neoptolemos JP. Choledochoduodenostomy, Transduodenal Sphincteroplasty & Sphincterotomy for calculi of Common Bile Duct. *Surg Gynecol Obstet* 1987; 164(3): 245.
52. Roberi OG. The case for selective cholangiography. *The Am J Surg* 1988; 155: 540.