

SURGICAL MANAGEMENT OF LUMBAR INTERVERTEBRAL DISC HERNIATION

MOHAMMAD ILYAS, AZAZ ALI SHAH AND MOHAMMAD TARIQ KHAN

*Department of Neuro Surgery,
Postgraduate Medical Institute,
Lady Reading Hospital, Peshawar.*

SUMMARY

Two hundred patients of prolapsed intervertebral disc who were not responding to conservative treatment were selected for surgery. The age, sex, signs and symptoms of the patients were noted. All the patients were assessed clinically and confirmed with myelogram or CT scan of the affected levels of spine. There were 120 male and 80 female patients. The disease is common between 20-40 years. Usually two levels L4-5 and L5-S1 are affected more often than others. In two third of the patients the results were good to excellent. The best results were found in those patient of sciatica who presented initially with leg pain. Associated spinal stenosis with intervertebral disc herniation is the important finding noted in one third of the patients. Decompression laminectomy with discectomy has the advantage that prolapsed disc can be removed bilaterally and simultaneously decompression of the canal can be carried out if it exists.

INTRODUCTION

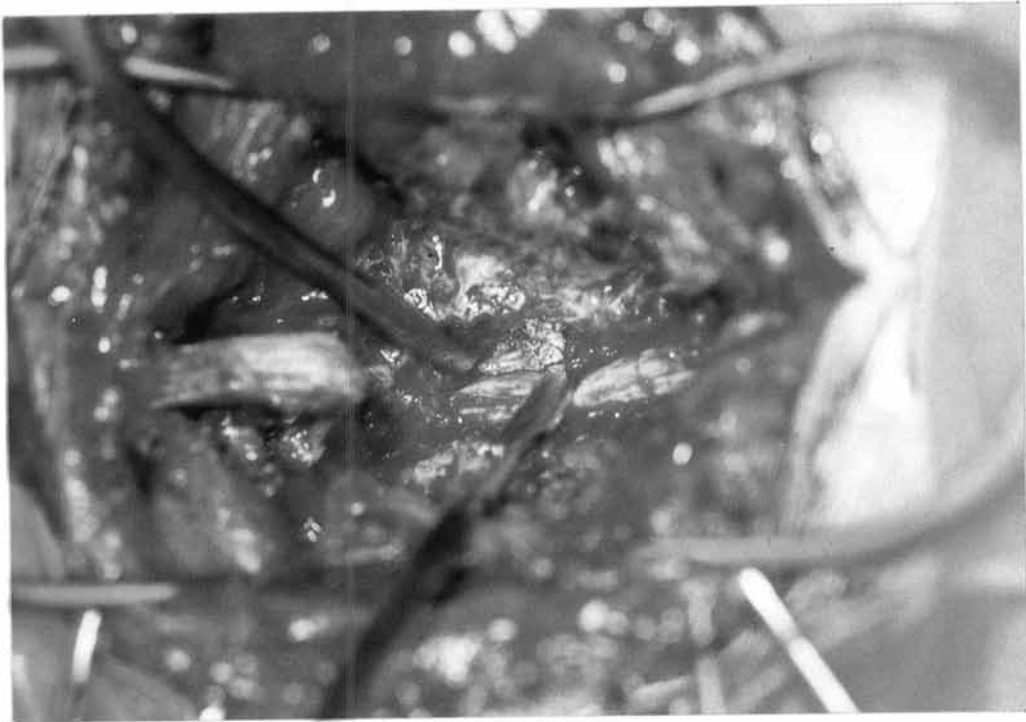The prolapsed intervertebral disc is the main source of low backache and radiating leg pain along the course of sciatic nerve. Treatment of lumbar intervertebral disc herniation starts with conservative management. It consist of limited physical activity and partial to complete rest, back exercises and NSAID which relieve sciatica in many cases. Two hundred patients of prolapsed intervertebral disc who were not responding to medical conservative treatment were selected for surgery. The surgical procedure adopted was standard lumber laminectomy with discectomy. The advantage of this procedure is that decompression of the spinal canal is carried out along with removal of herniated disc. Laminectomy with discectomy is considered as the procedure of choice against which all other procedures can be judged because of high success rate over many years.² Other procedures used to surgically treat lumbar

disc herniation include limited discectomy or micro-discectomy. The majority of patients presenting to us also have associated spinal stenosis due to geographical and socio-economical factors prevailing in this province, hence the standard laminectomy with discectomy provides better relief.

MATERIAL AND METHODS

Two hundred patients of intervertebral disc herniation were selected who underwent lumbar laminectomy with discectomy during the year 1993 and 1994. Age and sex, signs and symptoms of the patients were noted.

All the patients were assessed clinically with accurate localization of affected intervertebral disc levels. These patients were investigated with myelogram or C.T. of spine and correlated with the clinical assessment. The operative procedure adopted was lumbar laminectomy with discectomy.



The complications were also noted. Post operative follow up was for one year.

Surgical Procedure

Lumbar laminectomy with discectomy

The operative procedure is performed under general anaesthesia with the patient in prone position. A midline skin incision is centered over the pathologic disc space. The paraspinal muscles are separated with sharp subperiosteal dissection. The laminae are exposed laterally and the sacrum is identified for localization. The spinous process and the laminae of the effected level are removed with a bone rongeur. The ligamentum flavum is separated from the underlying dural canal by placing a piece of gauze and cut with a sharp knife and removed with a kerrison rongeur. Likewise the ligamentum flavum is removed from sides; extreme care is taken to avoid injury to the nerve root. Lumbar laminectomy with discectomy is an established procedure first performed in 1934.⁶ The articular facets

are preserved but in some cases of lateral herniation or associated stenosis removal of facet may be indicated.⁷

After removing the ligamentum flavum, the spinal canal is entered over the lateral edge of the dura and effected nerve root. The dural sheath is carefully separated from the herniated disc with cottoned paty to expose the effected nerve root which is retracted medially with the dural retractor. Sometimes a large sequestered fragment of disc lying in the axilla between the nerve root and the dura is removed first before the nerve root is mobilized. The disc is removed with pituitary rongeur under direct vision to avoid injury, to the retracted nerve root.

The pathologic disc is removed from both the sides in small pieces as much as possible but the entire disc material is not removed. Bleeding from the veins are controlled with gelfoam. The self retaining retractors are opened and any bleeding from the muscles is controlled with electrocoagulation. The muscles, fascia, subcutaneous and skin are closed layer by layer.

RESULTS

Two hundred patients with low backache and radicular pain in the legs either unilateral or bilateral were selected for surgery. They were treated in the Neurosurgery Department Postgraduate Medical Institute, Lady Reading Hospital, Peshawar during 1993 and 1994.

These patients were assessed clinically. The primary indication for surgery is positive straight leg raising sign. Other supportive findings included sensory deficit, muscle weakness and reflex abnormalities corresponding to the involved nerve root. The other causes of low backache e.g neoplastic lesions, infections, fractures, metabolic diseases such as osteoporosis were excluded.

These patients with suspected herniated disc were evaluated with myelogram or with CT scanning. These patients underwent surgery and the procedure adopted was standard laminectomy.

These patients were followed up for one year and the results are as below. There were 120 Male (60%) and 80 Female (40%) (Table I). Prolapsed intervertebral Disc herniation was common between 20 and 40 years, with less occurrence during early or late years (Table II). Prolapsed intervertebral disc herniation was common at L4-L5 and L5-S1; in 180 patients these levels were explored. (Table III).

In 30 (15%) of patients the prolapse intervertebral discs were found at two levels. Associated spinal stenosis at one or two segments along with prolapse intervertebral disc herniation was found in sixty patients.

Out of two hundred patients in 155 (77.5%) patients, the operative results were good to excellent. (Table IV). Patients operated for lumbar laminectomy with discectomy with predominant leg pain showed best results. Out of remaining 45 patients, 25(12.5%) patients were improved. These patients showed marked

Table No. 1
SEX DISTRIBUTION

Total Number of patients operated = 200

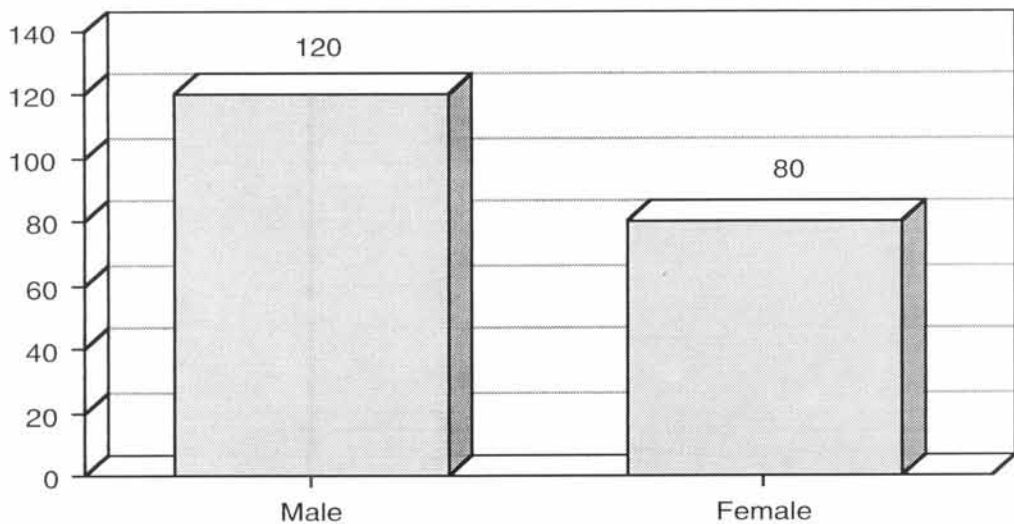
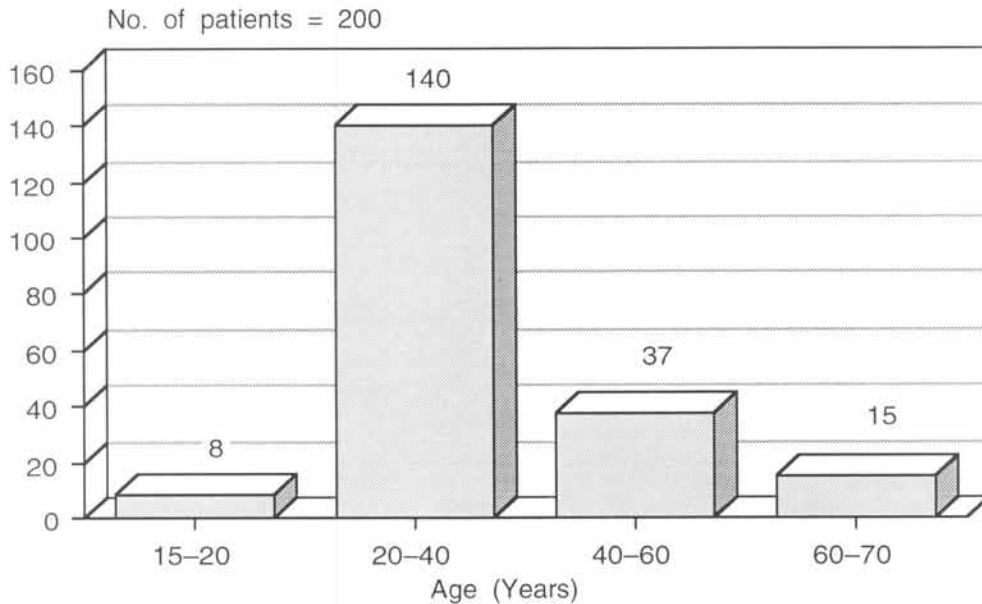


Table No. 2
AGE DISTRIBUTION

Commonest age group operated is between 20–40 years



resolution in back pain and leg pain. The remaining twenty (10%) patients did not show complete improvement. The back pain still persisted. The poorest results were found in patients who had mainly back pain while the best results were found in patients who presented initially with leg pain.

Of sixty patients who had only leg pain at initial examination 58 (96.6%) were found to have extruded fragments, of 120 patients with predominantly back pain over leg pain 80(66.6%) were found to have an extruded fragment. In twenty patients with greater back pain over leg pain only two patients were found to have extruded fragment. It was observed that patients with extruded fragment had a significantly higher proportion of leg pain and these patients showed better results. Included in the series were 8 patients of cauda equina syndrome, who required early operative intervention. The neurological outcome in these patients

was improved. They achieved independent ambulation and urinary control with unsatisfactory sexual functions.

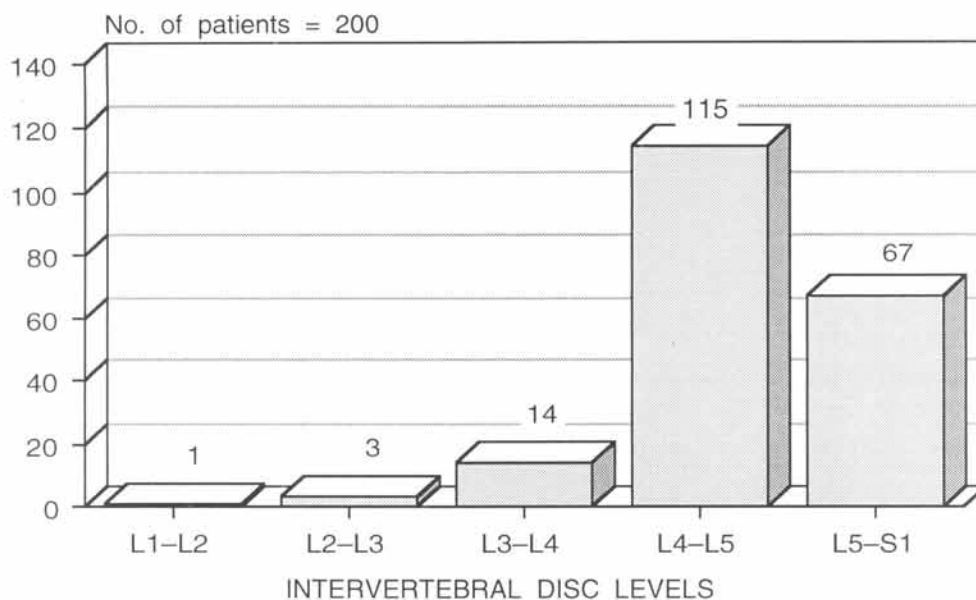
Complications

Injury to the nerve root with dural laceration was observed in two patient with protruded disc at L3/L4 while removing the overlying ligamentum and laminae. After removing the disc material the dura was further excised and left opened and covered with gelfoam. Postoperatively these patients had some sensory impairment with no CSF leakage.

Dural tear with CSF leakage was observed in two patients with prolapse at L4/L5 and L5/S1 in second week. The wounds were reopened and dura repaired.

Two patients developed major wound infection, with pus discharge from the wound. One responded to the antibiotics

Table No. 3
OPERATED INTERVERTEBRAL DISC LEVELS



while the second patient required reopening of the wound. Frank pus was found in the paraspinal muscles. The wound was washed repeatedly with hydrogen peroxide and normal saline.

Discitis

Postoperative discitis was observed in 5 patients (2.5%). It is characterized by persistent low back pain and muscle spasm coming on first to four weeks after operation. The ESR is raised without other signs of infection. The X-Rays performed at about 30 days shows progressive distractive changes of surfaces of vertebral bodies followed by fusion. These patients responded to conservative treatment like immobilization, antibiotics and analgesics.

DISCUSSION

Considerable attention has been focused on the herniated disc as a source of low backache since the entity was first described by Minter and Bar 1934.⁶

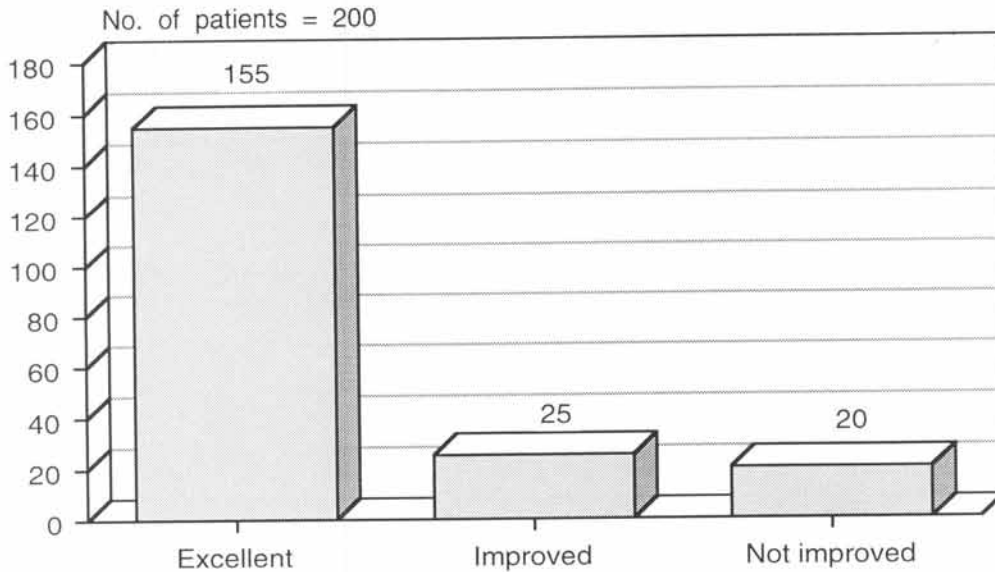
A trial of six weeks conservative treatment is given. Patients with moderate symptoms are treated with limited physical activity, avoidance of lifting heavy weights, bending and twisting and the use of a hard bed. Patients with severe symptoms are treated with absolute bed rest for two weeks and then treated in the same way as those of mild to moderate cases. The purpose of conservative treatment is to protect abnormal disc from straining and its healing by fibrosis.⁷

Application of traction by attaching heavy weight to the leg or pelvis can only serve to confine the patient lying in bed, otherwise forcible traction and manipulation are potentially harmful.⁹ Use of analgesics, sedatives and vitamins are effective in relieving the pain. Steroid injection into the spinal canal or affected lumbar nerve root region may relieve the symptoms but are short lasting.¹⁰

With conservative treatment about 20% of patients are relieved of symptoms. The indications for surgery are:

Table No. 4

RESULTS OF LUMBER LAMINECTOMY WITH DISCECTOMY



1. Extensive midline protruded disc with signs and symptoms of cauda equina e.g. motor or sensory deficit, urinary and faecal incontinence.
2. Patients with prolapse intervertebral disc compresses the exiting nerve root resulting into neurological deficit like foot drop shall be operated as early as possible.
3. Those patients with backache and radiating leg pain confirmed radiologically as a case of prolapse intervertebral disc not responding to conservative treatment for six weeks are considered candidate for surgery.

Those patients not responding to conservative treatment underwent surgery and the surgical procedure performed was lumbar laminectomy with standard discectomy. Standard discectomy is considered as the procedure of choice against which all other procedures can be judged because of high success rate over many years.

The advantage of this procedure is that prolapse intervertebral disc can be removed bilaterally as well as decompression carried out for spinal stenosis if it exists. The potential risks associated with this procedure are quite rare when performed by surgeon experienced in this technique. The present series of patients with intervertebral disc herniation undergoing lumbar laminectomy with discectomy shows that in 180 patients better results were achieved. Patients who presented initially with predominant leg pain, undergoing lumbar laminectomy with discectomy showed better results than patients with primarily low back pain. It was observed preoperatively that patients with only leg pain at an initial examination had higher incidence of an extruded disc fragment than those presenting primarily with back pain. The poorest results were found in few patients, and in these the psychosocial factors such as depression, prolong use of narcotics cannot be ignored. Patients operated for cauda equina did not show complete improvement in neurological deficit. It is extremely

difficult to achieve 100% sexual function even when the patients of cauda equina syndrome are operated within 6 hours.¹¹

There are other procedures like limited discectomy or microdiscectomy. The technique for limited discectomy is similar to that of slanted discectomy except that only herniated part of the disc is removed. This can be carried out without laminectomy with removal of part of the posterior vertebral arch. The chances of recurrence or reherniation are very high. In microdiscectomy an operating microscope is used. The surgical approach and technique are similar to that of standard discectomy.

A number of operative results of prolapsed intervertebral disc have been published. Roughly two third of the patients achieved good to excellent results while in remaining 1/3rd patients the results were poor. The best results were found in patients whose symptoms were those of root compression. While poor results were found in patients complaining of back pain.¹²

The most important factor in the overall surgical success rate is proper patient selection e.g. patients presenting primarily with radiating leg pain, findings of strongly positive straight leg raising sign and associated neurological findings of sensory or motor deficit and correlating it with radiological findings. In these patients it can be predicted clinically that there is high probability of extruded disc fragment, and they will show better results from discectomy. Therefore, case selection could be further improved by simple assessment.

In this region of the world where associated spinal stenosis at one or two segments is common along with disc herniation as found in one third of patients emphasises the fact that lumbar laminectomy with discectomy can be considered as the procedure of choice.

REFERENCES

1. Eismont FJ, currier B. Surgical management of lumbar intervertebral disc disease. *Journal of bone and joint surgery* 71-A 1989; 1266.
2. Lawrence G, Lenke MD, Shirley Moore RN, Kay E, Gachle RN, Sheila West RN. Lumbar Disc Herniation. New Treatment modalities. *Aorn journal*. 1994; 59: 6.
3. Murphey F. Sources and patterns of pain in disc disease. *Clin. Neurosurg*. 1968; 15: 343
4. Shaperas. Cauda equina syndrome secondary to lumbar disc herniation. *Neurosurgery* 1993; 32: 743.
5. Aronson HA, Dunsmore RH. Herniated lumbar disease. *J. Bone joint surg.*, 45-A: 1963; 311.
6. Minter WJ, Barr JS. Rupture of intervertebral disc with involvement of spinal canal. *The New England Journal of Medicine* 1934; 211: 210.
7. Abdullah AF, Ditto EW 111, Byrd EB, Williams R. Extreme lateral lumbar disc herniations: clinical syndrome and special problems of diagnosis. *J. Neurosurg* 1974; 41: 229.
8. Armstrong JR. Lumbar disc lesions. 3rd Ed. Baltimore, Williams and Wilkins Co. 1965.
9. Nachemson A, Elfstrom G. Intravital dynamic pressure measurements in lumbar discs. A study of common movements, maneuvers and exercises. *Scand. J. Rehab. Med.*, Suppl. 1970; 1: 1.
10. Enckler JM, et al. The use of epidural steroids and its treatment of lumbar radicular pain. *Journal of Bone and Joint surgery* 1985; 67: 63.
11. Michael H, Lavynae. Cauda Equina syndrome secondary to lumbar disc herniation. *Neurosurgery*, 1994; 34: 3.
12. Davis CH. Extradural spinal cord and nerve root compression from benign lesions of the lumbar area. *Neurosurgical Surgery*, Second Edition, Edited by Julian R. Youmans, Philadelphia 1980 W.B Saunders Company, 2548.