

CASE REPORT ON ALKAPTONURIA

INTIKHAB ALAM, HAMEED AHMAD, MUNEER BANGASH,
NAVEED KHAN AND BAKHT BILAND

*Department of Medicine,
Postgraduate Medical Institute,
Lady Reading Hospital, Peshawar.*

Alkaptonuria or Ochronosis, a rare autosomal recessive inborn error of metabolism is due to lack of an enzyme called Homogentisic acid oxidase (HGO). This results in accumulation of Homogentisic acid (HA) in the body, the oxidized polymers of which deposit in tissues rich in collagen leading to bluish-black pigmentation, early and severe degenerative changes in large joints and calcification of the intervertebral discs and formation of renal and prostatic calculi and rarely renal failure and degenerative cardiac valvular disease.¹ A middle aged man suffering from Alkaptonuria is reported who possibly has two other family members suffering from the same disease.

CASE REPORT

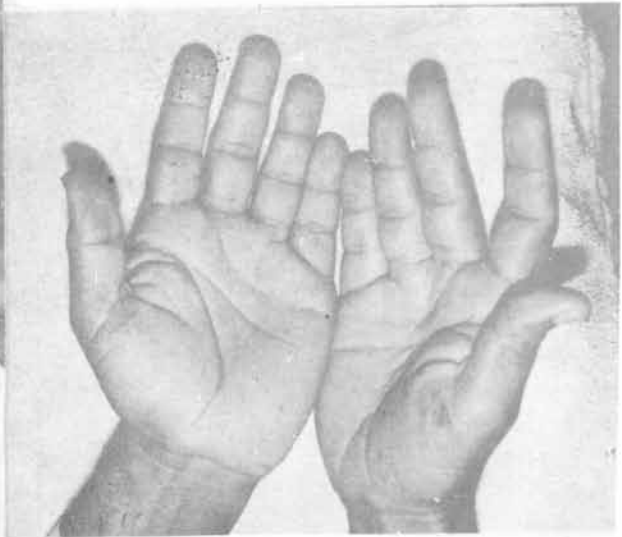
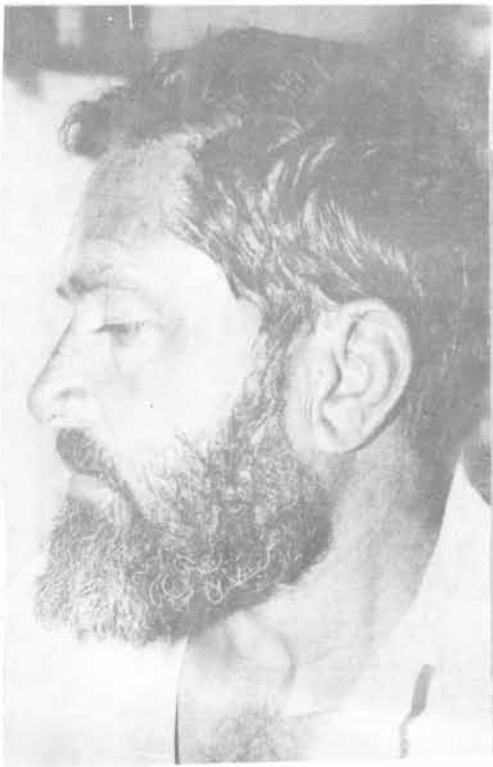
A 45 years old man was admitted in medical A unit of Lady Reading Hospital on 1st march, 1997. He presented with polyarthrititis involving medium and large joints, severe backache gradually increasing in intensity to the extent of disability for the last 11 years and hypertension for the last 2 years. He was already on Tab Atenolol and Diclofenec sodium. He was operated for Appendicectomy in 1975 and twice for Nephrolithiasis in 1985 and 1987. There is history of passing small stones per urethra for the last 12 years. Stones are pale when freshly passed but turn black on exposure to air. (Fig-I) Patient informed that he still

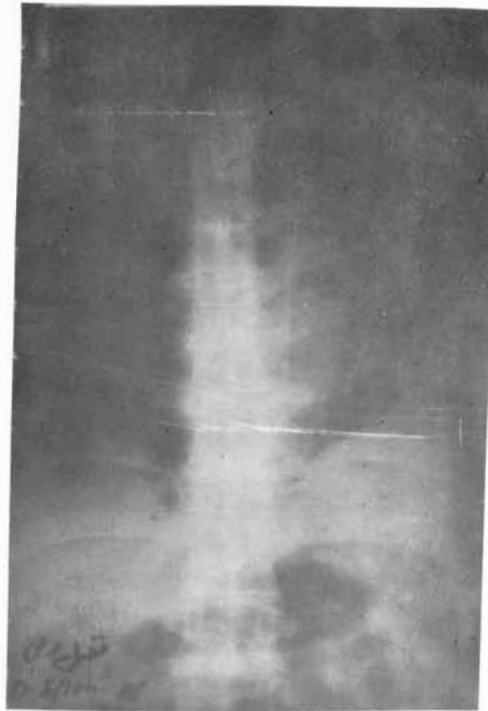had bilateral renal stones which he passed off and on. He also volunteered the history of urine which turns black on standing (Fig-II) and staining of his vests and clothes by his sweat. Patient has 4 sons and 2 daughters who are all healthy, however, one of his nieces who is 4 years of age has urine which turns black on standing and one of his brothers has the same problem. His parents are healthy.

On examination, his BP was 150/95 mmHg and was found to have marked signs of arthritis in both wrists, elbows, shoulders, knees and ankles with very tender and marked limitation of spinal movements. He was noted to have brownish discoloration of his exposed parts of sclerae (Fig III) and bluish black discoloration of his both pinnae of the ears (Fig IV) which were very hard on palpation and grayish blue pigmentation on his palms bilaterally (Fig V). His systemic examination was unremarkable.

On investigation, his kidney functions and haematological screening were normal with an ESR of 19 mm in 1st hr. Urine examination showed 4-5 pus cells with negative growth on culture. Homogentisic acid in urine samples was reported positive by Khyber Medical College and Agha Khan Hospital. ANF and RA factor were negative. Abdominal ultrasound revealed normal sized kidneys having bilateral renal calculi. Chest X-ray, ECG and Echocardiography were

DISEASE → Aleptomycin
SPECIMEN → Urinary Stones
PATIENT → Fasta Rabbi
UNIT → Male Medical A
HOSPITAL → R.G.M.I. Lady Reading
Fishamond



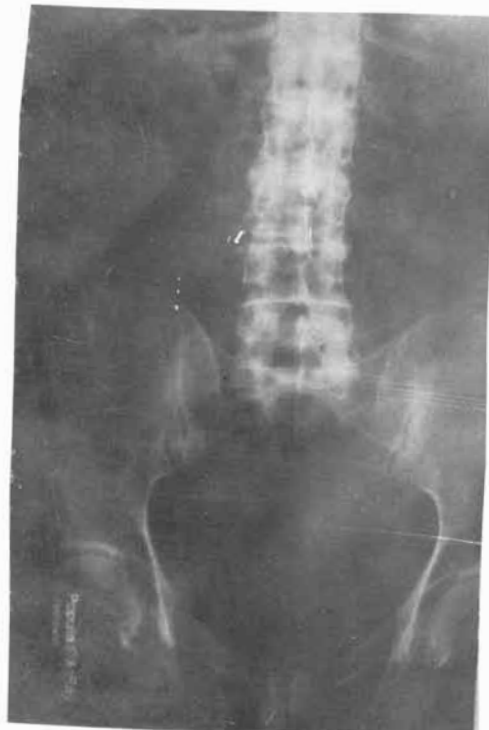

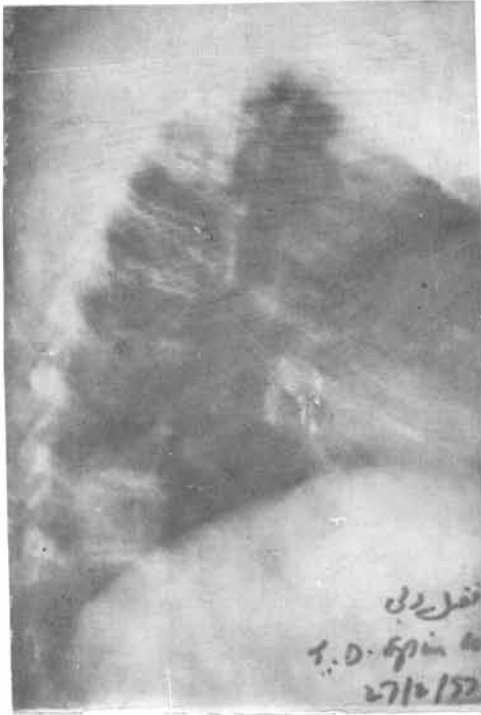
normal. X-Ray Dorsal and Lumbosacral spines revealed marked changes of spondylosis with pathognomonic intervertebral discs calcification (Fig VI). Renal stones were found to be mixed stones on analysis.

DISCUSSION

Alkaptonuria or Ochronosis occupies a unique place in the history of human genetics as it was the first disease shown to be inherited as a mendelian autosomal recessive trait by Garrod in 1902.² It is a rare disorder of Tyrosine and phenylalanine catabolism occurring with a frequency around 1 in 200,000. Heterozygotes show no sign of the disease.³ It is due to the deficiency of an enzyme, Homogentisic acid oxidase (HGO) in the liver and kidneys of the patients. The disease develops due to a loss-of-function mutation of the HGO gene located at Q2 region on chromosome. Alkaptonuria, literally meaning "Black urine", denotes the presence of Homogentisic

Acid (HA) in the urine. The urine darkness to blackness on standing and on alkalinizing due to the presence of oxidized polymers of HA. The patients have minimally increased concentrations of HA in the serum as it is rapidly cleared by the kidneys and as much as 3 to 7 gms of HA may be excreted in the urine per day.³ This high concentration of HA in the urine may lead to formation of ochronotic calculi in the kidneys which may lead to obstructive uropathy¹ or the deposition of the pigment in the kidneys interstitium may lead to chronic tubulo-interstitial disease characterized by widespread tubular atrophy and interstitial fibrosis leading to renal failure.⁵ HA and its oxidized polymers bind to collagen and gradually deposit in the connective tissues, cartilages and intervertebral discs giving them a grey to bluish-black colour macroscopically. Ochronosis denotes the deposition of this dark pigment in the tissues, giving them an ochre (orange) color microscopically.⁶ Clinically this deposition leads to:





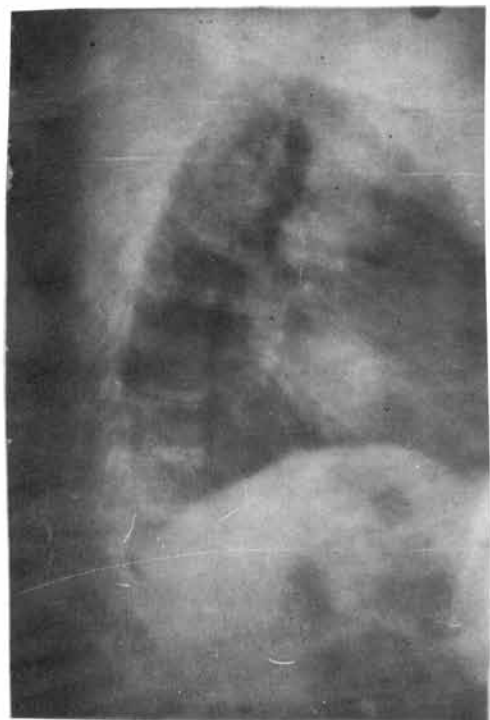
- a. Ochronotic arthropathy characterized by an early and severe degenerative arthritis in large joints and of intervertebral discs which get calcified and is detectable on plain X-rays. The joint cartilages become thin and fragmented and therefore more prone to degenerative changes.⁶ This arthritis is heralded by pain, stiffness and some limitation of motion of the hips, knees and shoulders. Intermittent periods of acute arthritis resembling rheumatoid arthritis occur but small joints are usually spared. Ankylosis of the lumber spine is a common late manifestation. However sacro-iliac joints are not affected.⁷
- b. Ocular and cutaneous pigmentation seen most commonly in the exposed parts of the sclerae, pinnae of the ears and nasal septum.
- c. Cardiovascular ochronosis characterized by calcification and stenosis of the aortic valve¹ and only calcification of the aorta.⁷

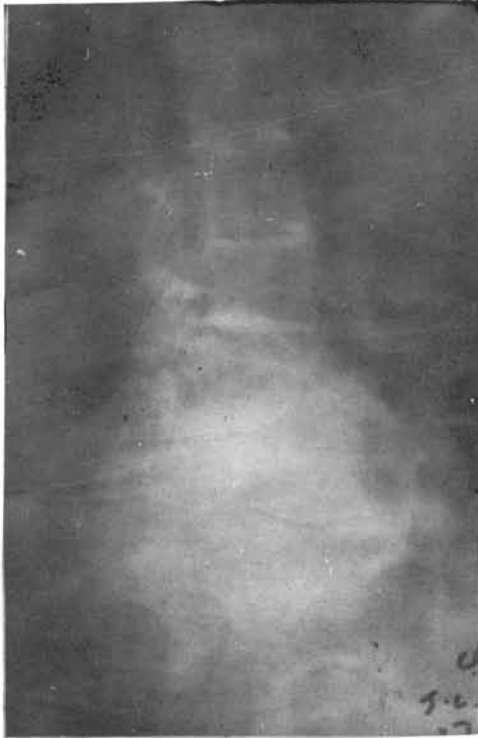- d. Staining of the sweat and cerumen leading to staining of the clothes in the armpits.⁶

The disease may go unnoticed until middle life when degenerative joints disease develops in the majority. However discoloration of the sclerae and the ears generally remain the earliest manifestation developing after age 20 to 30.

Diagnosis

The triad of degerative arthritis, ochronotic pigmentation, and urine which turns black on alkalinization is usually diagnostic. The urine also turns purple-black on adding ferric chloride, brown on adding Benedict's reagent or immediate black on adding silver nitrate solution. These screening tests can be confirmed by chromatographic, enzymatic or spectrophotometric determination of HA in urine. X-ray of the lumber spine are virtually pathognomonic, showing degeneration and calcification of the intervertebral





discs and marrowing of the intervertebral spaces.³

Differential Diagnosis⁸

Acquired ochronosis was formerly encountered in patients in whom phenol dressings were applied to chronic cutaneous ulcers.

Alkaline urine from patients taking either methyl dopa or L-dopa also darkens upon exposure to air.

Treatment

There is no specific treatment of Alkaptonuria. Dietary restrictions of phenylalanine and tyrosine by protein restriction and Vitamin C have been tried in a effort to reduce pigment formation and deposition but no consistent clinical benefit has been observed in the long course of this disease and overall response has been

discouraging. Ochronotic arthritis is managed like any other degenerative arthritis with drug like simple analgesics and NSAIDs, physical measures like application of heat, physiotherapy and hydrotherapy and finally with surgery in the form of osteotomy and ultimately hip or knee joints replacement.⁸

REFERENCES

1. Van Offal JF, De Clerck LS, Francx LM, Stevens WJ. The clinical manifestations of ochronosis a: review. *Acta Clin Belg.* 1995; 50(6): 358.
2. Fernandez Canon JM, Granadino B, Beltran Valero, et al. The molecular basis of alkaptonuria. *Nat Genet.* 1996; 14(1): 19.
3. Leon E Rosenberg. Inherited disorders of amino acid metabolism and storage. In *Harrison's Principles of Internal medicine*, 13th ed. Isselbacher, Braunwald, Wilson, Martin, Fauci, Kasper (eds) McGraw Hill 1994; 2123.
4. Pollak Mr, Chou YH, Carda JJ, et al. Homozygosity mapping of the gene for alkaptonuria to chromosome 3q2. *Nat Genet* 1993; 5(2): 201.
5. Venkateshan VS, Chandra B, Graziano V, et al. Alkaptonuria and renal failure: a case report and review of the literature. *Mod Pathol.* 1992; 5(4): 464.
6. Brenton DP. Inborn errors of aminoacids and organic acid metabolism in *Oxford Textbook of medicine*, 3rd ed, Weatheral DJ, Ledingham JGG, Warrel DA (eds) Oxford university press, 1996; 1364.
7. Smith R. Disorders of the skeleton in *Oxford Textbook of medicine*, 3rd ed. Weatheral DJ, Ledingham JGG, Warrel DA (eds) Oxford university press, 1996; 3085.
8. Warrs RWE. Inborn errors of amino acid and organic acid metabolism in *Oxford Textbook of medicine*, 3rd ed. Weatheral DJ, Ledingham JGG, Warrel DA (eds), Oxford university press 1987; 9.