

# AMELOBLASTOMA — AN EXPERIENCE OF 31 CASES

QIAM UD DIN AND AYUB SHAH SHERANI

*Department of Oral and Maxillofacial Surgery,  
Khyber Medical College of Dentistry, Peshawar and  
Bolan Medical College, Quetta.*

## SUMMARY

This is a review of 31 cases of ameloblastoma seen and managed at the Oral and Maxillofacial surgical Unit, Khyber College of Dentistry and at a private practice over a 10 years period. A male preponderance was found, with peak presentation in the third and fourth decades of life. Most of the patients presented with expansion of both the cortical plates. Curettage and skimming of the healthy bone in unilocular cases of the mandible still holds good provided the patient is followed up for longer period. Resection of the lesion with dento alveolar bone and preservation of the lower border of the mandible is effective conservative management in patients with multilocular ameloblastoma having an intact lower border. Where practicable, bone grafting should be done immediately to avoid the common complications of displacement of principle segments and occlusal disharmony that occur when grafting is delayed.

## INTRODUCTION

Ameloblastoma is the most common benign neoplasm originating from odontogenic epithelia,<sup>1</sup> with locally invasive capacity. It represents approximately 11% of odontogenic tumours<sup>2</sup> and about 1% of all the oral tumours.<sup>3</sup> The disease has even distribution between the sexes.<sup>4</sup> The disease occurs at all ages with a peak incidence in the second and third decades of life.<sup>5</sup> The mandible is by far more frequently affected than the maxilla<sup>6</sup> and in one report the incidence was as high as 99.1%.<sup>7</sup> The tumour proliferates by three dimensional peripheral budding, sending many microscopic projections into the bone marrow spaces and rendering curettage ineffective because of the inaccessibility of the neoplastic islands.<sup>8</sup> The tumour may reach a large size, compress and infiltrate soft tissue, obstruct the air way, affect the nutrition by curtailing normal masticatory function and swallowing, erode major arteries and invade middle cranial fossa.<sup>9</sup> While a conservative treatment by curettage has been suggested,<sup>10</sup> a high recurrence rate has justified radical

resection with inclusion of apparently uninvolved bone.<sup>11</sup>

This study, aims to analyze all those cases of Ameloblastoma seen and managed over the last ten years, at Oral and Maxillofacial Surgical unit of Khyber College of Dentistry, and at a private practice, highlighting the distribution according to sex, age on presentation, clinical features, treatment modalities employed and follow up review.

## MATERIAL AND METHODS

During the period from January 1987 to December 1996, (ten years), 31 cases of ameloblastoma involving the jaws were seen and treated at Oral and Maxillofacial Surgical unit, Khyber College of Dentistry, and at the author's private practice. All the patients were either residents of NWFP or migrated from Afghanistan.

### Sex

A total of 31 patients were recruited in the study. Out of these 18(58%) were males

TABLE – I  
SITE DISTRIBUTION

SITE	NO.	%
Mandibular ramus/molar region	04	13
Mandibular molar region	06	19
Mandibular molar/premolar region	12	38
Mandibular Symphysis/ parasymphysis region	06	19
Maxilla posterior region	03	11

and 13(42%) were females, the male/female ratio being 1.3:1.

### Age

Figure-I shows the age distribution of the patients at the time of presentation. The youngest patient in this study was 9 years old, the oldest was 65 years old and the mean age at the time of presentation was 34.6 years. The age variable was recorded as stated by the patient or his/her attendant and this was considered correct, but majority of the patients did not know their exact date of birth. Twenty two patients (71%) had the disease before the age of 41 years.

AGE DISTRIBUTION

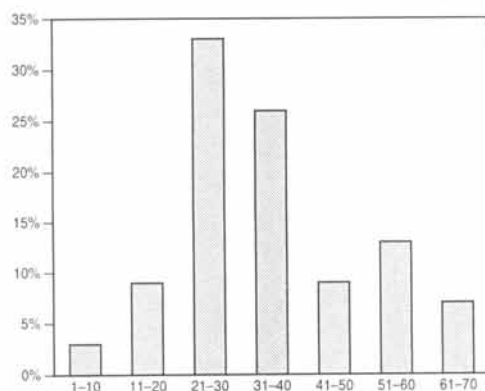


Fig. 1

### Site Distribution

Twenty eight cases (90%) were recorded in the mandible and only 3 cases (11%) in the maxilla. Table-I shows the site distribution of 31 cases. Six cases (19%) involved molar region of the mandible. In 12 cases (38%) both molar and premolar regions were involved. Four cases (13%) involved the molar and ramus region of the mandible and only 6 cases (19%) affected the symphysis and parasymphysis region of the mandible. In this last category the disease was not limited to one side and crossed the midline in all cases. The three

CHIEF COMPLAINT(S)

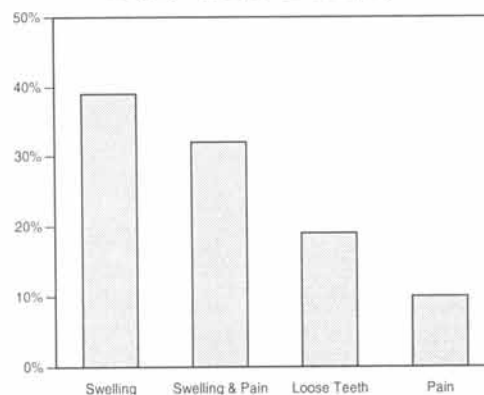


Fig. 2

cases recorded in the maxilla were found in the posterior part of the maxilla and non were recorded in the anterior region.

### Clinical Features

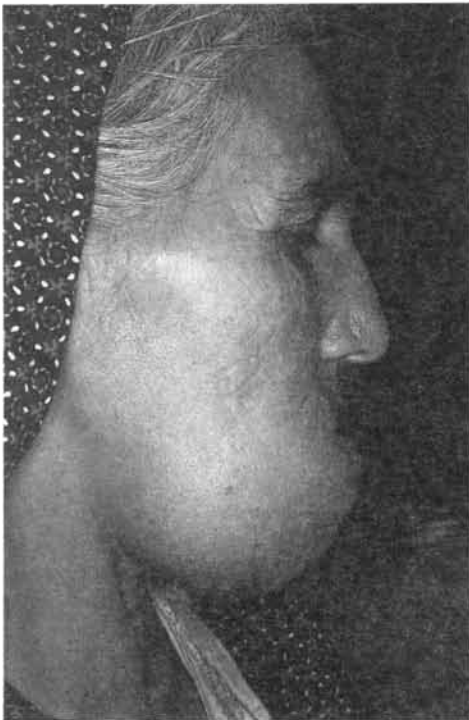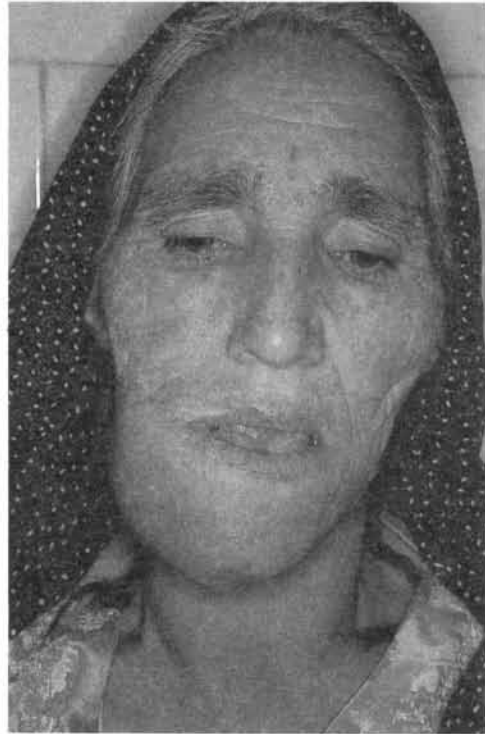Figure-II show chief complaints at the time of presentation. Painless swelling was the most common presenting symptom (39%) followed by painful swelling (32%) and loosening of teeth (19%). Only 10% patients presented with pain as chief complaint. No patient was diagnosed on routine dental/radiographic examination.

### Cortical Plates Involvement

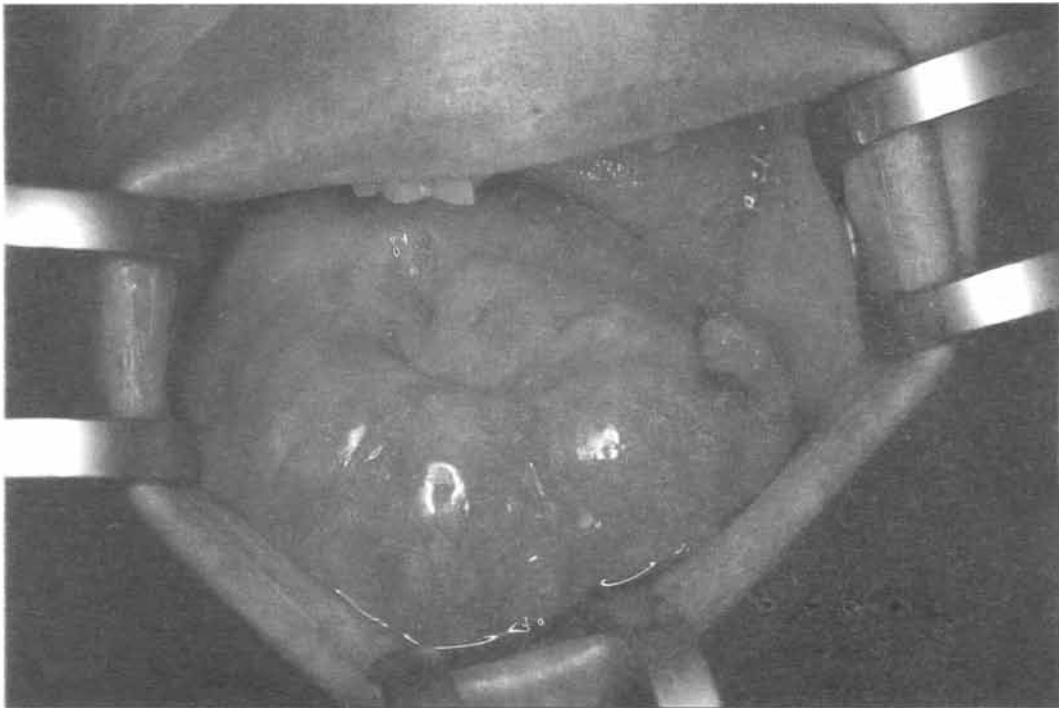Unlike cystic lesions, solid lesions of the Maxillofacial region lead to expansion

## A Gigantiform Ameloblastoma

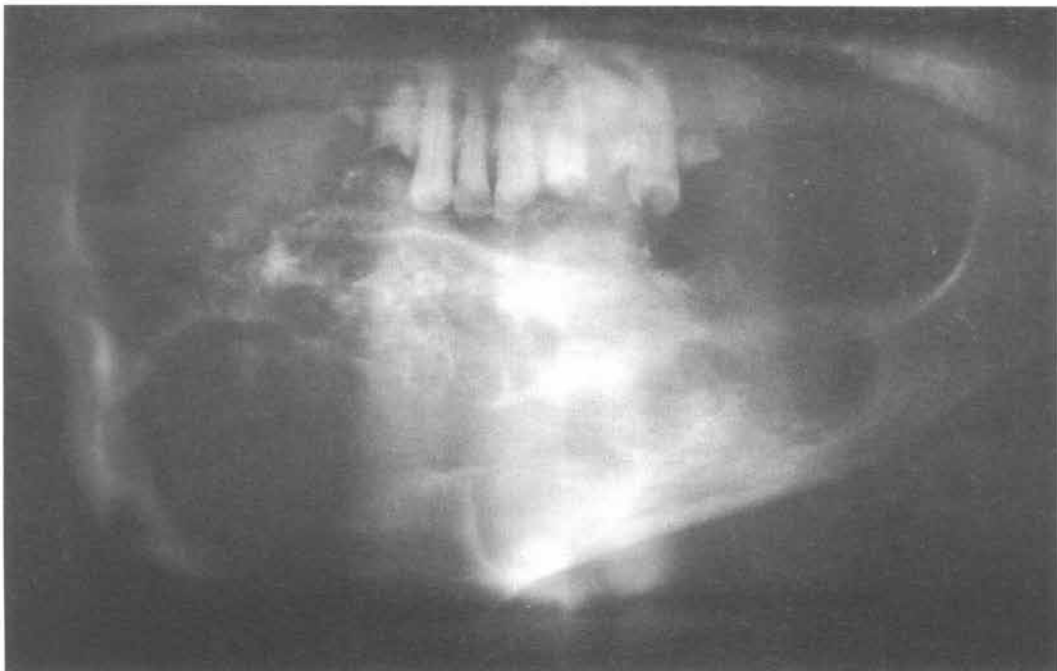
A) Front profile.



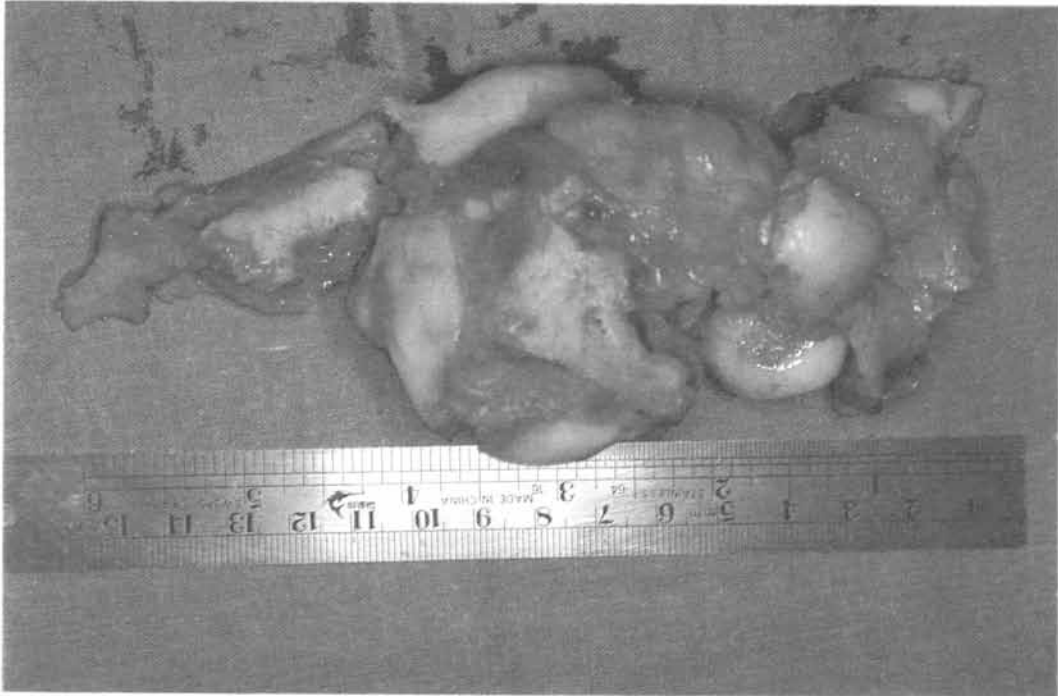B) Lateral profile.



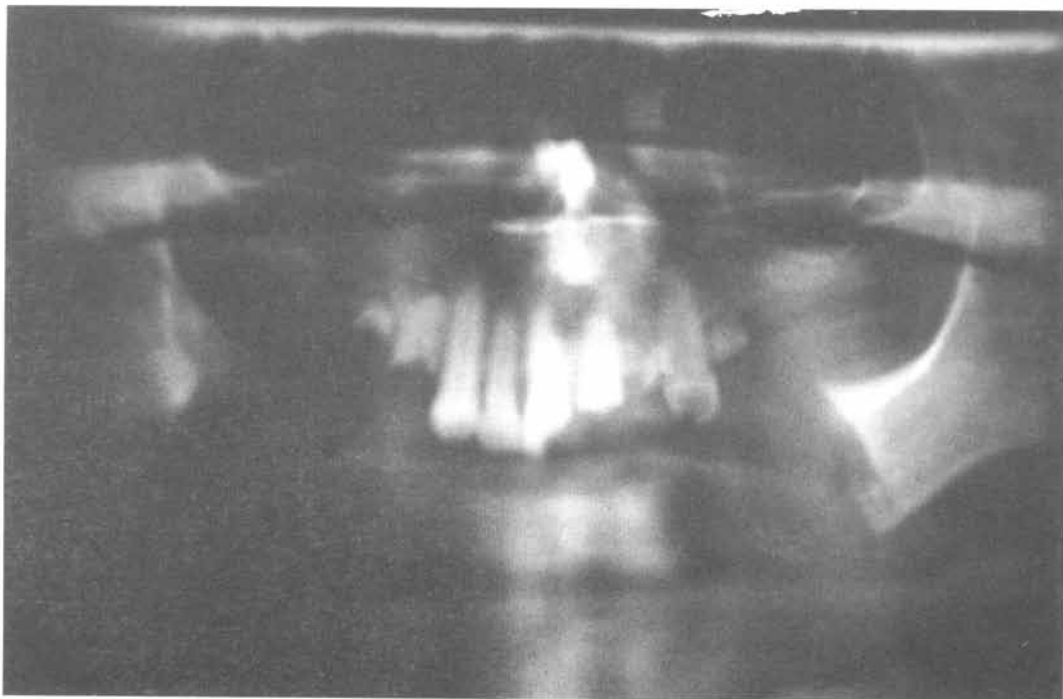
C) Intra oral view.



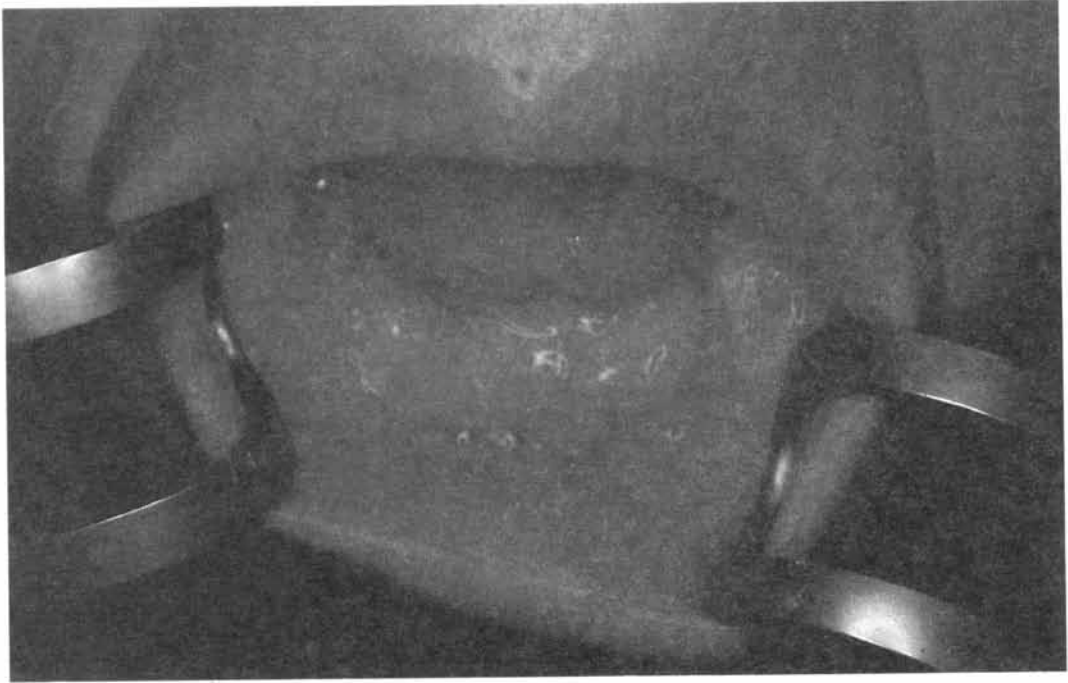
D) OPG showing involvement of almost entire Mandibular body on both side.



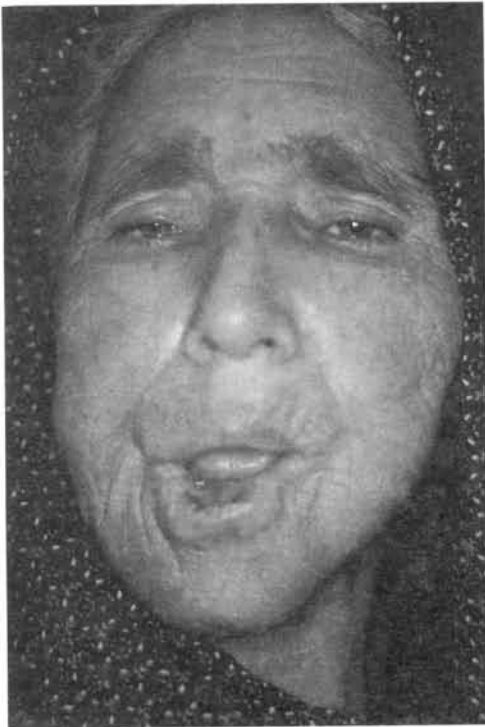E) Post operative photograph showing the entire specimen.



F) Post operative OPG. (The patient refused to spare her rib for immediate Mandibular reconstruction.)



G) Post operative intra oral view.



H) Post operative front profile.

of both cortical plates, once they achieve a moderate size. In 26 cases (84%) both cortical plates were involved suggesting that majority of the cases were of considerable size, while in only 5 cases (16%) either labial/buccal or lingual/palatal plates were involved. Figure-III shows involvement of cortical plates.

### X-Ray Findings

For X-Ray examination, orthopantomograph (OPG) and PNS views were advised and the finding showed that 17 cases (55%) had unilocular appearance, 11 cases (35%) had multilocular appearance, while the typical honey comb appearance was seen in only 3 cases (10%). This distribution is shown in figure-IV.

### Treatment

Table-II shows the types of treatment provided to 31 patients. Among the 17 unilocular lesions, 2 were in the maxilla and 15 in the mandible. The 2 maxillary lesions

### CORTICAL PLATES INVOLVEMENT

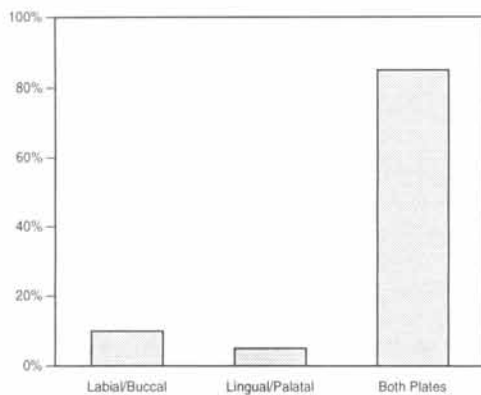


Fig. 3

were treated by segmental maxillectomy through an intra oral approach, while the 15 mandibular lesions with unilocular appearance on OPG were treated by thorough curettage and trimming of the surrounding healthy bone. Of the 11 patients, who had multilocular appearance on OPG, 9 were

TABLE - II  
TYPES OF TREATMENT

TYPE OF TREATMENT	NO.	%
Segmental maxillectomy	02	06.45
Curettage + Bone skimming	15	48.39
Marginal resection	09	29.03
Resection + Bone graft	03	09.68
Resection only	02	06.45

treated by marginal resection by preserving the lower border of the mandible, while the other 2 cases in this group along with 3 patients, who had honey comb appearance on OPG were treated by radical resection of the involved mandible along with the healthy margins.

Only 3 out of 5 patients who had mandibulectomy, received the benefit of bone graft. Rib graft was inserted in all three cases. Financial position, oral hygiene professional and social class were factors in the consideration of patients for bone graft.

### Review and Follow Up

Out of 31 patients, 29 reported for follow up. Of these 27 were free of disease

### X-RAY FINDINGS

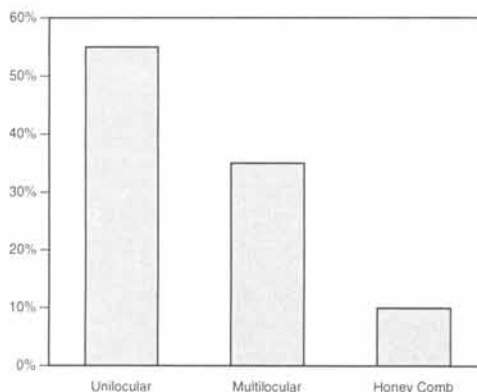


Fig. 4

while 2 had recurrence, which occurred with in an interval of 6-9 months. These patients belonged to the second treatment group, where the lesion was curetted and the surrounding healthy bone was trimmed. Both these cases of recurrence were treated by marginal resection.

## DISCUSSION

The term ameloblastoma was introduced by Churchill in 1934<sup>12</sup> replacing the term "adamantinoma" coined by Malassez in 1885. This change in terminology was based on the fact that the term "adamantinoma" implies to the formation of hard tissue, while no such material exists in ameloblastoma.

Although first mention of the tumor of this nature dates back to 1868 when Broca reported it, but the first thorough description of an ameloblastoma is that of Flakson in 1879.<sup>13</sup>

Ameloblastoma originates from neoplastic changes in the remnants of the dental lamina, either with in the bone or more rarely between periosteum and oral mucosa. There are many published cases purporting to show ameloblastomatous change in follicular cyst walls. Only few of these withstand scrutiny, either from the clinical or histological aspects.

Small and Waldron<sup>10</sup> reviewed over 1000 patients, showing that though ameloblastoma could present at any age, there was a peak incidence at 33 years. The majority, (80%) occur in the mandible, chiefly in the molar and ramus area. However, Akinosi and Williams<sup>14</sup> in a Nigerian study, reported a series of 76 patients of all ages in whom 74% of ameloblastomas presented in the symphyseal region of the mandible. In the present study 71% patients had the disease before 41 years of age. Similarly 71% of ameloblastomas occurred in the posterior part of the mandible (premolar, molar and ramus area) while 19% involved the maxilla.

Swelling is the single most common symptom while pain is not as frequent. The ameloblastoma grows slowly, and it is important to realize that patients may be asymptomatic in the early stage of the neoplasm. Orthopantomogram (OPG) have been of great help in the discovery of this tumor in the early asymptomatic state during the routine dental examination. In maxillary tumors, sinus problems or nasal obstruction may be the first symptom.

Despite numerous studies, complete agreement is still lacking on the management of this tumour. Daramola et al<sup>15</sup> suggested enucleation of monocular lesions with trimming of the surrounding bone. Wilson and Roche<sup>16</sup> also reported the effectiveness in majority of their cases managed by curettage. In this study 2 of the 15 patients managed by curettage and skimming of the bone, had recurrence. This finding suggests that a unilocular ameloblastoma, where the lower border of the mandible is spared, should be treated conservatively. However a close watch is necessary and if recurrence occurs then, marginal resection can be carried out as a second choice. But if the lower border of the mandible is involved in the tumour, no matter what the size of the tumour is, a radical approach in terms of resection is the only choice.

It is generally believed that recurrence rate of ameloblastoma is much higher in maxilla than mandible, probably due to infiltration of the thin, easily penetratable maxillary medullary spaces with extension of the lesion beyond the clinical and radiological margins. While in mandible the thick compact bone tends to restrict their extension. More over tumours in the maxilla are close to the nasal cavity, paranasal sinuses, orbital contents, pharyngeal tissues and vital structures at the base of the skull, which contribute to the unfavourable prognosis of any expanding tumours occurring in the maxilla. Cherrick<sup>17</sup> reported that there



are 82.5% chances of recurrence, when conservative treatment was employed to ameloblastoma of the maxilla. It is therefore suggested that a wider margin of apparently healthy bone needs to be removed to deal with maxillary lesions.

## REFERENCES

1. Ueyama Y, Tsukamoto G, Matsumura T. Gigantic ameloblastoma of the mandible complicating hypoproteinemia: case report *Journal of cranio Maxillo-Facial Surgery* 1995; 23: 47.
2. Regezi JA, Kerr DA, Courtney RM. Odontogenic tumors: analysis of 706 cases *J Oral Surgery* 1978; 39: 709.
3. Lucas RB. Pathology of tumours of the oral tissues. Churchill Livingstone, Edinburgh 1976; 30.
4. Minderjahn A. Incidence and clinical differentiation of odontogenic tumors, *J Maxillofac Surg* 1979; 7: 142.
5. Suzuki A. Odontogenic tumours pathological aspects. *Jpn Pathol Clin Med* 1985; 3: 869.
6. Mehlich DR, Dahlin DC, Masson JK. Ameloblastoma a clinicopathologic report. *J Oral Surg* 1972; 30: 9.
7. Adekeye EO. Ameloblastoma of the jaws a survey of 109 Nigerian patients *J Oral Surg* 1980; 13: 36.
8. Hoffman PJ, et al. The fate of the uncontrolled ameloblastoma. *Oral Surg* 1968; 26: 419.
9. Kyriazis AP, Karjazos GC, Kyriazis AA. Maxillary ameloblastoma with intracerebral extension. *Oral Surg* 1971; 32: 582.
10. Small IA, Waldron CA. Ameloblastoma of the jaws. *Oral Surg* 1955; 8: 281.
11. Jonson RH, Topazian RG. The management of variants of ameloblastoma. *Plast Reconstr Surg.* 1968; 41: 357.
12. Churchill HR. Histological differentiation between certain dentigerous cyst and ameloblastoma. *Dent Cosmos* 1934; 76: 1173.
13. Shafer WG, Hine MK, Levy BM. A text book of oral pathology Philadelphia, WB Saunders Company. 1983; 251.
14. Akinosi JO and William AO. Ameloblastoma in Ibadan, Nigeria *Oral Surg.* 1969; 27: 297.
15. Daramola JO, Ajagbe HA, Oluwasanmi JO. Ameloblastoma of the jaws in Nigerian children a review of sixteen cases. *Oral Surg* 1975; 40: 458.
16. Wilson DL, Roche WC. Dentigerous Cyst with ameloblastomatous change *J Oral Surg* 1960; 18: 172.
17. Cherrick HM. Presentation to American Association of Oral and Maxillofacial Surgeons, Las Vegas 1983.