

# RESULTS OF CONSERVATIVE TREATMENT OF DISPLACED EXTENSION - TYPE SUPRACONDYLAR FRACTURES OF HUMERUS IN CHILDREN

Ismatullah, Liaqat Ali Khan

Accident and Emergency Department,  
Postgraduate Medical Institute, Lady Reading Hospital, Peshawar, Pakistan

## ABSTRACT

**Objective:** To assess the results of conservative treatment of extension-type displaced supracondylar fractures of humerus in children.

**Material and Methods:** This prospective study was conducted at the Accident & Emergency Department of Lady Reading Hospital, Peshawar from Feb 2004 to Jan 2008. A total of 40 children having extension-type displaced supracondylar fracture of humerus (Gartland type II and III) were included in this study. They were treated with blind closed reduction of the fracture and a plaster of Paris back slab. Follow-up was done up to 12 months.

**Results:** All the 40 children included in this study were in the age range of 1 year to 10 years. Among these 22 were males and 18 were females. There were 23 type II and 17 type III fractures according to Gartland classification. The outcome was graded according to Flynn criteria in to excellent, good, fair and poor. Out of 23 type-II fractures, 10 (43.47%) cases showed excellent results, 5 (21.73%) had good, 5(21.73%) had fair and 3 (13.04%) had poor results.

Out of 17 type III fractures, 5 (29.41%) cases had excellent outcome, 3(17.64%) had good, 2(11.76%) had fair and 7(41.17%) had poor results.

**Conclusion:** The results of this study were entirely satisfactory in Gartland type -II fractures. However the results were not good in type-III fractures which require other advanced techniques of secure fixation like closed pinning under image intensifier.

**Keywords:** Supracondylar Fracture, Humerus, Closed reduction, Conservative Treatment.

## INTRODUCTION

Supracondylar fracture of the humerus is a very common fracture in children, occurring most often in the age between 5 to 7 years<sup>1</sup>. Displaced supracondylar fracture may be associated with various complications like neurovascular compromise, compartment syndrome, skin problems, Volkmann's ischaemia and cubitus varus. Its treatment is controversial and technically difficult<sup>2</sup>. There are two types of supracondylar fractures, extension type which is more common (90-95%) and flexion type which is rare (5-10%)<sup>3-4</sup>. The most popular and practically useful classification of extension-type supracondylar fracture in children is that proposed by Gartland<sup>5</sup> (Table-1).

Type-I fractures are simple and easily

treated with splintage for three weeks. It has no inherent complications and heals uneventfully. It is the management of displaced supracondylar fractures (type-II & III) which is challenging and controversial.<sup>6</sup> Various methods of treatment that are used for these fractures include side-arm traction, manipulation under anaesthesia, operative fixation using percutaneous wires and open reduction and internal fixation. All of these methods have advantages and disadvantages and the treatment should be tailored to the morphology of the fracture and the expertise and facility available.

The purpose of this study was to highlight the results of conventional method of blind closed reduction of supracondylar fracture of humerus and its stabilization with a plaster back slab in 40 children in the Accident and Emergency

Department of Lady Reading Hospital where the facility of image intensifier and powered equipments are not available.

### GARTLAND CLASSIFICATION OF SUPRACONDYLAR FRACTURES

Type-I	Undisplaced
Type-II	Displaced with intact posterior cortex
Type-III	Displaced (No cortical contact)

Table 1

### MATERIAL AND METHODS

This prospective study was conducted in the Accident and Emergency Department of Lady Reading Hospital Peshawar from February 2004 to January 2008.

A total of 40 cases of supracondylar fractures were included in this study. The following inclusion and exclusion criteria were used.

#### A. Inclusion Criteria:-

1. Children with supracondylar fractures in the age range of 01 year to 10 years.
2. Gartland type-II & III, extension type, supracondylar fracture of humerus
3. Fresh cases of supracondylar fractures of not more than 4 days duration.
4. Only close fractures.

#### B. Exclusion Criteria :-

1. Open fractures
2. Fractures in which at the time of presentation there was neurovascular compromise, compartment syndrome or skin blisters.
3. Late cases of more than 4 days duration

On entry to the Accident and Emergency Department, the patient was assessed by a consultant to exclude neurovascular injury or other associated injuries. The fracture was classified according to Gartland classification. Under intravenous sedation and analgesia, closed reduction was performed by a consultant and plaster of Paris back slab applied. Post-reduction

### FLYNN CRITERIA

Results	Cosmetic factor- loss of carrying angle (degrees)	Functional factor- loss of elbow movements (degrees)
Excellent	0-5	0-5
Good	6-10	6-10
Fair	11-15	11-15
Poor	> 15	> 15

Table 2

anteroposterior and lateral radiographs were taken. The patient was kept under observation for 12 to 24 hours in Trauma Room for any neurovascular compromise after reduction. The patient was then sent home. For the first 4 weeks the patient was seen at weekly intervals and then at monthly intervals up to total period of 12 months. At each visit radiographs were taken. Plaster back slab was removed at three weeks after reduction and then exercises instituted to restore full range of motion. The results were categorized according to Flynn criteria<sup>7</sup> (table 2). It uses the range of movements of elbow joint for functional assessment and the carrying angle of elbow joint for cosmetic assessment.

### RESULTS

A total of 40 cases were included in this study. All of them, had displaced extension-type supracondylar fracture of the humerus. There were 22 (55%) males and 18 (45%) females (fig. No 1). The male to female ratio was 1.22 to 1.00.

### SEX WISE DISTRIBUTION OF PATIENTS (N = 40)

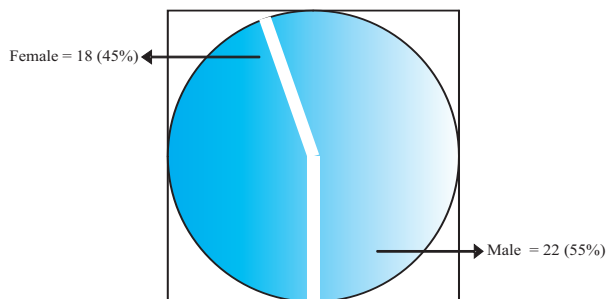


Fig. No.1

The age-wise distribution of patients is shown in table-3.

### AGE DISTRIBUTION OF PATIENTS

Age group	Number of patients
1-4 years	12
4-7 years	20
7-10 years	8

Table 3

Among 40 cases , 20 (50%) presented in the first 36 hours after injury in the Accident & Emergency Department, 12 (30%) presented in 36 to 72 hours and 8 (20%) presented in 72 to 96 hours after injury. Out of 40 Patients, there were 23(57.50%) Gartland type II and 17(42.50%) Gartland type III fractures (table-4).

According to Flynn criteria, results in

**GARTLAND TYPES OF FRACTURES**

Gartland type	Number of Patients (n=40)	Percentage
Gartland type II	23	57.50%
Gartland type III	17	42.50%

Table 4

Gartland type II were 10(43.47%) excellent, 5(21.73%) good, 5(21.73%) fair and 3(13.04%) poor (table-5).

**RESULTS IN GARTLAND TYPE II FRACTURES**

Results	Frequency (n=23)	Percentage
Excellent	10	43.47%
Good	5	21.73%
Fair	5	21.73%
Poor	3	13.04%

Table 5

In Gartland type III fractures the result were 5(29.41%) excellent, 3(17.64%) good, 2(11.76%) fair and 7(41.17%) poor (table-6). The results combined for both types of fractures (Gartland type II and III) in this series of study

**RESULTS IN GARTLAND TYPE III FRACTURES**

Results	Frequency (n=17)	Percentage
Excellent	5	29.41%
Good	3	17.64%
Fair	2	11.76%
Poor	7	41.17%

Table 6

were 15(37.50%) excellent, 8(20.00%) good, 7(17.50%) fair and 10(25.00%) poor (table-7). The common complications in this series were stiff elbow in 6(15.00%) cases and cubitus varus in 4(10.00%) cases. In 1(2.50%) patient, Volkmann's

**COMBINED RESULTS IN GARTLAND TYPE II & III FRACTURES**

Results	Frequency (n=40)	Percentage
Excellent	15	37.50%
Good	8	20.00%
Fair	7	17.50%
Poor	10	25.00%

Table 7

**COMPLICATIONS**

Complication	Frequency (n=40)	Percentage
Stiff elbow	6	15.00%
Cubitus varus	4	10.00%
Volkmann's ischaemia	1	2.50%
Median nerve injury	1	2.50%

Table 8

ischaemia developed which was of mild grade, involving only flexor compartment of forearm. It was treated conservatively. In 1(2.50%) patient, median nerve injury developed after manipulation but it was temporary and recovered after 3 months (table-8).

**DISCUSSION**

Supracondylar fracture of humerus is one of the most common fractures in first decade of life<sup>8</sup>. Before embarking on any treatment, it is useful to classify the fracture. The most commonly used classification is Gartland classification.

Type-I fractures are treated with plaster of Paris back slab. Partially displaced fractures (Type-II) are treated by closed reduction and plaster of Paris back slab. The treatment of Type-III fractures is controversial. These fractures are prone to redisplacement after closed reduction<sup>9</sup>. Recently, the management has evolved from purely conservative approach to more aggressive one. Many surgeons advocate closed reduction of type-III fractures under image intensifier and percutaneous fixation with wires<sup>10,11</sup>. But in many hospitals in Pakistan the facility of image intensifier is not available. Other methods employed for such fractures are side-arm traction<sup>12</sup>

and open reduction and internal fixation<sup>13</sup>. Side-arm traction requires prolonged stay in hospital as well as keeping the child in lying down position in bed, which is a difficult task for parents and hospital personnel. Open reduction and internal fixation involves a major surgical procedure with attendant risks of anaesthesia, hospitalization, infection, high cost and stiff elbow.

Because of non-availability of image-intensifier in the Accident and Emergency Department and the meager facility for open reduction and internal fixation, we have endeavored to achieve good results with closed reduction and splintage in plaster of Paris back slab in displaced supracondylar fractures of humerus in children. Shoaib et al<sup>14</sup> performed a study similar to it in 25 patients having displaced supracondylar fractures (Gartland type-II & III). Their results were excellent in 4 (16%), good in 11

(44%), fair in 3 (12%) and poor in 7 (28%) cases. This study is comparable to our study. The poor results were mostly in type-III fractures. Celiker et al<sup>15</sup> treated 141 patients having supracondylar fractures of humerus. They used either closed methods or open reduction. In the overall series the results were excellent in 72 (52.70%), good in 31 (21.83%), fair in 13 (9.15%) and poor in 26(18.30%). The overall results, having used different methods, were significantly different only in the category of type-III fractures, which afford poor results when treated with closed reduction and splintage alone. Type-III fractures usually redisplace in plaster back slab even after accurate closed reduction. The rate of complications like cubitus varus and stiff elbow are high when type-III fractures are treated with closed reduction and splintage alone. However it is a universally accepted method of treatment for type-II fractures, which are stable after reduction.

In our study, in Gartland type-II fractures, the rate of poor results was 13.04%, whereas in Gartland type-III fracture, it was 41.17% showing a significant difference.

This implies that when managing supracondylar fracture of humerus in children, type-III fractures require more vigilant care and secure fixation techniques<sup>16</sup> to decrease the number of poor results.

## CONCLUSION

Type-II supracondylar fractures of humerus in children can be effectively managed by closed reduction and plaster of Paris back slab. For type-III fractures this type of management is not effective. The frequency of excellent and good results decreases in type-III fractures because of inherent instability and redisplacement in a simple splint.

It is better to use additional stabilization techniques like percutaneous pin fixation or internal fixation with wires.

## REFERENCES

1. Cheng JC, Ng BK, Ying SY, Lam PK. A ten years study of the changes in the pattern and treatment of 6,493 fractures. *J Pediatr Orthop* 2000; 19: 344–50.
2. Sadiq MZ, Syed T, Travlos J. Management of grade-III supracondylar fracture of the humerus by straight-arm lateral traction. *Intern Orthop (Sicot)* 2007; 31: 155–8.

### Address for Correspondence:

**Dr. Ismatullah**

Senior Registrar,

Accident and Emergency Department,  
Lady Reading Hospital, Peshawar.

3. Alburger PD, Weidner PL, Betz RR. Supracondylar fracture of the Humerus in children. *J Pediatr Orthop* 1992; 12: 16–9.
4. Wilkins KE. Supracondylar fracture: What is new? *J Pediatr Orthop (Br)* 1997; 6: 110–6.
5. Gartland JJ. Manangement of supracondylar fracture of the humerus in children. *Surg Gynaecol Obstet* 1959; 109: 145–54.
6. Lee EH. Supracondylar fractures of the humerus in children – Back to basics. *Singapore Med J* 2000; 41: 423–4.
7. Flynn JC, Methews JG, Benoit RL. Blind pinning of displaced supracondylar fracture of humerus in children. Sixteen years experience with long term follow-up. *J Bone Joint Surg Am* 1974; 56: 263–72.
8. Shoaib M, Sultan S, Sahibzada SA, Ali A. Percutaneous pinning in displaced supracondylar fracture of humerus in children. *J Ayub Med Coll Abbottabad* 2004; 16: 48–50.
9. Rijal KP, Pandey BK. Supracondylar extension type III fracture of the humerus in children: Percutaneous corrs-penning. *Kathmandu Univ Med J* 2006; 4: 465-9.
10. Lee YH, Lee SK, Kim BS, Chung MS, Baek GH, Gong HS, et al. Three lateral divergent or parallel pin fixations for the treatment of displaced suparcondylar humerus fractures in children. *J Pediatr Orthop* 2008; 28: 417-22.
11. El-Adl WA, El-Said MA, Boghdady GW, Ali AS. Results of treatment of displaced supracondylar humeral fractures in children by percutaneous lateral cross-wiring technique. *Strategies Trauma Limb Reconstr* 2008; 3:1-7.
12. Israr A, Durrani Z. Management of displaced supracondylar fracture of humerus in children by side-arm traction. *Pak J Surg* 2006; 22: 159–61.
13. Zulfiqar S, Zamir S, Saeed S. Management of supracondylar fracture of humerus in children at Nawab Shah. *Pak J Surg* 2006; 22: 219–21.
14. Shoaib M, Hussain A, Kamran H, Ali J. Outcome of closed reduction and casting in displaced supracondylar fracture of humerus in children. *J Ayub Med Coll Abbottabad* 2003 ; 15: 23–5.
15. Celiker O, Pestilci FI, Tuzuner M. Supracondylar fracture of humerus in children. *J Orthop Trauma* 1990; 4: 265–9.
16. Rehana AS. Displaced supracondylar fractures of the humerus in children, treated by closed reduction & percutaneous pin fixation. *Ann Abbasi Shaheed Hosp Karachi Med Dent Coll* 2004; 9 : 596–600.