

MANAGEMENT OF KIENBOCK DISEASE BY RADIAL SHORTENING

Shahab Ud Din, Shahid Hussain and Sikandar Hayat

*Department of Orthopaedic,
Postgraduate Medical Institute,
Hayatabad Medical Complex, Peshawar.*

SUMMARY

Kienbock's disease is a vascular necrosis of the carpal lunate, which is first described by Robert Kienbock. Litchman classified this disease in four stages. All the stages need surgical intervention except acute phase of the disease. Statistically kienbock's disease has relation with negative ulnar variance. In this study ten patients, (5 patients of stage II and III each) all were negative ulnar variance. All were treated with radial shorting. All patients improved wrist pain (78%), range of movements improved (88%), grip strength (75%) and radio logically (80%). I recommend radial shorting procedure for stage II and III patients.

INTRODUCTION

Kienbock's disease is a pain full disorder of the Wrist, unknown etiology in which x-rays shows avascular necrosis of carpal Lunate, first described in 1910, by Robert Kienbock.¹ Stahl followed the progression of the disease and refinement of the system, which he proposed to grade the condition.^{2,3}

There is an apparent statistically relation between the incidence of kienbock's disease and negative ulnar variance.^{4,5} Lichtman⁶⁻⁷ had classified four clinical and Radiological stages. There is a liner and

compression fracture but normal architecture and density. Density is abnormal with out lunate collapse. Lunate collapse is present. Extensive osteoarthritic changes are present.

Management depends upon above mentioned stages. In all stages the surgical procedure are indicated stage I to III joint leveling procedure, in stage IV extensive inter carpal fusion silastic arthroplasty, vascularised graft, proximal row carpectomy and wrist arthodesis.⁶⁻⁷

Joint leveling procedure, radial shorting, and ulnar lengrhning, of the carpal bone.

MATERIAL AND METHODS

Ten patients were treated by radial shortening from Jan 1998 till Dec. 1999 with follow up of one year at Orthopaedic Department Hayatabad Medical Complex, Postgraduate Medical Institute, Peshawar.

At time of diagnosis all patients were examined clinically and radiologically. There were 6 females and 4 males patients, age range was 15-35 years, mean age was 23.5 years, side involves left wrist 6 and right wrist.⁸ Stage's wise 5 patients were in stage II and III respectively.

All patients radiologically were, the ulnar variance was determined on radiography by the technique described by Palmer et al,⁵ the mean ulnar variance was 2.4mm (-1 to -4.2).

All patients were operated according to Almquist and Burns⁹ recommended technique, a longitudinal radiopalmar approach to the distal radius. The dissection was carried out medial to radial artery, pronator quadratus and origin of the flexor pollicis were exposed, periosteum was incised and radius exposed subperiosteally. An osteotomy was performed, a 1 to 2mm wafer of radius according to minus ulnar variance

and fixed with T-shaped compression plate. Closure performed in layers postoperative immobilization with long arm cast. At four weeks cast was changed to short arm cast for another two weeks. Then follow up was carried out clinically and radiologically at six weeks interval for one year.

RESULTS

Wrist pain has been improved in seven patients (78%).

Pronation and supination improved in eight patients (88%).

The relative grip strength increase 75% as compared to normal contra lateral wrist.

Radiological measurement of the carpal height and the width of the lunate, radio density flattening and cyst formation within the lunate.

On radiological measurement to note the progression of the kienbock's disease. The most useful was the width of the lunate. The mean increase was 2.5 mm, as shown in Fig-1. The flattening of the lunate has improve in three patients (60%), as shown in Fig-2, and unchanged in two patients (40%).

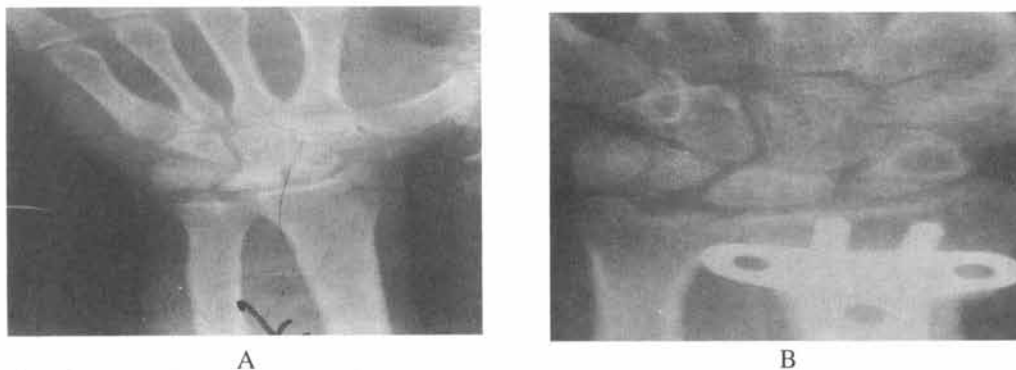

Fig. 1 (A) Pre operative radiograph of a patient with stage (III), negative ulnar variant.
(B) Post operative radiograph of the same patient with the improvement of lunate height and with zero ulnar variant.

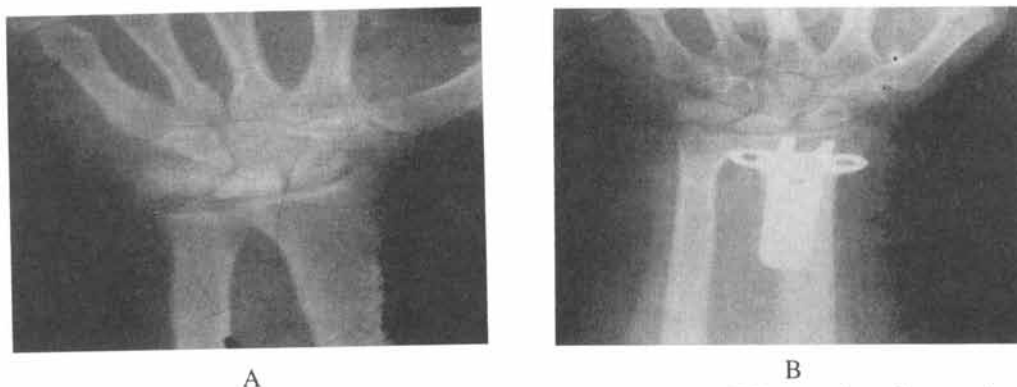


Fig. 2 (A) Pre operative radiograph of a patient with stage (III), negative ulnar variant.
(B) Radiograph of the same patient after one year with normal height of the lunate.

One patient with stage II did not turn up for 3rd follow up. In one patient pain has worsened and range of movements, were not improve due to subluxation of inferior radio ulnar joint, treated with splint.

DISCUSSION

In the literature little has been published on the management of the Kienbock's disease and there are no standards by which results can be compared Tillber¹⁰ who followed up the results of ulnar lengthening in ten wrists for a mean of 13.5 years reported that the all patients were satisfied and that there was no evidence of osteoarthritis. Razemon¹¹ reported good results of 28 patients with radial shortening procedure with the average follow up of 10 years. Almquist and Burns¹⁵ reported satisfactory results with radial shortening procedure. Vitek and Schonbauer¹² also reported good results with radial shortening. Geckenbaugh et al,¹³ Tajima¹⁴ reported good result with joint leveling procedure. Mikkelsen et al¹⁵ Kristensen et al³ have found conservative treatment is ineffective or suitable only for acute phase of the Kienbock's disease.

It is conclude in the present study that radial shortening is easier to perform with

less potential for postoperative pseudarthrosis and more direct approach to decompressing the lunate.

REFERENCES

1. Kien Bock R. Uber traumatische makazue des nibdbeins und kompression fractures. Fortschr roentgenstrahlen. 16:77-103, 1910-1911.
2. Trail IA, Linscheid RL, Quenzer DE, Schere PA. Ulnar lengrhening and radial recession procedures for Kienbock's disease: long term clinical and radiographic follow up. J Hand Surg Br 1996; 21: 169.
3. Stahl F. on lunatomalacia (kienbock's disease): a pathogenesis and the late results of immobilization treatment. Acta Chir Scand 1947; 95(126): 3.
4. Kristensen SS, Soballe K. kienbock's disease: the influence of arthritis on ulnar variance measurements. J Hand Surg Br 1987; 12: 301.
5. Plamer AK, Glisson RR, Werner FW. Ulnar variance determination. J Hand Surg. 1982; 7376.
6. Lichtman DM, Alexander AH, Mack GR, Gulnther SF. Kienbock's disease: update on silicone replacement arthroplasy. J Hand Surg. 1982; 7: 343.
7. Lichtman DM, Mack GR, MacDonald RI, et al. Kienbock disease: the role of silicone

- replacement arthroplasty. *J Hand Surg Am* 1972; 59: 899.
8. Salman J, Stainly JK, trail IA. Kienbock's disease. Conservation management versus radial shortening. *J Bone Joint Surg Br.* 2000; 82; 820.
 9. Almquist EE, Burns JF Jr. radial shortening for the treatment of kienbock's disease: 5 to 10 year follows up. *J Hand Surg.* 1987; 7: 348.
 10. Tillberg B. Kienbock's disease treated with ostetomy to Lengthen ulna. *Acta Orthop Scand* 1968; 39: 359.
 11. Razemon JP. Treatment of Kienbocks's disease with segmentary shortening of the radius: a propos 28 cases. *Chirurgie* 1984; 110: 600.
 12. Vitek M, Schonbauer HR. Long term results of conservatively operated necrosis of the lunate bone. *Handchir Mikrochir Plast Chir* 1987; 19: 322.
 13. Beckenbaugh RD, Shives TC, Dobyms JH, Linscheid RL. Kienbock's disease: the natural history of kienbock's disease and consideration of lunate fractures. *Clin Orthop* 1980; 149: 98.
 14. Tajima T. An investigation of the treatment of Kienbock's disease. *J Bone Joint Surg Am* 1966; 48-A: 1649.
 15. Mikkelsen SS, Gelinek J. Poor function after non operative treatment of Kienbock's disease. *Acta Orthop Scand* 1987; 58: 241.