
SURGICAL MANAGEMENT OF DEPRESSED SKULL FRACTURE

Mumtaz Ali, Liaqat Ali, Inayat Shah Roghani

*Department of Neurosurgery,
Lady Reading Hospital, Peshawar and
Hayatabad Medical Complex, Peshawar.*

ABSTRACT

Objectives: To study the outcome of surgical management of depressed skull fracture.

Material and Methods: This study was conducted from April 1995 to March 2001, in department of Neurosurgery PGMI/LRH Peshawar. A total of 98 patients with depressed skull fracture, treated surgically were included in the study. It included patients operated for cosmetic reasons or functional outcome. Patients treated conservatively, secondary to fire arm injury and penetrating objects were excluded from the study. Details regarding the causes, duration and clinical conditions were documented. X Rays skull were done in all cases. CT scan was done in 78 cases. After surgery patients were followed up for 9 months. Clinical examination of the wound for sepsis, CSF leak, check up X Rays/CT scan and neurological assessment of patients was done on every visit.

Results: A total of 98 patients were operated under general anesthesia in the emergency. There were 63 (61.74%) male and 35 (34.3%) female patients with age ranged from 01-55 years with an average age of 11 years. The causes of depressed skull fracture were, falls from height in 53 (51.94%) cases, road traffic accident in 32 (31.36%) cases, sports injury in 2 (1.96%) cases, physical violence in 7 (6.86%) cases and miscellaneous in 8 (7.8%) cases. 30 (29.4%) cases were operated for cosmetic purpose while the rest of 68 (66.64%) cases were operated for functional outcome. Closed depressed skull fracture was noted in 23 (22.54%) cases, while compound depressed skull fracture was in 75 (73.5%) cases. The incidence of depressed skull fracture was 14 (13.7%) in frontal bone, 17 (16.66%) in fronto-parietal, 18 (17.64%) in temporal, 30 (29.4%) in parietal, 11 (10.78%) in occipital, 4 (3.9%) on superior sagittal sinus, 3 (2.94%) on confluence of sinuses and 1 (0.96%) on transverse sinus. Indications for surgery were depressed skull fracture more than 5 mm in frontal, fronto-parietal area, all opened depressed skull

fractures, with focal neurological deficit, leaking CSF and oozing brain matter along with depressed fracture. Postoperatively 66 (64.68%) showed excellent recovery, 13 (12.74%) were hemiparetic, 3 (2.94%) were dysphasic, 11 (10.78%) were having seizures, 9 with post traumatic syndrome and 2 (1.96%) remained in vegetative state, and 4 (3.92%) developed meningitis. No CSF leaks were noted.

Conclusion: Depressed skull fracture is a common neuro-traumatic disorder. The commonest causes in our society are:- fall from height and Road traffic accident. In time surgical management gives excellent results and leads to minimize the sequel of this condition. Most of the causes can be prevented just by adopting preventive measures. The condition can be treated in periphery hospital as well, if trained personals are available.

Key words: Depressed skull fracture, Surgical management.

INTRODUCTION

A skull fracture is said to be depressed when a fragment of skull bone is displaced inward a distance equal to or greater than the width of the calvarium¹. Skull fracture can occur with or without damage to the brain and its covering. It is common in patients with low speed trauma². The principles of its management have undergone through a considerable evaluation in the past few decades³. Both conservative and surgical managements are adopted. Even the majority of compound depressed skull fractures can be managed without operation⁴. Patients with severe contamination of wound, an established infected wound, a ragged scalp lacerations, severely comminuted fractures and the presence of brain or cerebrospinal fluid leakage from the wound need surgical management.

When depressed skull fracture is associated with scalp laceration it is called on open depressed skull fracture and if not then simple depressed skull fracture⁵. Closed depressed skull fractures are of cosmetic

importance when there is no neurological deficit, while compound depressed skull fractures are of more clinical importance. If these cases are not managed properly, can result in life threatening complications. Proper early debridement of devitalized tissue, repair of dural defect and closure of the wound are the standard principles. Replacing the depressed bone fragments at the time of initial surgery is safe and save patients from cranioplasty but such a practice is potentially associated with a higher incidence of postoperative wound infection if the time interval since injury is more than 24 hours⁶.

MATERIAL AND METHODS

A prospective study of 98 patients of depressed skull fractures treated surgically is presented. All these cases were treated at the department of neurosurgery postgraduate medical institute, HMC Peshawar from April 1995 to March 2001. Those fractures resulted from sharp instruments and missiles injuries were excluded from this study.




FIG.-I

These patients were from different areas of NWFP. All of these cases were referred to surgical casualty and later on, shifted to neurosurgical unit.

Detail history, apart from age, sex and address, regarding the cause of depressed skull fracture, duration since injury, clinical condition, x-ray findings and CT picture were documented. Six patients were having orthopaedic problems in the form of long bones fractures in addition to depressed skull fractures, which were managed in casualty orthopaedic ward, before transferring to neurosurgical unit. X-rays skulls were done in all cases. Both anterior posterior and lateral view were taken in 100% of cases while town's views were taken in 5 cases only along with anterior posterior and lateral views. CT Scans were done in 78 cases. Those patients with deteriorated level of consciousness were put on a loading dose of intra venous mannitol till surgical arrangements were done. Both S. shaped linear and horse shoe flap incisions were used according to type and site of depressed skull fractures.

In highly communicated infected cases, depressed fragments were removed while in clean and closed cases with less than 24 hours of injury period; bone pieces were

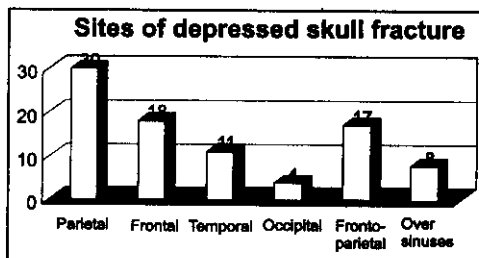


FIG.-II

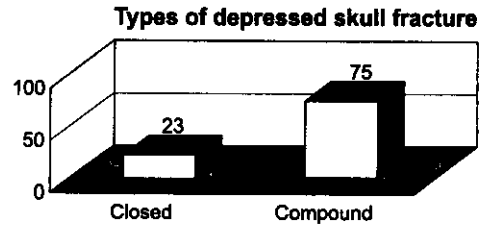


FIG.-III

cleaned and put back in the form of graft after putting in hydrogen peroxide. Thorough wash was done with normal saline and hydrogen peroxide. Dural repair was done in 15 cases. Anterior 1/3 of superior saggital sinus was ligated in 2 cases. The patients were followed for 9 months period. Clinical examination of the wound for sepsis and CSF leak, removal of stitches, check up x-ray and neurological assessment of patients were done on every visit. Out of 98 patients, 94 were regularly followed in this study while the rest of 4 cases were labeled defaulter. Probably the reason of not following up was that, they were belonging to Afghanistan and remote areas of the N.W.F.P. The parents of children's and patients themselves showed enough cooperation following the instructions advised. On every visit, both clinical and radiological examination, and when needed CT Scans were done. X-ray and CT films were retained in hospital for comparative study.

RESULTS

98 patients with depressed skull fractures treated over seven year period are presented. Maximum numbers of patients 45 (44.1%) were of school going age. The average age of these patients was (11.5 years) with age range from 1 to 55 years. There were 63 (61.74%) males and 35 (34.3%) females with male to female ratio of 1.8:1. (Fig-I) The incidence of depressed fracture was 30 (29.4%) cases in parietal, 14 (13.7%) cases in frontal, 18 (17.64%) cases in

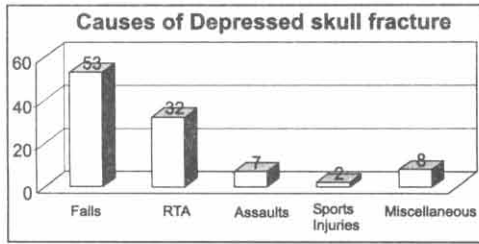


FIG.-IV

temporal, 11 (10.78%) cases in occipital, and 17(16.66%) cases in fronto-parietal bone. 4 (3.9%) cases on superior saggital, 3 (2.94%) cases on confluence of sinus and 1(0.96%) on transverse sinus respectively. (Fig.-II) 23 (22.54%) cases were belonging to simple depressed fracture, out of which 5 (4.9%) in frontal and 8 (7.84%) in parietal region while the rest of 75 (73.5%) cases were of compound variety. (Fig.-III) The ratio of closed with compound injury was 2:5 The causes of depressed skull fracture in these cases were falls from heights in 53 (51.94%) patients, road traffic accidents in 32(31.36%) patients, physical assaults in 7 (6.86%) patients, sports injury in 2 (1.96%) patients and different miscellaneous, causes like domestic happenings etc in 8 (7.84%) cases. (Fig.-IV) The average period of time from the injury to arrival in neurosurgery unit was 4.8 days with range from six hours to 15 days. Those patients who were neurological stable were only radiographed while those with focal or global neurological symptoms were scanned. Among the 98 (96.04%) patients who underwent surgery, most of them were

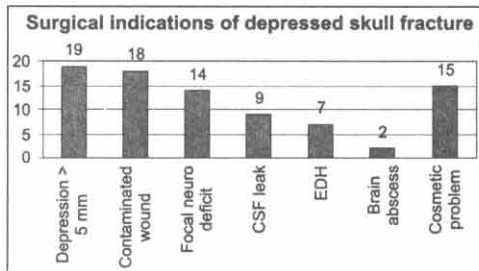


FIG.-V




FIG.-VI

operated in emergency, 87 (85.26%) cases and in few cases elective surgery was performed, 11(10.785) cases. All these patients were operated under general anesthesia.

The indications for surgery were depressed fragments of bone more than 5 mm below the inner of skull in 19 (18.62%) cases, gross contamination of wound in 18 (17.64%) cases, focal neurological lesions in the form of exposed brain matter, monoplegia, hemiplegia, dysphasia and disturbed vision in 14 (13.72%) cases, oozing brain matter with CSF leak in 9 (8.82%) cases, extradural haematoma in 7 (6.86%) cases, brain abscess in 2 (1.96%) cases and cosmetically deforming defects in 15(14.7%) cases. (Fig.-V) Primary closure of dural defect was possible in most of cases i.e. in 45 (44.1%) cases while in only 5(4.9%) cases duroplasty was done. Depressed bone fragments were replaced in 68 (66.64%) cases only and discarded in 30 (29.4%) cases out of 68 (66.64%) compounds depressed skull fracture. In the outcome analysis, 57 (55.86%) patients showed excellent recovery, 3 (2.94%) patients were hemiparetic, 3 (2.94%) cases were dysphasic, 11 (10.78%) were having seizures disorder, 9 (8.82%) with post traumatic syndrome, 4 (3.9%) developed meningitis and 2 (1.96%) remained in vegetative state. (Fig.-VI)

In the follow up, 94 (92.12%) patients were followed and 4 (3.92%) were labeled defaulter. Out of defaulters three were belonging to Afghanistan and one of the Northern areas of NWFP. The defaulter cases were considered free of any complications in the results discussed. The mean duration of follow up was 10 months.

DISCUSSION

Trauma is a huge problem in the developed countries as well in developing countries and head injury is a lethal factor of mortality in young population⁷. Most of the patients admitted to hospital after head injury remain in general hospital cared for a variety of specialist, only a minority are transferred to the regional neurosurgical unit⁸.

Depressed skull fractures are common injuries and majority of them belong to compound varieties. Both conservative and surgical methods can be adopted for management of these patients, depending on cosmetic and functional outcome.

Comparing the general factors of our 98 patients series with other study. We noted the following points which affected the outcome of those patients. These were age, cause of depressed skull fracture, type of depressed skull fracture, site of depressed skull fracture, associated injuries pre & postoperative treatment.

In our cases, maximum numbers of patients were children of school going age which were at special risk to road traffic accident during school timing and falling from roof top. Falling from roof top was common in urban and from trees and mountains in the rural areas due to their habits of flying kites and climbing up. This facture has been highlighted by Lange Casack H et al in his study⁹.

Road traffic accident is another common cause in urban area particularly in congested cities. Z binden B and E.N Sayi, have reported RTA as the cause of depressed skull fracture in 32% and 65.8% of cases respectively¹⁰. Physical violence and sport injuries are not seen commonly, but in an uneducated society can be considered as an important factor and new parts. We saw depressed skull fracture of 14 cases in

frontal, 18 cases temporal, 17 cases temporo-parietal, 30 cases parietal and 4 cases in occipital. Robert F et al reported depressed skull fractures in 48% of frontal and 37% of parietal bones, 50% of frontal and 33.3% of parietal bones were the common sites for depressed skull fractures¹¹. A Adelaye and Sayi has reported 36.8%, 39.5% in frontal and parietal bones respectively¹².

Occipital and temporal were rarely reported. We saw it in those patients, who had fall on back and were hit by friends during fighting.

Extradural haematoma was seen in 8 cases. These fractures were in temporal region. Depressed skull fractures finding was reported by N. R. Jones et al in 11.3% of his patients with extradural haematoma. We noted 71 (75%) of patients having compound depressed skull fractures while only 23 were closed. The reason may be that compound injuries are considered very serious and sent for hospitalization, which is markedly less than 50% & 90% of simple depressed fractures reported by other authors. Otherwise the incidence might have been more what we have reported in our series.¹³

Although conservative methods could be adopted in large number of cases with good outcome¹³, but we operated, all our 98 patients because of clear surgical indications keeping the cosmetic and functional outcome.

The indications for surgery were cosmetics in 15 patients grossly contaminated wound in 18 patients dural violation in 8 patients, focal neurological deficits in 14 patients extradural haematoma in 8 and depressed bone on sinuses 9. In the study of S. M. Mlay and E. N. Sayi 1993 indications for surgery were 68% for cosmetic purposes, 13.6% for open fractures and 9.1% for focal neurological deficits and torn dura respectively¹⁴. Those cases with closed depressed skull fractures were operated on elective

operating days while compound depressed fractures with neurological deficits were operated in emergency. Grossly contaminated wounds were full of hair, sands, wooden and cloth pieces and tobacco past (Naswar). Tobacco paste (Naswar) was seen in one case that came from hilly area of our province, where it is used for haemostatic purpose. Normal saline and hydrogen peroxide were used during debridement of wounds. The comminuted bone pieces were washed and replaced in 8 cases. All these cases were operated within 24 hours after sustaining injury except one whose duration was not exactly noted and this case later presented with osteomyelitis and thus bone pieces were removed. Probably the time passed since injury was more than 24 hours. Though the concept of putting the patients own bone pieces after washing with hydrogen peroxide is not a new one⁶, but is still a controversial point. Matson and Meirowsky both have the ideas of not putting the depressed bone fragments after elevation and their removal have been suggested while Coleman, and Kriss et al are in favor of utilizing of bone pieces after proper washing in hydrogen peroxide, to fill the skull defect. They have made the duration since injury a limiting factor i.e. the injury should not be more than 24 hours¹². In 1991 James B. et al has reported good results in their series of immediate replacement of depressed bone pieces in one sitting⁶.

We came across with the following postoperative complications in the form of infections in 13 cases, meningitis in 4, wound sepsis in 5, osteomyelitis in 1 and brain abscesses in 4, ugly surgical scars in 12 cases, and seizures in 11 cases and other miscellaneous complication in the form of psychosomatic symptoms / post traumatic syndrome in 9. Excellent recovery was seen in 66 patients without any neurodeficit. 2 patients remained in vegetative state. The primary concern in literature

with compound depressed skull fracture has been infection which ranges from 2.5% to 10.6%³.

Anyhow, a 10 days use of parenteral antibiotics with proper debridement of wound is helpful. We put all our patients after surgery on broad spectrum antibiotics for two weeks time but the infection rates was again quite high i.e. 13%. After comparing the infection rates, the factors labeled responsible were longer duration since injury has occurred, improper wound care in the local hospital, dural violation, replacing the bone fragments after elevation and not culturing the necrotic materials from the wound. In 1971, Brackman reported 4.6% infection rate after bone replacement and this factor may have increased the rate of infection in our series.

Proper debridement with normal saline and hydrogen peroxide, closure of the dura, replacing the depressed bone pieces after proper washing and elevation and parenteral use of antibiotics significantly reduce the chances of infections and prevent the patient from another operation of cranioplasty at a later date⁴. We saw 6% of patients were having seizures. Significant difference in the incidence of post traumatic seizures regardless of treatment approach occurs. Epilepsy is more common if there has been an intracranial haematoma, a depressed skull fracture or post traumatic amnesia of more than 24 hours¹⁵. The incidence of seizures can be reduced by closing the dura and elevating depressed bone pieces as minimization of scar formation and enhancing blood supply to ischemic cortical brain probably decreased post traumatic epilepsy. The occurrence of post traumatic epilepsy is usually secondary to the impact injury and not due to presence of depressed fracture¹⁶ which is most commonly seen with contusions in temporal and frontal lobes and thus, no improvement occurs even after elevation of depressed fracture. Some others has

reported the incidence of 16.5% post traumatic seizures in this series in which focal contusions in the brain was labeled as epileptogenic focus¹⁷. Any patient who has had seizures, after a craniotomy or depressed fracture should advise not drive or operate dangerous machinery. They should be advised also to contact the driving and vehicle licensing authority¹⁵.

The symptoms of headache were noted in 15% in our patients and all these were treated conservatively with mild analgesics. Though in literature, headache and other neurovegetative symptoms may be observed following depressed skull fractures with concussion but the prognosis of these symptoms may not be very good and need psychotherapy.

In our experience, the treatment of depressed skull fracture can be safely achieved in a surgical manner if proper surgical principles are followed. These principles washing of depressed bone pieces with hydrogen peroxide within 24 hours since injury has occurred, proper wound irrigation and prompt institution of intravenous antibiotics. Using these guidelines, we might be able to avoid infections, reoperation for cranioplasty at a later date and prevent poor cosmetic outcome. Thus the chances of focal neurological deficit and other factors complicating the management of patients with depressed skull fracture can be decreased.

CONCLUSION

- Most of depressed skull fractures should be treated surgically because spontaneous remodeling does not occur. Frontal and temporo-parietal fractures are of more cosmetic improvement as slight depressed fracture in these regions are very obvious and makes the patient psychologically disturbed.

- Depressed fracture of more than 5 mm, depressed fracture with evidence of dural violation and depressed fracture as a cause of raised intracranial pressure particularly over middle and posterior third of superior sagittal sinus should be surgically managed.
- Proper debridement of wound and irrigation with normal saline, evacuation of intracranial haematoma and duroplasty are essential principles along with depressed bone fragments elevation. Primary repair of skull defect with bone fragments is recommended as the treatment of choice during debridement of compound depressed fracture of mild to moderate severity which is presented to hospital within 24 hours of injury.
- The outcome of slight depressed skull fracture is good, and in other with focal or global brain injuries, the outcome depends upon severity of injury.
- Most of causes of depressed skull fracture are falls, road traffic accidents and domestic accidental happenings and this preventive measure could be instituted.

REFERENCES

1. J. Robert Kirkwood, ed. Head trauma, in essential of neurosurgery, 1st ed. Churchill living Stone, New York 1990; 263.
2. Buzdar H. Acute extradural haematoma analysis. Factors influencing the outcome of patient, undergoing surgery in coma. JCPSP 1999; 9(12):5-11.
3. Wilberger J, and Chen DA. The skull and meninges, management of head injury. Neurosurgery clinical of north America 1991; 2(2): 341.
4. Van den Heever HJ, Van der Mervve JJ. Management of depressed skull fractures. Selective conservative management of non-missile injuries J neurosurgery 1985; 71: 186.

5. Parker R. Anatomy of Head Injury anatomy, surgery international 2000; 51: 209.
6. Blankenship JB, Chaddock VM, Boop F. Repair of compound depressed skull fractures in children with replacement of bone fragments.
7. Chris - Fitzsimmons-Francis P. Morris Prehospital care - Triage and Trauma scoring. Trauma - surgery international 2001; 52: 25.
8. Kay AD, Mornhill S and Teasdale GM. The head inures adult, who cares? BJ of Neurosurgery 2001; 15 (6): 508.
9. Zbinden B, Kaiser G. Specific Aspects of depressed skull fractures in childhood. Z. Kinderchir 1989, 44: 3.
10. Jennet. B, Miller JD. Infection after depressed fracture of skull, implications for management of non missile injuries.
11. Kriss et al 1969 cited by Robert F, et al. Non surgical treatment of compound depressed skull fracture. J. Trauma 199, 35(3): 441.
12. Mlay SM, Sayi EN. The management of depressed skull fractures in children at Muhimbili medical centre, Dar es Salam Tanzania, East Afr Med J 1993; 70 (5): 291.
13. Coleman C. Cited by Blankenship et al. Repair of compound depresses skull fracture in children with replacement of bone fragments. Pediatr neurosurgery 1990; 16:297.
14. C Mauritz, VanDen Heever, David J, Van Der, Merwe. Management of depressed skull fracture, selective conservative management of non missile injuries.
15. Mlay SM. Head injury in children, A study of 120 cases. E. Afr. Med J 1985; 62:877.
16. Laurence D Watkins- Head injuries: General principles and management: Neurosurgery in surgery international. 2000; 51:219
17. Teasdal GM, Murray G, Anderson E et al. Risk of acute traumatic intracranial haematoma in children and adults, implication for managing head injuries. Br Med J 1990; 300.

Address for Correspondence:

Dr Mumtaz Ali,
Department of Neurosurgery,
Lady Reading Hospital,
Peshawar.